

Scaphoid Fracture Union

Joseph Joaquim Dias

A thesis presented for the degree of
Doctor of Medicine

University of Leicester

1989

UMI Number: U018587

All rights reserved

INFORMATION TO ALL USERS

The quality of this reproduction is dependent upon the quality of the copy submitted.

In the unlikely event that the author did not send a complete manuscript and there are missing pages, these will be noted. Also, if material had to be removed, a note will indicate the deletion.



UMI U018587

Published by ProQuest LLC 2015. Copyright in the Dissertation held by the Author.
Microform Edition © ProQuest LLC.

All rights reserved. This work is protected against
unauthorized copying under Title 17, United States Code.



ProQuest LLC
789 East Eisenhower Parkway
P.O. Box 1346
Ann Arbor, MI 48106-1346

CONTENTS

	PAGE
Preface	1
Introduction	1
<hr/> Section 1: The normal scaphoid <hr/>	
1.1 Anatomy of the scaphoid bone	8
1.2 Ligaments attached to the scaphoid	13
1.3 Wrist kinematics with special reference to the scaphoid bone	24
1.4 Extraosseous and intraosseous vascularity of the scaphoid	33
<hr/> Section 2 : The broken scaphoid <hr/>	
2.1 Epidemiology of scaphoid fractures	43
2.2 The mechanism of fracture	44
2.3 The problem : scaphoid fracture	

	non-union	51
2.4	The magnitude of the problem : incidence of non-union	56
2.5	Factors affecting union	61
2.6	Early diagnosis of scaphoid fracture	61
2.7	Clinically suspected scaphoid fracture	73
2.8	Type of plaster cast	76
2.9	Duration of immobilisation	81
2.10	Fracture morphology	84
2.11	Fracture displacement	85
2.12	Avascularity and scaphoid fractures	87
2.13	Carpal instability and scaphoid union	89
2.14	Role of noncompliance	92

Section 3 : Experimental studies

3.1	Soft tissue signs in the early diagnosis of scaphoid fractures: the incidence of
-----	---

	false positive and false negative results	95
3.2	The value of multiple radiographic views in the assessment of acute scaphoid injuries	107
3.3	Clinically suspected scaphoid fractures: the value of second week radiographs	117
3.4	Scaphoid cast versus Colles' cast : a prospective randomised study	135
3.5	The value of radiographic signs of scaphoid fracture union : assessment of inter-observer agreement.	157
3.6	Scaphoid waist fractures : patterns of union	170
3.7	State of union in treated fresh fractures of the scaphoid	187
3.8	Real time ultrasonography in the assessment of scaphoid fracture non-union	198
3.9	Avascularity and scaphoid fracture non-union	215

3.10	Carpal instability and scaphoid fracture non-union	234
------	---	-----

Section 4 : Discussion

4.1	Discussion	251
4.2	Conclusions	261

Section 5 : References

5.1	References	264
5.2	Appendix 1 : Ultrasonography of carpal bones	290

PREFACE

Fracture of the carpal scaphoid, occurring as it usually does in young working men, can lead to disruption in their work and leisure for a considerable period of time. Moreover, it has been regarded to be prone to develop non-union if inadequately treated. This can lead to continuing symptoms in the wrist. Its small size and oblique orientation make clinical and radiological assessment difficult. These factors have led to controversy regarding several aspects in the management of this fracture.

It is the commonest fracture of the carpal bones and, in the young adult, is probably as frequent as a fracture of the distal radius. The Leicester Trauma and Orthopaedic service can expect to treat between eighty and one hundred definite fractures of the scaphoid every year.

The usual duration of immobilisation for this fracture is between eight and twelve weeks, with a small percentage requiring a longer period in a plaster cast. This is much longer than the usual five weeks immobilisation for distal radius fractures. In addition, the recommended cast includes the thumb which may result

in further restriction in the use of the injured hand while in the cast. Both these factors can cause serious economic and social inconvenience to patients sustaining such a fracture.

This thesis reports the results of investigations carried out in relation to the early diagnosis and management of scaphoid fractures, excluding the fracture of the scaphoid tuberosity. The established management protocol was put under scrutiny and the reliability of radiographic assessment in the early diagnosis and in the diagnosis of union was investigated. In addition, an alternative method of assessment, using real time ultrasonography, which could overcome the drawbacks of clinical and radiological assessment, was studied.

These investigations were performed during the period from the 1st of September, 1985 to the 31st of October, 1988 while I held the post of Lecturer in the University Department of Orthopaedic Surgery, Leicester.

These investigations could not have been undertaken without the co-operation and assistance of several Departments and individuals. I would like to acknowledge the support, help and encouragement of all the Consultant Orthopaedic Surgeons at the Leicester Royal Infirmary, who allowed me to take over the complete

management of all scaphoid injuries in this period. I am especially grateful to them for ensuring that any patient with a scaphoid injury who inadvertently turned up in their fracture clinic was referred to the special scaphoid clinic conducted for this study. This ensured that no patient was excluded from the prospective trial. Many of them gave up time and conscientiously reviewed many sets of scaphoid radiographs in the two 'radiographic reliability' studies. I am also grateful to the many senior house officers, registrars and senior registrars who participated in various aspects of this thesis.

I would like to thank Sister Hazel Richards and all her staff for their patience and cheerful help in changing countless plaster casts which I considered unsatisfactory - usually, I hasten to add, because of softening in the palm due to the patients' activities. Margaret Steward and her staff ensured that any patient who failed to turn up was not lost to follow up and I am grateful to her for looking after the notes and radiographs. This involved considerable extra work as these had to be filed seperately.

I am indebted to Dr John Thompson, Lecturer in Epidemiology in the Department of Ophthalmology, Leicester Royal Infirmary, for help with most of the

statistical analysis and especially for his help in designing the reliability studies. All the computing and statistical analysis was carried out at the Computer Centre, University of Leicester.

I am grateful to many individuals without whom these studies could not have been comprehensively performed. Ivan Brenkel, Lecturer in Orthopaedic Surgery, stepped in and covered the scaphoid clinic when I was on annual leave and participated actively in several studies. Informal discussions with him, Nigel Clay and Mr Nicholas Barton, Consultant Hand Surgeon, Queens Medical Centre, Nottingham, helped me to formulate and crystalise various ideas. Dr David Finlay, Consultant Radiologist, Leicester Royal Infirmary, ensured that I had complete co-operation from his department even when I had to send several patients for repeat radiographs and radiographs of the opposite wrist. I am indebted to him for his support and encouragement throughout these studies. Dr Tony Lamont, Consultant Paediatric Radiologist, taught me to use the new Acuson Ultrasound Scanner and provided me free access to the scanner even during week-ends. I would particularly like to acknowledge his help in refining the technique of ultrasonographic assessment of the wrist.

I would also like to acknowledge that most figures in sections 1 and 2 were modified from those in Dr J Taliesnik's book on 'The Wrist' (Churchill Livingstone, New York, 1985).

I am grateful to Hilary Stafford, Chief Technician, University Department of Orthopaedic Surgery, Glenfield General Hospital, Leicester, for the preparation and staining of the histological slides, and to Dr A Malcolm, Senior Lecturer in Osteo-Articular Pathology, Newcastle-upon-Tyne, for reviewing these histological sections.

The patience and perseverance of the staff of the Medical Illustration Department, Leicester Royal Infirmary is also gratefully acknowledged.

I am deeply grateful to Mr Huw Thomas, Senior Lecturer in Orthopaedic Surgery, Leicester University, for patiently reading through the all drafts of this thesis. Without his help and guidance I would have had difficulty in completing this work.

Finally, I owe a deep debt of gratitude to Professor Paul Gregg, who, shortly after joining as the Foundation Professor of Orthopaedic Surgery, University of Leicester, suggested that I should investigate the management of scaphoid fractures and provided me with the opportunity to do so. He ensured that I had the operating time and the outpatient sessions to continue this study, monitored the progress of the various aspects but at the same time let me have the freedom to

evolve my ideas. For his enthusiastic support and advice
and for his help in refining the various publications
that have resulted from this work, I am deeply grateful.
f

Joseph J Dias,

April, 1989

INTRODUCTION

SCAPHOID FRACTURE UNION

The main concern about a fracture of the scaphoid is that it may fail to unite. This concern has promoted extremes in management and consequently has become the source of controversy on almost every aspect in the management of this injury.

A: THE PROBLEM

The incidence of non-union has been reported to range from 5% (Russe 1960, Leslie and Dickson 1981) to 50% (Herbert & Fisher 1984). Almost every study on this injury was retrospective and failed to define what was considered to represent a non-union. This is probably the primary reason for such a vast variation in the reported incidence of non-union.

The presence of a non-union may or may not cause symptoms or the level of symptoms may not 'warrant' surgical intervention. However, recent studies of symptomatic non-unions over 5 years after injury (Mack et al 1984, Ruby et al 1985) noted that secondary

degenerative osteoarthritis, as seen on radiographs, was present in almost all cases. While a non-union may not be as major a clinical problem as suggested by early writers on the injury (Adam and Leonard 1928, Todd 1921) the concern is that the problem of symptomatic non-union may still be very much greater than currently appreciated.

B: FACTORS AFFECTING UNION OF SCAPHOID FRACTURES

Various factors have been suggested as influencing union following scaphoid waist fractures. These include (1) failure of early diagnosis, (2) inadequate immobilisation, (3) fracture morphology, (4) fracture displacement, (5) associated carpal instability, (6) proximal scaphoid avascularity, and (7) patient non-compliance.

Each of these factors has been a source of controversy and debate. Whilst there is complete agreement that a fracture of the scaphoid should be diagnosed early, there is conflicting advice regarding how this should be achieved. The early authors emphasised the need for adequate clinical examination of the injured wrist (Todd 1921) along with adequate radiography. This involved good quality radiographs and multiple views ranging from two (postero-anterior and lateral views) to sixteen (Graziani 1940). Some have even suggested that

3

radiographs should be obtained under flourescopic control so that they can be obtained with the x-rays in the plane of the fracture. A small percentage of injuries still, however, continue to be missed (Leslie & Dickson 1981, DaCruz 1988). This has led to the recommendation of further investigations such as trispiral tomography (Cooney et al 1980), radio-isotope bone scan (Ganel et al 1979, Jorgensen et al 1979), and even aspiration of the wrist (McLaughlin and Parkes 1969) to exclude the fracture.

One long standing recommendation has recently come under scrutiny. A clinically suspected scaphoid fracture in which initial radiographs failed to demonstrate an obvious fracture is traditionally treated in a plaster cast for a fortnight following which repeat radiographic and clinical examination is recommended. Several authors (Leslie & Dickson 1981, Duncan & Thurston 1985, Young et al 1988, DaCruz et al 1988) have suggested that this is un-neccessary and costly as very few of these have been subsequently shown to have a fracture. In addition, it has been stated that these represent incomplete fractures which would probably heal regardless of treatment. Medico-legal claims for missed scaphoid injuries, however, continue to be settled in favour of the patient (Annual report-Medical Protection Society 1988).

Once a fracture of the scaphoid is diagnosed there is universal agreement that the injured wrist must be immobilised. However, once again, there is controversy regarding (a) the position of the wrist in the plaster cast and the inclusion of the thumb and/or elbow in the plaster cast, and (b) the duration of immobilisation. The traditional recommendation has been to immobilise the broken scaphoid until union, as judged on radiographs, has occurred. This usually means twelve weeks immobilisation and in around 20% of the fractures a further period of immobilisation may be required. In a few reported instances the plaster cast has been retained for over one year ! Because of the serious effect on the patients life (economic and social) several other authors have taken a more aggressive attitude (Herbert & Fisher 1984), usually on arbitrary and ill-defined criteria, to internally fix those scaphoid fractures which gave 'cause for concern' regarding union after an initial period in a plaster cast (ranging from 6 weeks to 6 months).

The fracture morphology has been thought to influence union of scaphoid fractures (Russe 1960, Bohler 1954). This has not been supported by more recent studies (McLaughlin and Parkes 1969, Leslie & Dickson 1981). Cooney et al (1980) and Leslie and Dickson (1981)

suggest that displacement of the fracture occurring during treatment is more important. Concurrent ligamentous injury resulting in carpal instability and increased intercarpal mobility has also been suggested as a factor predisposing to non-union (Fisk 1970, Monsivais et al 1986).

The effect of avascularity of the proximal part of the scaphoid on the rate of union of the scaphoid waist fracture is unknown. The reported incidence of proximal avascularity, judged by the increased radio-density of the proximal part of the scaphoid, varies widely for fresh fractures (1% to 40%) and also in the presence of non-union (9% to 41%). Finally, it has been suggested that compliance of the patient (usually a young active adult male) to treatment may be a significant factor affecting the outcome of these fractures.

The small size and oblique orientation of this bone makes both, clinical examination and radiographic interpretation not only difficult but also highly observer dependant. This, coupled with the concern about non-union, has led to prolonged immobilisation of the wrist in young working men with the consequent adverse influence on their lives. The literature on most of these aspects fails to provide any clear answers.

C: AIMS & OBJECTIVES**Aim**

The aim of this investigation is to define an optimum method of treatment of scaphoid waist fractures which would achieve the twin goals of bone union and rapid return to work.

Objectives

1. To assess the value of soft tissue signs and multiple radiographic views in the early diagnosis of scaphoid fractures and to establish whether repeat radiographic assessment of clinically suspected scaphoid fractures after a fortnight helps in diagnosing subtle fractures
- 2: To determine the need for thumb immobilisation in the treatment of scaphoid fractures, determine the non-union rate and to investigate factors which influence union such as avascularity and carpal instability in a series of prospective studies.
3. To assess the value of radiographic diagnosis of fracture union and to develop an ultrasonographic technique to assess union of a scaphoid fracture and to assess the stability of established non-unions.

Section 1

The normal scaphoid

SECTION 1.1

THE ANATOMY OF THE SCAPHOID BONE

Andreas Vesalius recognised the carpus (greek 'karpos' - wrist) as an anatomical entity in 1543 and identified all the carpal bones. Michael Lyser first proposed proper names for each carpal bone (Jones 1949). These names were first used by Alexander Munro in his book 'Anatomy of humane bones' in 1726 (Quoted in Jones 1949). The present official nomenclature was established in 1955.

Most modern reptiles and mammals have eight carpal bones. Napier (1980) demonstrated reductions and fusions of the carpal bones in certain animals. He described a single scapho-lunate bone in carnivores.

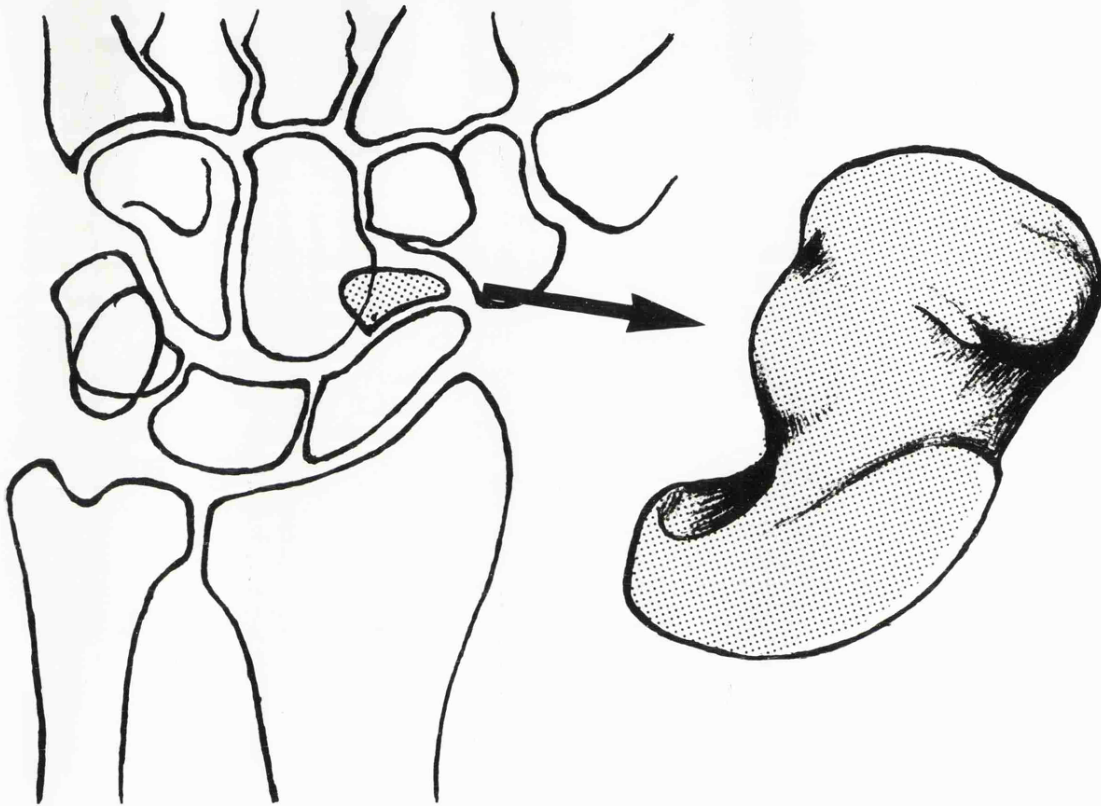
The human carpus is not, however, a mere relic of an earlier ancestral configuration; the arrangement of several multifaceted bones is essential for mobility and stability. With the exception of humans and certain African apes, the proximal carpal row in primates includes one extra bone - the os centrale. In the human embryo the os centrale appears in the sixth week of

gestation and fuses with the scaphoid in the eighth, remaining only as a small irregular prominence (Figure 1.1-1). Bogart (1932) and Jones (1949) have reported that in some wrists the os centrale degenerates into a fibrous structure represented in the adult wrist as a ligament between the scaphoid and the capitate. In these individuals, radiographs of the wrist may demonstrate an open space between the distal scaphoid and the capitate (Figure 1.1-2).

The scaphoid bridges the luno-capitate joint. Most of its surface is covered by hyaline articular cartilage for articulation with the radius, the trapezium, the trapezoid, the lunate and the capitate. The facet for the radius is the largest, occupying the entire proximal pole. The articular surface of the distal pole is divided by a superficial ridge into two facets, one for the trapezium and the other for the trapezoid. The direction of this ridge from dorsal and radial to volar and ulnar coincides with the maximum plane of wrist motion and corresponds to the joint space between the trapezium and the trapezoid. The medial facet is composed of two surfaces, one distally for the head of the capitate and the other, a very small semilunar facet for articulation with the lunate. The extreme volar portion of the facet for the lunate contains a shallow grove for the insertion of the radio-scapho-lunate

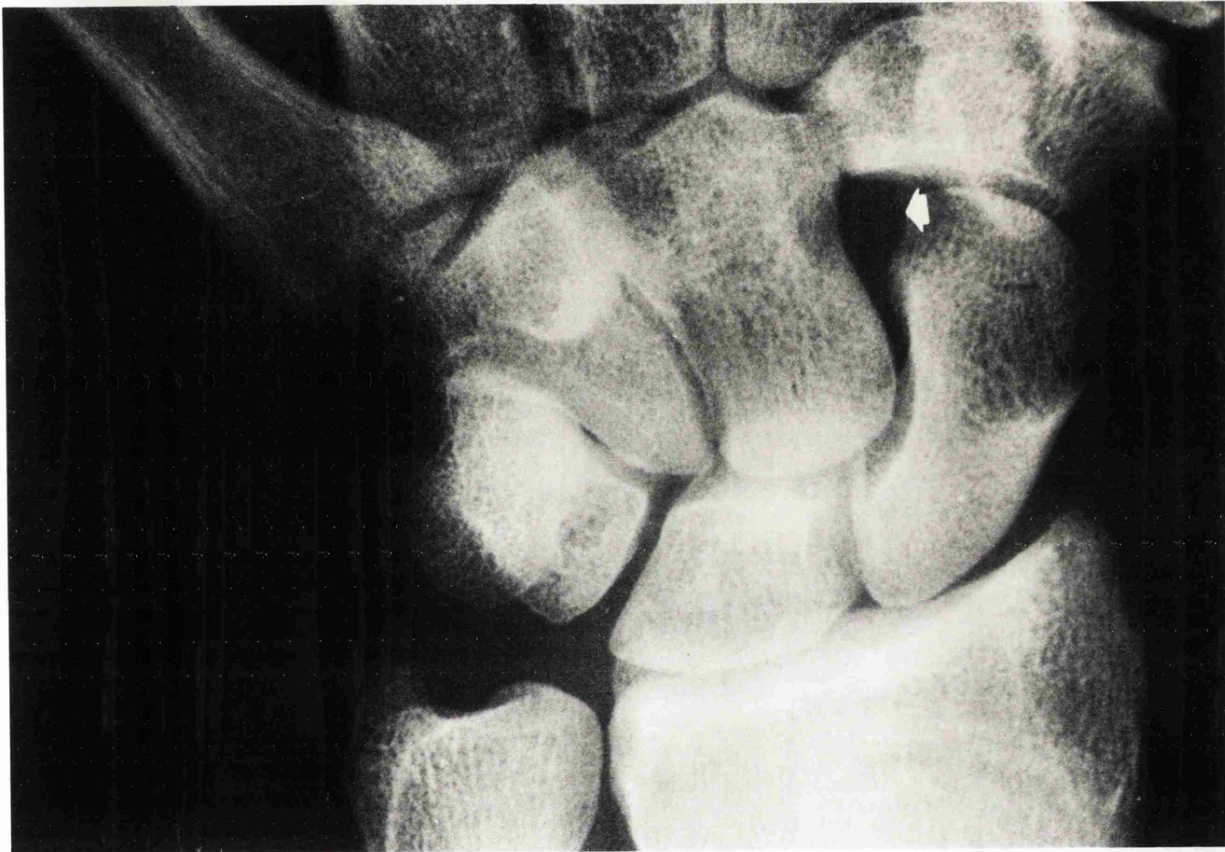
ligament. The non-articular surface of the scaphoid is narrow and is referred to as the waist of the scaphoid. It twists around the bone, mostly on the lateral aspect, directly opposite the facet for the capitate. It ends at a large distal pole, the tubercle of the scaphoid, onto which the transverse carpal ligament and the palmar intrinsic and radiocarpal ligaments are inserted (Taleisnik 1976). In the narrow waist or groove are numerous foramina for blood vessels.

11
FIGURE 1.1-1 : The os centrale



The os centrale, an extra carpal bone in primates, is represented by the tubercle on the inner aspect of the scaphoid.

FIGURE 1.1-2 : The absent tubercle centrale



The gap sometimes seen between the distal pole of the scaphoid, the capitate and the trapezium (arrow) probably represents a fibrous anlage of the os centrale.

SECTION 1.2

LIGAMENTS AROUND THE SCAPHOID

In the wrist the ligaments constitute a sophisticated system capable of inducing bony displacement such that precise transmission of tension loads occurs. The volar ligaments are thick and strong. Their strength and orientation correlates with the primitive palmigrade position of the limbs in primates (Lewis et al 1970). The dorsal ligaments are thinner and fewer and are reinforced by the floor and septae of the fibrous tunnels through which the extensor tendons pass on the dorsum of the wrist. The ligaments of the wrist are divided into two major groups (Taleisnik 1976). Extrinsic ligaments between the carpal bones and the radius or metacarpals and intrinsic ligaments which originate and insert on the carpal bones.

A: THE VOLAR EXTRINSIC LIGAMENTS AROUND THE SCAPHOID

These include the radial collateral ligament, the radio-scapho-capitate ligament, the radio-lunate ligament and the radio-scapho-lunate ligament (Figure 1.2-1). The weakest ligaments are on the radial aspect of the wrist, the radio-scaphoid portion of the

radio-scapho-lunate ligament and the radio-scapho-capitate ligament, suggesting that failure is more likely to occur on the radial side of the wrist joint.

The radial collateral ligament

The radial collateral ligament is more volar than lateral (Taleisnik 1976). It originates from the volar margin of the radial styloid, courses volar to the transverse axis of wrist movement, and is attached on to the tuberosity of the scaphoid and the walls of the fibrous tunnel for the flexor carpi radialis tendon. It is not a true collateral ligament but is the most radial of the volar radio-carpal ligamentous fan. The function of a true collateral ligament, as seen in a hinge joint, is not possible in a multiaxial joint such as the wrist. The term 'collateral' ligament would be justified only if the radio-carpal movement were restricted to flexion and extension. In ulnar deviation of the wrist any true collateral system would act as a restraint. Kauer (1979) proposed that the extensor pollicis brevis and the abductor pollicis longus tendons behaved as an 'adjustable collateral system'. Lateral wrist stability depends primarily on the precise fitting of the multiple carpal bones on the radial aspect of the wrist along with the two tendons providing a dynamic collateral system.

The radio-scapho-capitate ligament

This ligament originates from the triangular surface on the anterior surface of the radial styloid and attaches on the volar surface of the head of the capitate. On its way, it courses over the volar concave aspect of the scaphoid, onto which it gains a rather weak attachment.

The fibres of this ligament are considerably more elastic than the other ligaments and elastic fibres have been demonstrated among the predominant collagenous portion.

The radio-lunate ligament

This originates from the volar aspect of the base of the radial styloid continuous with the origin of the radio-scapho-capitate ligament, and is attached to the volar aspect of the lunate. This forms a strong and distinct ligament which, at surgery, appears as a volar labrum which deepens the articulation of the proximal scaphoid and the radius. It may need to be transected at surgery in order to expose the proximal pole of the scaphoid through the volar approach.

This is the strongest of all volar extrinsic ligaments (Mayfield et al 1979) with the amount of ligament elongation before failure being only 57% when compared

with the radio-scapho-capitate ligament (74% elongation).

The radio-scapho-lunate ligament

This ligament was described by Kuenz and Testut (quoted by Testut & Latarjet 1951) and is sometimes referred to by their names. It originates from the small tubercle on the volar rim of the radius at the articular crest which divides the scaphoid and lunate articular facets of the distal radius. This ligament inserts primarily into a small fossa in the articular surfaces of the scaphoid and lunate and into the capsule of the scapho-lunate joint. The lunate insertion is strong. In full palmar flexion of the scaphoid the radio-scapho-lunate ligament and, to a lesser extent, the radio-scapho-capitate ligament tether the proximal pole of the scaphoid to the volar margin of the radius. In maximum dorsiflexion of the scaphoid the radio-scapho-lunate ligament provides an anterior restraint against excessive displacement of the proximal pole.

B: THE DORSAL EXTRINSIC LIGAMENTS OF THE SCAPHOID

These are the radio-scaphoid ligament and the radio-lunate ligaments (Figure 1.2-2). The radio-scaphoid ligament is a short structure arising from the dorsal rim of the radial styloid and inserting into the dorsum of the scaphoid. The radio-lunate

ligament arises from most of the dorsal rim of the distal radius and is inserted into the dorsum of the lunate.

C: THE INTRINSIC LIGAMENTS OF THE SCAPHOID

These fall into two groups, the short ligaments between the scaphoid and trapezium / trapezoid and the scapho-lunate ligaments, and the long ligaments which traverse the entire carpal area on its volar and dorsal aspects.

Short intrinsic ligaments of the scaphoid

The scapho-lunate ligaments : These are found on the volar and dorsal surfaces. They course obliquely from lunate to scaphoid and allow considerable motion between these two bones. From neutral to full dorsiflexion, the lunate rotates approximately 28 degrees and the scaphoid 30 degrees (Wright 1935). From neutral to complete volar flexion the lunate rotates by 30 degrees and the scaphoid by 60 degrees. Both ligaments twist as dissimilar scapho-lunate rotations occur in volar flexion, and unwind as the carpus returns to neutral. The dorsal ligament is shorter and more dense than the volar ligament, allowing for anterior scapho-lunate gaping during motion (Kauer 1974). Kauer (1980) described a third type of scapho-lunate displacement, in addition to rotation and 'gaping'. This displacement

occurs because of the difference in the degree of curvature between the proximal pole of the scaphoid and the proximal articular surface of the lunate. The scaphoid curvature is greater; therefore it must shift proximally during volar flexion, in relationship to the lunate, in order to maintain its surface contact with the radius.

The scapho-trapezium ligaments : There are three of these: the volar, lateral and dorsal. These allow the trapezium and trapezoid to ride dorsal to the distal pole of the scaphoid, a mechanism that forces the scaphoid into flexion during the radial deviation of the wrist.

The long intrinsic ligaments

The volar inter-carpal ligament is a strong inverted V shaped structure with the apex of the V originating from the volar aspect of the head of the capitate. The lateral (scapho-capitate) band contributes to the support of the distal pole of the scaphoid along with the radial collateral ligament. It may extend to the trapezium. The medial band is inserted into the volar aspect of the triquetral bone and crosses the proximal part of the hamate.

The dorsal inter-carpal ligament is a ribbon like

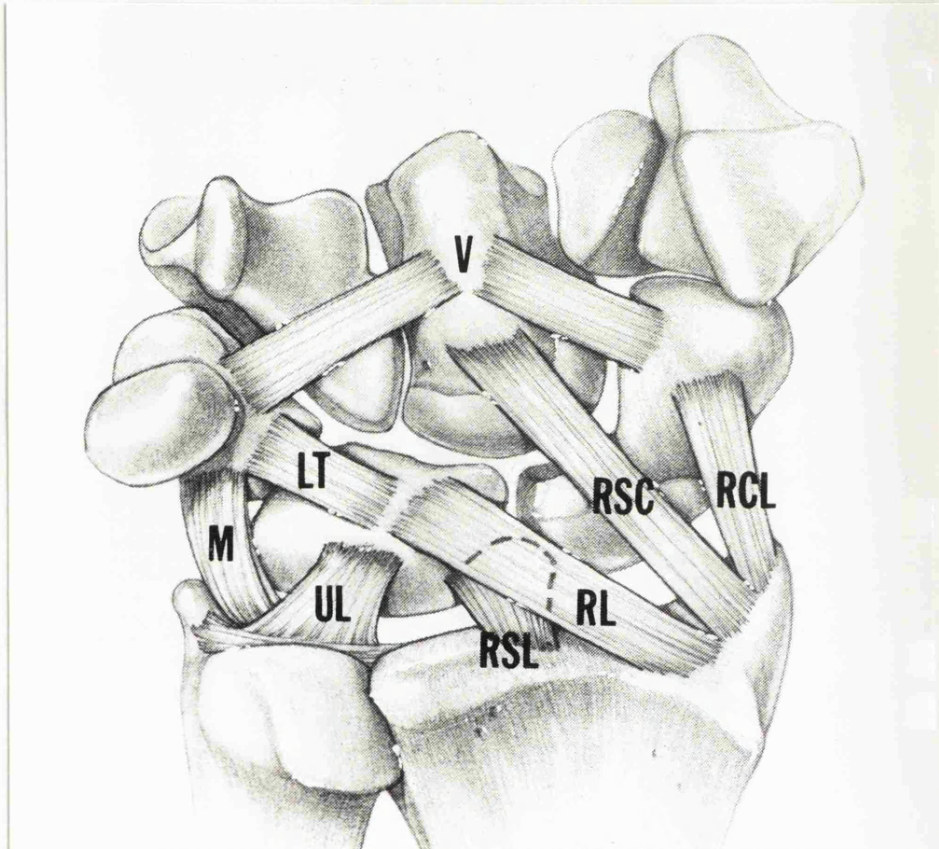
structure that originates from the triquetrum and courses laterally and obliquely to insert on the scaphoid and occasionally the trapezium. It skirts the head of the capitate dorsally.

In movements of the wrist in the coronal and the sagittal planes the scaphoid moves simultaneously around or along three axes. This complex movement is controlled by the ligamentous attachments of the scaphoid. On the volar aspect of the scaphoid there are three well defined ligamentous zones. The proximal zone controls the rotation of the proximal pole on the radius (radio-scapho-lunate ligament) and the lunate (the intrinsic scapho-lunate ligament). The distal zone controls the distal pole or tuberosity, connected to the radius (radial collateral ligament) and the capitate (lateral band of the volar 'V' ligament). The central zone provides tenuous attachment to the radio-scapho-capitate ligament.

The scaphoid rotates on the radio-scapho-capitate ligament as a gymnast balances on the horizontal bar when executing a hip circle (Figure 1.2-3). The contact point of this ligament on the scaphoid coincides with the transverse axis for scaphoid rotation from volar flexion to dorsiflexion. Both the radio-scapho-capitate ligament and the radio-scapho-lunate ligaments tether

the proximal pole of the scaphoid to the volar aspect of the radius. The radio-scapho-lunate ligament is particularly important and is tense at both ends of scaphoid rotation. As long as these bands are intact, rotatory subluxation of the scaphoid cannot occur even if the scapho-lunate inter-osseous ligaments are severed (Berger et al 1982). Ruby et al (1987) suggest, however, that disruption of the dorsal scapho-lunate ligament can result in instability between the proximal scaphoid and the lunate.

FIGURE 1.2-1 : The volar ligaments

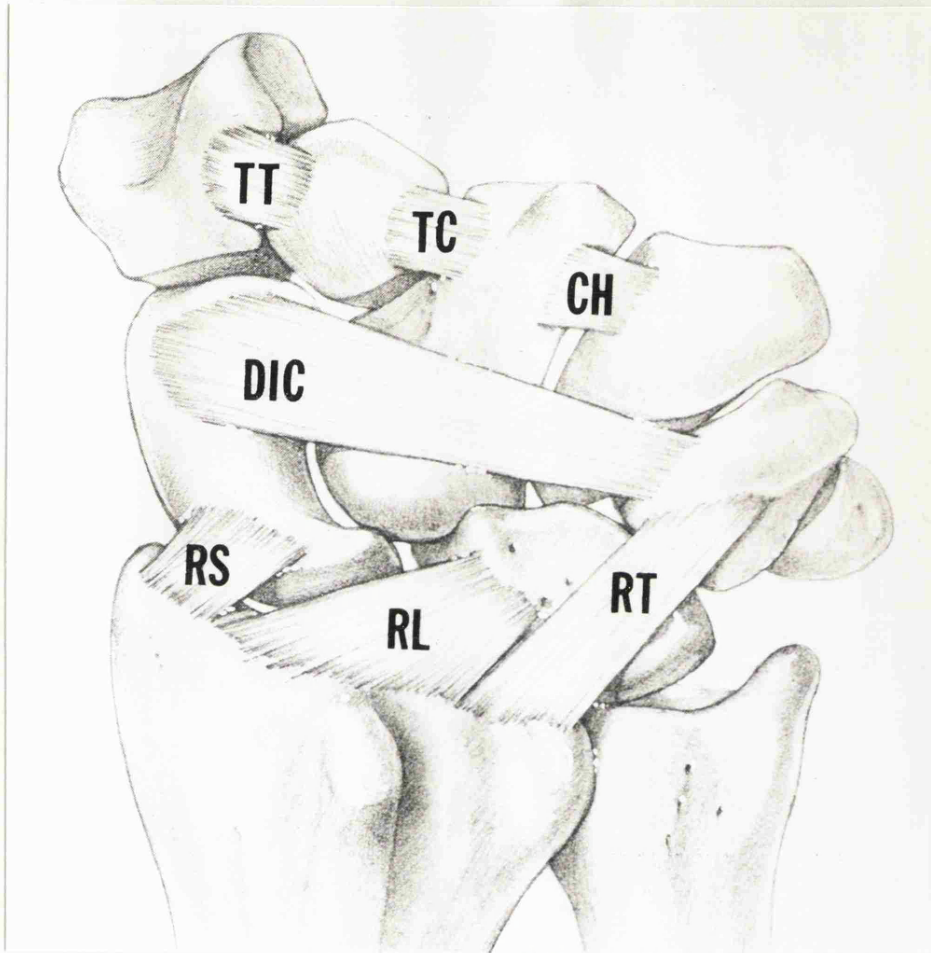


The volar ligaments of the wrist (after Taliesnik 1976). RCL: radial collateral ligament is more volar than lateral. RSC: radio-scapho-capitate ligament, RL: radio-lunate ligament, RSL: radio-scapho-lunate ligament.

The volar inter-carpal ligament is an inverted 'V' structure (V), the lateral band is the scapho-capitate ligament.

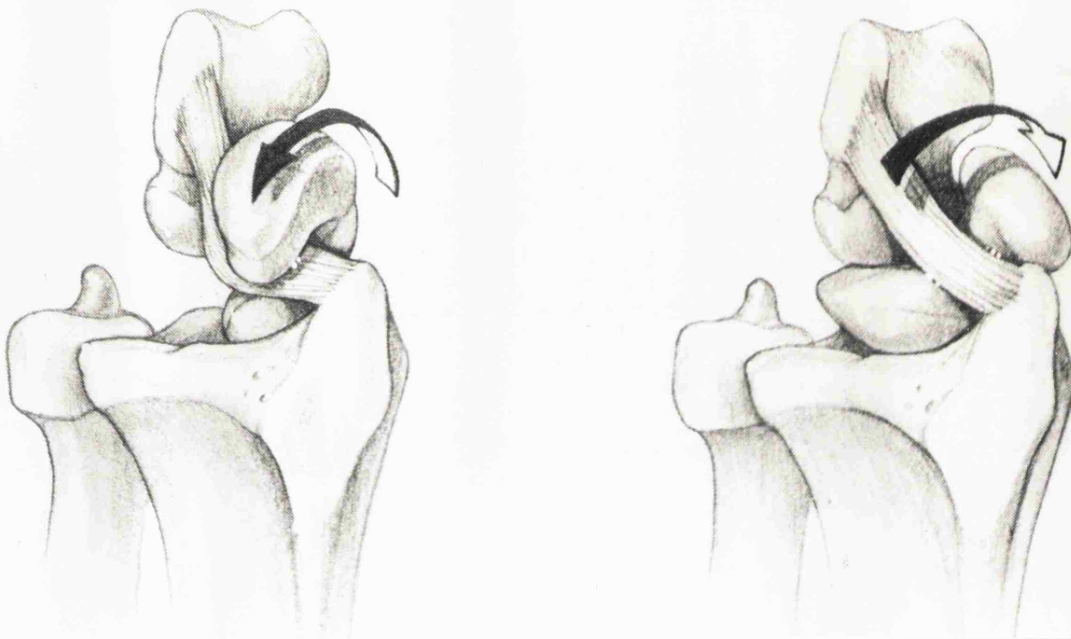
The medial ligaments include the ulnar-lunate (UL), lunate-triquetral (LT) and the menisco-triquetral (M) ligaments.

FIGURE 1.2-2 : The dorsal ligaments



The dorsal ligaments of the wrist (Taliesnik 1976). RS: the radio-scaphoid ligament, RL: the radio-lunate ligament and RT: the radio-triquetral ligament. The ribbon like dorsal inter-carpal ligament (DIC) runs from the scaphoid to the triquetral bone. The distal short intercarpal ligaments TT, TC, and CH.

FIGURE 1.2-3 : Scaphoid rotation



The scaphoid rotates on the radio-scapho-capitate ligament as a gymnast balances on the horizontal bar when executing a hip circle.

SECTION 1.3

CARPAL KINEMATICS WITH SPECIAL REFERENCE TO THE SCAPHOID BONE

Von Bonin (1929) viewed the carpus as three separate sets of bones : the lunate, the scaphoid and the five distal bones (triquetrum, hamate, capitate, trapezoid and trapezium). Traditionally the carpus is considered to consist of a proximal and distal carpal row. This does not explain either the function of the wrist joint or its behavior after injury.

Navarro (1921, 1935) proposed an entirely different concept, that of the vertical or 'columnar' carpus. He suggested that the carpus was made of a central column for flexion and dorsiflexion and two side columns for rotation. The central column was formed by the lunate proximally and the capitate and hamate distally. The lateral or mobile column comprised of the scaphoid and the trapezium & trapezoid, while the medial or rotational column was made up of the triquetrum and the pisiform. Some phylogenetic support for this longitudinal representation of the carpal bones may be found in primitive animals (Johnston & Whillis 1949)

The ideal primitive carpus is represented as a longitudinal arrangement of bones radiating symmetrically from the axis of the limb towards the different digits. Developmental changes were secondary to the specialization of the radial digits for grasping and of the ulnar digits for support, stability and strength. The only part of the primitive carpus disposed transversely was the distal row. The primitive distal row is composed of five bones, arranged one at the base of each metacarpal bone. The first modification of this pattern occurs in digitate vertebrates in whom the ulnar two bones are fused into a single carpal bone articulating with the fourth and fifth metacarpals (Brash & Jamieson 1943). This reduction, represented by the hamate in humans, is consistently seen in mammals and is probably a reflection of the need for stability on the ulnar side of the hand. This disposition is similar to that seen in humans, the trapezium, trepezoid, capitate and the hamate being intimately connected by ligaments. This constitutes a true transverse functional unit articulating with all five metacarpal bones.

A modification of Navarro's concept incorporates this view, expanding the central column to include the entire distal carpal row in addition to the lunate (Figure

1.3-1). The mobile column was limited to the scaphoid and the rotation column to the triquetrum (Taleisnik 1976).

In 1202 Leonardo de Pisa came across a sequence of numbers in connection with the breeding of rabbits. In this sequence each number is the sum of the previous two (0,1,1,2,3,5,8 ...). This pattern is not limited to rabbits. It is found in the ancestral tree of the male bee and in botany, from the number of petals in many flowers to the scales of fir cones and pineapples. A carpal arrangement of three verticle columns would fit this pattern. The skeletal sequence of the upper limbs one scapula, one humerus, two forearm bones, three carpal columns and five metacarpals.

A: THE CENTRAL COLUMN

The human wrist may be described as a central flexion-extension longitudinal link. Such a link mechanism allows greater motion, with flatter joint surfaces for increased stability. Onto this central column attach the two inverted 'V' ligament complexes. Motions along the radio-luno-capitate link are produced by muscles that cross the carpus on the way from their origin to their insertion into the bases of the second, third, fourth and fifth metacarpals. Steindler (1950) pointed out that these muscular forces are asymmetrical,

and that the resulting plane of dorsiflexion is radialward and that for palmarflexion is ulnarward. This plane from dorsal and radial to volar and ulnar is the physiologic axis of wrist activity (Bryce 1896, Corson 1898). Within this link system, the distal row of carpal bones, firmly attached to the capitate, moves with the hand, to which it is connected by strong inter-osseous ligaments. The centre of wrist movements lies within the head of the capitate (Youm et al 1978). The position of the lunate, the potentially unstable intercalated bone, varies in response to the pull of its ligaments, the contact pressures of the surrounding carpal bones and the shape of the lunate. The lunate is wedge shaped, its volar aspect being thicker. This favours dorsiflexion of the lunate. In this type of a link, stability is required in only one direction and this is provided by the scaphoid.

B: THE LATERAL MOBILE COLUMN : THE SCAPHOID

The functional role of the scaphoid to provide carpal stability has been long recognised (MacConaill 1941, Von Bonin 1929). MacConaill (1941) singled out the scaphoid as an intercalated rod between the proximal and distal carpal rows. Without the scaphoid the central column would tend to collapse under compression loads.

MacConaill (1941) compared the carpal function to a screw clamp device. As dorsiflexion is completed, the scaphoid becomes one with the distal carpal row thus behaving as a fixed jaw of a carpal screw clamp. At the end of dorsiflexion the carpal bones are closely packed or locked, a position of support, stability and strength.

The proximal pole of the scaphoid is, in a saggital plane, wedge shaped like the lunate, with a tendency to dorsiflex similar to that of the lunate (Kauer 1980). This tendency is controlled by the action of the trapezium and trapeziod on the distal pole of the scaphoid (Johnston 1907). Thus, during palmarflexion of the wrist, the scaphoid is made to volarflex against this dorsiflexion tendency. During wrist dorsiflexion, the scaphoid dorsiflexes in response to its own bias, but only as far as allowed by its ligamentous restraints and the position of the trapezium and trapezoid.

More complex inter-carpal motions occur in ulnar and radial deviation, when equal but opposite rotations of the proximal and distal carpal rows can be observed (Bryce 1896). Volarflexion of the lunate in radial deviation is induced by the scaphoid (Johnston 1907). In turn the scaphoid is made to volarflex by the lever

action of the trapezium and trapezoid, obligated to ride dorsal to the distal pole of the scaphoid, in response to the pull of the extensor carpi radialis longus and brevis tendons on the second and third metacarpals. As the scaphoid volarflexes, its longitudinal axis becomes perpendicular to that of the radius. In postero-anterior radiographs the perpendicular volarflexed scaphoid appears foreshortened, its distal pole seen end on (Figure 1.3-2). This allows the radial carpal height to shorten, and the trapezium comes to lie close to the radial styloid.

C: THE MEDIAL ROTATION COLUMN

It has been observed (Ghigi 1939) that because scaphoid displacement from flexion to extension is greater than that of the lunate and is non-existent for the triquetrum, the proximal row demonstrated a rotation movement around a longitudinal axis passing through the triquetrum. In radial and ulnar deviation, however, the scaphoid translates the least while the triquetrum moves distally (radial deviation) and proximally (ulnar deviation) on the hamate.

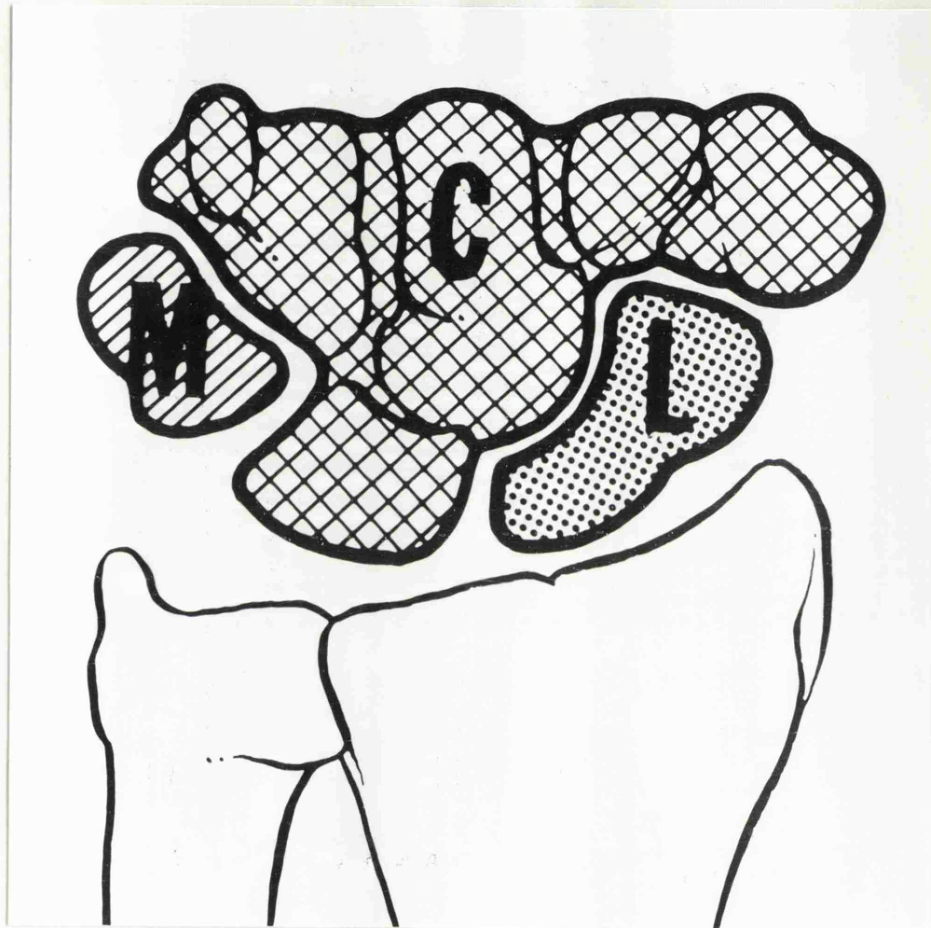
D: SUMMARY

The wrist is essentially a longitudinal central

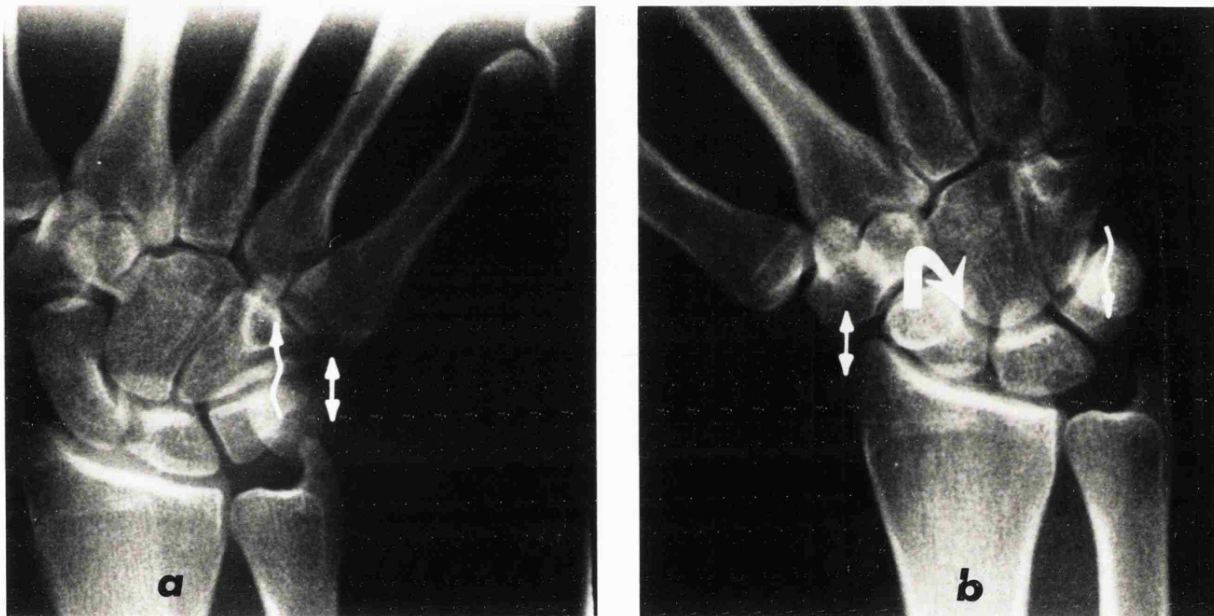
flexion-extension link composed of the radius, lunate and the distal carpal complex (trapezium, trapezoid, capitate and hamate). Two inverted 'V' shaped ligament complexes are attached to the centre of motion in the head of the capitate. Wrist motion is produced by muscles that attach beyond this column into the metacarpals and occurs along a physiological plane that goes from dorsal and radial to volar and ulnar. The distal carpal row moves the hand through strong carpo-metacarpal ligaments. These motions influence scaphoid and triquetrum movements. In radial deviation of the wrist, shortening of the radio-carpal height is made possible by the volarflexion of the scaphoid. This causes the mid-carpal joint to unlock and the distal carpal row is allowed to migrate radially. In ulnar deviation the scaphoid straightens out (extends) and its axis is more in line with the axis of the radius. During ulnar deviation the triquetrum becomes dorsiflexed and telescopes on the hamate. In this position the scaphoid becomes longitudinal and midcarpal movement is largely eliminated. The carpus is effectively transformed into a single functional and extremely stable unit.

Volarflexion and radial deviation take place predominantly at the mid carpal joints. The lunate is the intercalated segment with an intrinsic structural tendency to dorsiflex. This tendency is enhanced by the triquetrum and is neutralised by the scaphoid.

FIGURE 1.3-1 : The columnar carpus



Navarro's concept of the columnar carpus as modified by Taliesnik (1976) : The central column (C) includes all bones in the distal row; the mobile lateral column (L) is represented by the scaphoid while the rotational medial column (M) is represented by the triquetral bone.

FIGURE 1.3-2 : Scaphoid movement

In ulnar deviation the scaphoid extends (**a**) while in radial deviation of the hand it flexes forwards and the distal pole is seen end on (**b**), appearing as a ring. The trapezium comes to lie close to the radial styloid.

SECTION 1.4

THE EXTRA-OSSEOUS AND INTRA-OSSEOUS VASCULARITY OF THE SCAPHOID

The scaphoid bone is supplied almost entirely by the radial artery (Figures 1.4-1 and 1.4-2).

A: THE RADIAL ARTERY

The radial artery is the smaller of the two terminal branches of the brachial artery. Proximal to the radio-carpal joint, this artery rests on the pronator quadratus muscle, on the volar-radial quadrant of the wrist. As it reaches the radial styloid, the artery changes its direction to proceed dorsally and distally, first around and then just beyond the tip of the styloid process of the radius. It continues deep to the abductor pollicis longus and extensor pollicis brevis tendons, across the anatomical snuff box and under the extensor pollicis longus tendon, to reach the apex of the first dorsal inter-osseous space. It passes between the two heads of the first dorsal inter-osseous muscle in a volar direction to reach the palm of the hand, where it joins the deep palmar branch of the ulnar artery to form the deep palmar arch.

B: THE COMMON INTEROSSEOUS ARTERY

The common interosseous artery is short and substantial. It starts in the proximal forearm from the dorsal aspect of the ulnar artery. Upon reaching the proximal border of the interosseous membrane in the proximal forearm it bifurcates into anterior and posterior interosseous arteries. The anterior interosseous artery descends on the interosseous membrane, between the flexor pollicis longus and the flexor digitorum profundus. Upon reaching the pronator quadratus, it gives off two branches : a small volar division, which passes deep to the pronator quadratus and anastomoses with the volar carpal network, and a larger dorsal division. This division perforates the interosseous membrane to enter the dorsum of the wrist, running alongside the posterior interosseous nerve. It is then joined by the termination of the posterior interosseous artery. This terminal common interosseous artery divides into lateral and medial branches which in turn anastomose with ascending rami from the dorsum of the carpus.

Branches of these main trunks supply the scaphoid. Just before the radial artery leaves its anterior position to reach the dorsum of the hand, it gives off a palmar carpal branch that anastomoses with an analogous branch of the ulnar artery to form the volar carpal arch,

running along the distal border of the pronator quadratus muscle. Likewise the dorsal carpal artery arises from the radial artery within the anatomical snuffbox, at a point level with the luno-capitate joint. It anastomoses with a similar branch of the ulnar artery to form the dorsal carpal arch. The superficial palmar branch of the radial artery runs over the tuberosity of the scaphoid to anastomose with the termination of the ulnar artery to form the superficial palmar arch.

McCormack et al (1953) reported 18.5 percent major variations in the brachial and antebrachial arterial patterns of 750 upper extremity specimens. Departures from the anatomical norm involved the radial artery in 81.3 percent : usually involving a high origin of this artery. Unusual terminal branches of the radial artery were comparatively rare.

Over the wrist itself the vascular anastomoses form three dorsal arches and three volar arches with branches from the radial, ulnar and the interosseous arteries. The dorsal arches are the radiocarpal arch at the level of the radiocarpal joint, the intercarpal arch at the level of the midcarpal joint and the basal metacarpal arch. On the volar surface corresponding arches are formed with the deep palmar arch replacing the basal metacarpal dorsal arch. These arches supply the carpal

bones.

C: INTRA-OSSEOUS CIRCULATION OF THE SCAPHOID

The intraosseous vascularity of the scaphoid has received particular attention (Gelberman & Menon 1980, Taliesnik & Kelly 1966).

The scaphoid receives its blood supply through ligamentous attachments. The lateral bundle of the intrinsic 'V' ligament originates from the tuberosity of the scaphoid. Proximal and lateral to this is the insertion of the radial collateral ligament. The dorsal radiocarpal ligament is attached to the dorsal spiral groove. Two additional ligaments are only precarious vehicles for vascular access, because their scaphoid attachments are either tenous (radio-scapho-capitate ligament) or very localised to a small fossa (radio-scapho-lunate ligament). Most studies point out that the distal half of the scaphoid receives a more abundant arterial supply. This coincides with the overall ligamentous arrangement. The proximal part of the scaphoid is essentially an intra-articular pole, comparable to the head of the femur, and covered by articular hyaline cartilage. Only one ligament attaches to the proximal pole rather like the ligamentum teres of the head of the femur.

In 1955, Grettve showed that the main scaphoid supply entered a narrow area curving around the radial border of the carpus. This supply could be divided into three groups: dorsal, proximal and volar. Taleisnik and Kelly (1966) also described three groups of vessels responsible for the supply of the scaphoid. The 'latero-volar' vessels approach the scaphoid immediately distal and lateral to the radial articular surface. The dorsal group penetrates the dorsum of the scaphoid along the spiral waist, and the distal vessels enter it on the volar aspect of the distal pole. The 'latero-volar' and the dorsal branches anastomose freely while the distal vessels supply a circumscribed area of the tuberosity only. In these authors' opinion the 'latero-volar' system is the main contributor to the intraosseous blood supply. After penetration of the bone these vessels divide into branches which spread proximally and medially toward the articular surface of the scaphoid for the radius and capitate. The 'latero-volar' arteries provide most of the blood supply to the proximal two thirds of the scaphoid. There are profuse anastomoses between its branches and with similar branches of the dorsal system, ending in subperiosteal and subarticular arcades, typical of the vascular pattern of cancellous bone. They found that the dorsal arteries were usually of the same size or slightly smaller than the

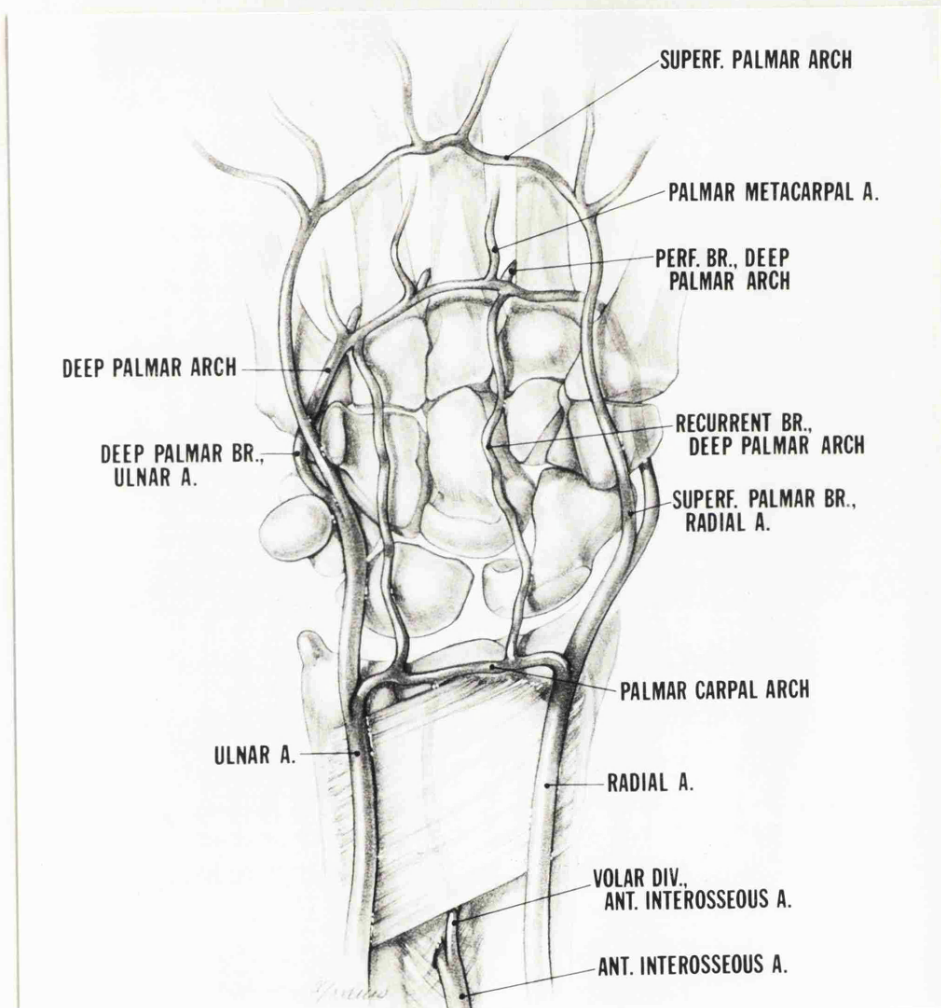
'latero-volar' vessels. The dorsal vessels contribute to the arterial supply of the proximal two thirds of the scaphoid. The distal arterial supply is the smallest of the three, but supplies a much more restricted area limited to the tuberosity of the scaphoid without anastomosing with the rest of the arterial system.

Minne et al (1973) described a similar pattern of three arterial groups : dorsal, distal and lateral. The dorsal vessels were distributed throughout the dorsal spiral groove of the scaphoid. The distal and lateral vessels were unequally allocated to the lateral and volar aspects of the scaphoid, although predominantly within the distal part of this bone. In contrast, Gelberman and Menon (1980) described two vascular systems instead of three : dorsal along the spiral groove and volar limited to the tuberosity. They agreed that there are no intraosseous anastomoses between arteries of the tuberosity and those within the rest of the scaphoid. They pointed out that several small vessels which did not penetrate bone were seen in the region of the proximal pole, undoubtedly related to the radio-scapho-lunate ligament. This observation was also made by Preiser in 1910.

In a study of dried specimens, Obletz and Halbstein (1938) catalogued 297 scaphoids according to the

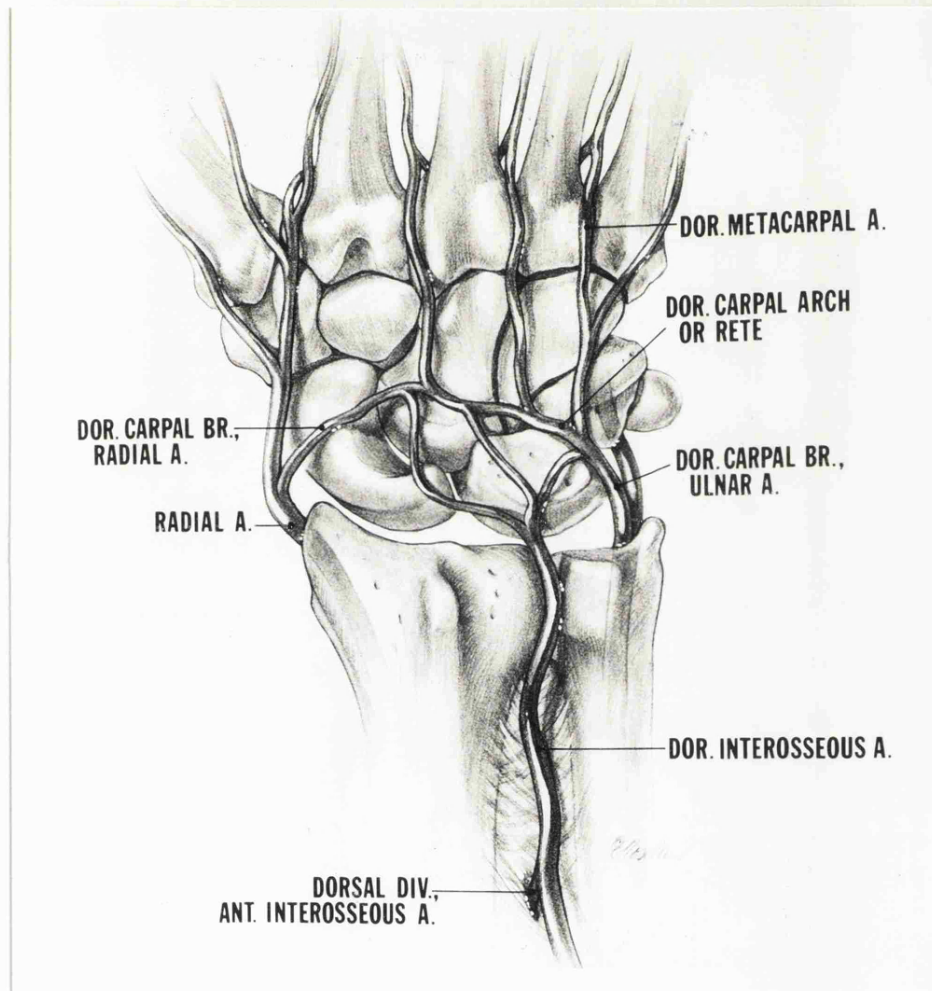
positions of vascular foramina. In 13 percent there were no foramina proximal to the waist of the scaphoid. This is similar to the 14 percent of the specimens studied by Gelberman and Menon (1980) which showed blood supply entering distal to the waist. Therefore one out of seven patients would have shown a significant loss of blood supply following a fracture through the waist. Twenty percent of the scaphoids studied by Obletz and Halbstein (1938) had one vascular foramen proximal to the waist of the scaphoid while in the remaining 67 specimens there were two or more vascular foramina proximal to the waist of the scaphoid.

FIGURE 1.4-1 : The blood vessels around the wrist



The blood vessels on the volar aspect of the wrist. The distal pole of the scaphoid is crossed by the superficial palmar branch of the radial artery.

FIGURE 1.4-2 : The blood vessels around the wrist



The blood vessels on the dorsum of the wrist. The main trunk of the radial artery as well as its dorsal carpal branch lie in close relationship to the dorsal ridge of the scaphoid.

Section 2

The broken scaphoid

SECTION 2.1

THE EPIDEMIOLOGY OF SCAPHOID FRACTURES

The fractured scaphoid is chiefly an injury sustained by young men. In military personnel (Barr et al 1953, Cleveland 1947, Dickison & Shannon 1944, Henry 1944, Stewart 1954) and athletes (Hopkins 1933) the incidence of scaphoid fractures is higher than that of the distal radius. It is an uncommon injury in children. Eddeland et al (1975) reviewed 196 fractures of the scaphoid and found only 13 in children 12 to 15 years of age. In another series (Vahvanen & Westerlund 1980), most patients were 10 years or older. They stressed that, although rare and usually without complications, scaphoid fractures in children should be kept in mind for they can progress to non-union if neglected. Recently a rare case of osteochondritis dissecans of the scaphoid was reported ((Aghasi et al 1981) involving the proximal pole, in a 19 year old patient whose original injury was sustained at age 13.

It is common in athletes and sportsmen, especially those taking part in contact sports. These individuals sustain repeated falls. This, in itself, does not fully

explain the higher incidence in men as more and more females are taking part in sport. Part of the reason may be the greater mobility of the wrist in females. This injury also occurs commonly in industry (Adams and Leonard 1928).

Jaekel & Clark (1939) reporting on fractures in workers at the construction of the Boulder dam found the scaphoid fracture to be the commonest wrist injury. In the earlier part of the century these fractures were also noted to occur following the kickback of a motor starting handle. This threw the hand into sudden dorsiflexion. This is an uncommon mode of injury now.

SECTION 2.2

THE MECHANISM OF INJURY

This injury usually occurs as a result of a fall on the outstretched hand. The exact mechanism of the fracture, as to whether the scaphoid fails under tension or compression, is not clearly understood.

A: COMPRESSION FRACTURE ?

Destot (1905) was able to cause fractures of the scaphoid in cadaveric hands by placing the hand in radial deviation and directing the force of injury to the thenar eminence. He suggested that the scaphoid is wedged between the radius and the ground and the fracture occurred by the exaggeration of the curve of the scaphoid and is caused by bending or compression. Adams and Leonard (1928) felt that it was always sustained as a result of indirect violence. They suggested that impact forces were transmitted via the third metacarpal, capitate and through the proximal scaphoid into the radius. When this happened, he proposed that the strong radio-scapho-capitate ligament acted as a fulcrum over which the scaphoid bent and broke.

Frykman (1967) subjected cadaver wrists to static loading and observed that the greater the dorsiflexion of the wrist, the larger the force required to produce a fracture and the more distal the location of the injury. With dorsiflexion of 90 degrees or more injury occurred to the carpal bones, and consistently to the scaphoid when radial deviation was added. Loads were greater than those required to break the distal radius.

This was confirmed experimentally by Weber and Chao

(1978) in fresh cadaver specimens. They demonstrated that for a scaphoid to fracture consistently the hand had to be dorsiflexed over 90 degrees and the load had to be applied to the radial aspect of the palm. The proximal scaphoid is held firmly by the radius, capitate and the volar ligaments and the fracture occurs between the supported and unsupported parts of the scaphoid (Figure 2.2-1).

B: TENSION FRACTURE ?

Jeanne and Mouchet (1919) were able to reproduce the fracture experimentally by hyperpronation of the hand and they suggested that the scaphoid broke under tension by 'opening of the angle'.

Todd (1921) felt that there should almost always be a definite history of significant injury. He suggested that the hand, on striking the ground, went into radial deviation. In this position the scaphoid is flexed and the proximal pole is firmly held between the radius and the radio-scapho-capitate ligament, which form a vice. The distal part of the scaphoid is 'snapped off' resulting in a transverse fracture of the waist of the scaphoid. If the radial deviation of the scaphoid was less extreme the fracture would be nearer the ulnar side of the scaphoid. He also quoted Speese who suggested

that transverse scaphoid fractures could occur with or without volar compression.

Dickison & Shannon (1944) suggested that the proximal scaphoid is fixed against the radius when the person falls with the hand in dorsiflexion, all further stress occurs at the mid carpal level resulting in a tension fracture. The location of the fracture varies with the radial or ulnar deviation of the hand at impact. Radial deviation exposes the distal one third of the scaphoid while with progressive ulnar deviation increasing portions of this bone are exposed.

C: DIRECT INJURY ?

In 1933 Hopkins suggested that the scaphoid breaks in a manner similar to Colles' fractures : a fall on the dorsiflexed hand, usually in radial deviation, load is transmitted through the third metacarpal and capitate which causes an impingement of the narrow part of the scaphoid against the radius. Cobey and White (1946), too, suggested that the scaphoid breaks because of compression rather than tension loads. They suggested that the capitate exerts compression against the concave surface of the scaphoid.

Torsion or rotation (both supination and pronation) have

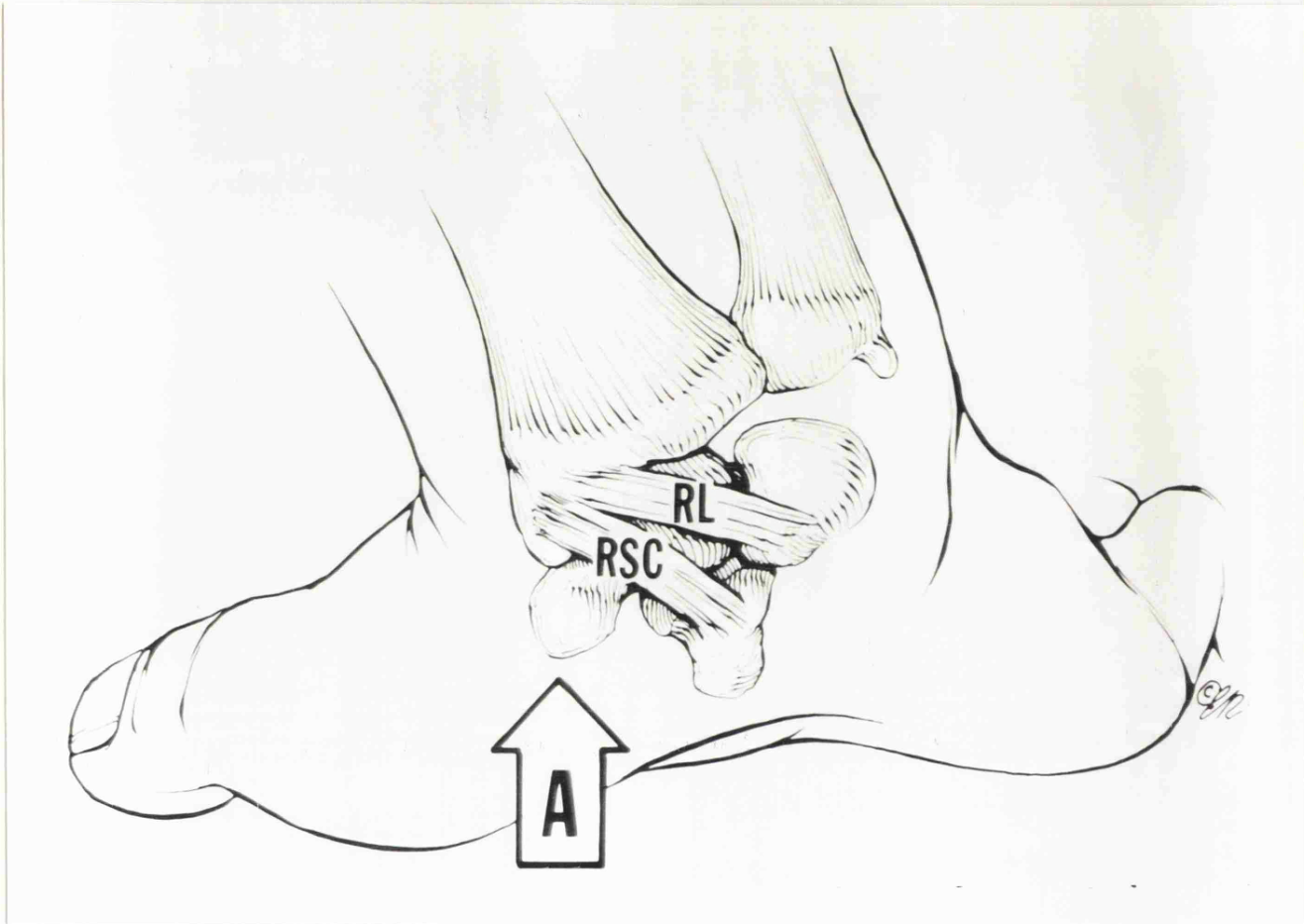
also been considered to be important (Fisk 1982, Gilford et al 1943).

D: PROBABLE MECHANISM OF INJURY

There is no doubt that compression, when it occurs, is on the volar aspect of the scaphoid. Secondly, patients very rarely give a history of the wrist being bent right back when they fell. Finally, when a young person falls he is more likely to take the impact over the distal palm rather than the heel of the palm. It may be that it is not the position of the wrist but the reaction of the proximal carpal row to axial loading that results in the fracture. Both the lunate and the proximal part of the scaphoid are wedge shaped, being broader anteriorly than posteriorly. This confers the intrinsic tendency to dorsiflex (ie face backwards). This tendency is resisted essentially by the fact that the scaphoid spans the proximal and distal rows and articulates firmly with the trapezium and trapezoid which have very little relative movement, as in all bones of the distal carpus. The distal carpal row has strong articulations with the metacarpals apart from the first metacarpal.

When the hand strikes the ground the impact forces are transmitted from the metacarpals into the relatively firm distal row. The position of the distal scaphoid is

fixed by the trapezium and trapezoid. Any give must now occur in the proximal carpal row which is devoid of any tendon insertion to have a moderating influence. The axial load therefore tends to dorsiflex the lunate and with it the proximal part of the scaphoid. A bending force is generated in the scaphoid. The radio-scapho-capitate ligament lies across the waist of the scaphoid which is also the most slender part of the scaphoid. The scaphoid breaks, the dorsal surface under tension and the volar surface under compression. Depending upon the direction and magnitude of the impact forces the volar aspect of the scaphoid would sustain varying degrees of compression.

FIGURE 2.2-1 : Mechanism of injury

When the dorsiflexed hand strikes the ground the proximal pole of the scaphoid is held firmly between the radius and the radio-scapho-capitate and the radio-lunate ligaments and the scaphoid breaks at its waist. A: is the ground reaction force.

SECTION 2.3

THE PROBLEM : SCAPHOID FRACTURE NON-UNION

The primary concern regarding scaphoid waist fracture is that it may not unite and that this will result in pain and osteo-arthritis.

In the early part of this century an established non-union of the scaphoid fracture was a very common presentation. Todd (1921) pointed out that all these patients were symptomatic while Adams and Leonard (1928) noted that all patients with a delayed union or non-union eventually developed osteoarthritis in the radio-scaphoid joint. More recently the concept of the 'asymptomatic' scaphoid non-union is well entrenched and repeatedly used as an argument against any aggressive policy in the management of this fracture.

A: THE NATURAL HISTORY OF SCAPHOID NON-UNION

All studies on the natural history of untreated scaphoid non-unions are limited by the fact that being retrospective they represent only those patients who presented with symptoms. Dickison and Shannon (1944)

demonstrated that osteoarthritis occurred in 30% of their 70 scaphoid non-unions. London (1961) reported on 60 non-unions with degenerative changes in 36 and observed that the severity of arthritis increased with time. In 25 of his patients the duration of non-union was not documented.

Ruby et al (1985) reviewed 56 scaphoid fracture non-unions of which 32 had received no treatment for over five years since injury. Osteoarthritis (presence of joint narrowing, osteophytes, sclerosis and cysts seen on radiographs) in the radio-scaphoid and intercarpal joints had developed in all but one case of the 32 patients with non-unions which were five years or older. 50 of the 56 patients (89%) had become symptomatic at some time. The majority of the patients in this study had become symptomatic following a second injury. They recommended advising all patients with a scaphoid non-union that osteoarthritis was a likely eventuality although it may not be painful.

Mack et al (1984) reviewed 47 untreated non-unions of the scaphoid which had been present for at-least five years. They found that radiographic evidence of osteoarthritis in the joints around the scaphoid increased with time. Between 5 and 10 years after injury almost all non-unions showed cyst formation and

resorbative changes around the scaphoid. Before 10 years only around 50% had any radiological abnormality (carpal collapse or displacement), between 10 and 20 years 89% had radiological abnormality while after 20 years 94% had an abnormality. They were unable to correlate the radiographic changes with symptoms. Thirty five of their 47 patients had mild or moderate symptoms while 11 had severe symptoms for 6 months to 6 years. These 11 patients all had a displaced non-union and 10 had wrist instability. Only 13 of their patients attributed their symptoms to a recent injury.

It has been shown repeatedly that few symptomatic non-unions can be expected to be free of degenerative change for more than a decade after injury, and most will have established arthritis in twenty years. The most significant factors associated with arthritis were displacement and wrist instability. Both were present in over 90% of patients with degenerative osteoarthritis. Mack et al (1984) also suggested that displacement and instability could occur as a late phenomenon in previously undisplaced non-unions and that in displaced untreated fractures these two complications would occur earlier.

B: THE 'ASYMPTOMATIC' NON-UNION

Mack et al (1984) suggested that an undisplaced

non-union in a sedentary patient was less likely to displace, slower to undergo degenerative change and less likely to cause symptoms. However, they expected the effect of any such bias to be slight. The exact incidence of asymptomatic non-union is not known.

There appear to be three main modes of presentation. The patient may present with a continuous ache in the radial aspect of the wrist which increases on certain activity (usually dorsiflexion or twisting) and is relieved by rest. It may be associated with sudden sharp pain in the radial aspect of the wrist on radial deviation and dorsiflexion of the wrist and may cause the patient to drop objects or cause the wrist to 'give way' (Todd 1921). These patients usually have moderate tenderness localised to the anatomical snuff box and, in at least half, the scaphoid stress test may be uncomfortable. They have limitation of dorsiflexion and radial deviation in particular when compared to the contralateral side.

The second type of presentation is when the patients, who deny having any prior problem with the wrist, sustain an injury and then present with pain in the anatomical snuff box. Twenty six of the 56 patients with a scaphoid non-union reported by Ruby et al (1985)

presented in this manner. It has been suggested that in such patients a strong fibrous union exists at the fracture site and that it is asymptomatic unless disrupted by a second injury (Brown & Dameron 1975, Lewis et al 1976).

The third method of presentation is when the patient has no symptoms and a radiograph of the wrist obtained for unrelated reasons reveals an ununited scaphoid fracture. Sometimes the patient cannot recall a fracture and in the past some of these were mistaken for a congenital bipartite scaphoid which is considered to be extremely rare, if it occurs at all. Gollaschs' report (1939) of bipartite scaphoids in several members of a family was probably the only true instance of this unusual condition.

Non-union that does not require treatment has been referred to (Perkin 1950, Scott 1956). London (1961) reported 60 non-unions and all but seven of these presented after strenuous use or injury. He suggested, rather confusingly, that the non-union was not itself the cause of symptoms but that it predisposes the wrist to react painfully to injury or overuse !

SECTION 2.4

THE MAGNITUDE OF THE PROBLEM

A: INCIDENCE OF NON-UNION

The incidence of non-union following fractures of the waist of the scaphoid has been variously reported, although the common accepted figure is around 5%. The early authors suggested that non-union was almost an invariable result of a scaphoid waist fracture and that this usually left the patient with a painful wrist. Bohler (1954) reported on 557 fresh fractures treated over a 27 year period, some in a below elbow cast without including the thumb and others with inclusion of the thumb, the plaster being retained for six to eight weeks. They noted that only 23 (3.96%) developed pseudoarthrosis. Russe (1960) treated 220 scaphoid fractures over a three year period: only 6 failed to unite (3%). There were 27 fractures in which treatment was delayed and all of these 'united' after immobilisation lasting between three weeks to three years, the average being six months.

More recently Leslie and Dickson (1981) reported a retrospective study of 222 consecutive patients with a

fresh fracture of the scaphoid seen over a six year period in Oxford. All were treated in a 'scaphoid' plaster cast with the first metacarpal included in a position of abduction and opposition. The mean time to union was nine weeks and 11 of 159 patients with a waist or proximal fracture were ununited. Non-union was more common in transverse and proximal pole fractures.

Marcus Stewart (1954) reported on 320 fresh fractures of the body and proximal pole of the scaphoid seen during the European theatre of World War II. He suggested that around 95% united using a scaphoid plaster for between eight and sixteen weeks. London (1961), in a well argued paper aptly entitled, 'the broken scaphoid bone, a case against pessimism', said that 95% of his 227 fresh fractures united uneventfully. It would appear from these and other studies (Dunn 1972, Eddeland et al 1975, Murray 1946, Lichtman 1982, Rothberg 1939, Sotto-Hall and Haldeman 1941) that only one in twenty scaphoid waist fractures would be expected to develop a non-union.

The confusion arises from the fact that there are many studies suggesting a much higher incidence of scaphoid fracture non-union.

Until Roentgen discovered x-rays in 1895 the fracture of

the scaphoid was known only as an occasional finding at autopsy (Callander 1866). Within five years Stimson (1902) stated that, 'total disability of the wrist' was the normal result after this injury. A generation later Adams and Leonard (1928) wrote, 'it is an undisputed fact that in the vast majority of cases the bone does not unite'. In 1957, Adams placed the scaphoid bone only second to the neck of the femur in its liability to non-union and in 1959 Decoulx et al reported non-union in 36% of a series treated in a plaster cast. London (1961) suggested that the high incidence in early studies reflected the inadequate treatment. Some of these patients had had a splint for only a week and immobilisation beyond one month was uncommon. He suggested that given adequate management the incidence of non-union would be in the region of 5%. However, a careful review of his own study demonstrates that 50 of his 300 fresh fractures did not demonstrate 'radiological union' and that in some cases union took upto 12 months to occur. No further details are available for these 50 patients although the impression gained is that almost all progressed to eventual union.

Cooney et al (1980) reported on the results of treatment of non-unions. Their patients were from 435 scaphoid fractures seen at the Mayo clinic between 1961 and 1976. Of these 106 patients had scaphoid non-union, an

incidence of around 25%. No details of treatment were given. Herbert and Fisher (1984) suggested that the true incidence of non-union after conservative treatment was difficult to estimate and pointed out that most reported studies did not define the criteria of non-union nor specify the length of clinical and radiological follow-up. They stated that in their experience the incidence of non-union after conservative treatment was in the region of 50%.

The exact incidence of non-union following fractures of the waist and proximal pole of the scaphoid is not known but probably ranges between 5 and 50%.

B: ASSESSMENT OF UNION

The assessment of union both clinically and radiologically can be difficult. London (1961) attempted to define union as, 'normal texture throughout the bone in postero-anterior, lateral and two oblique views or a steady improvement in radiographic appearances with time'. The orientation and size of the scaphoid and the overlap with other carpal bones on most views makes it a very difficult bone to image and to interpret. It is customary to look for trabeculae crossing the fracture line or 'sclerosis' at the fracture line as an indication of bony union (Russe 1960). Todd (1921) pointed out that in order to demonstrate a fracture of

the scaphoid or to adequately assess union the radiograph must be obtained with the x-ray beam in the plane of the fracture. Any other view would produce an overlap of the rims and may suggest union. Lindgren (1949) also emphasised this and stated that, 'it may be difficult to determine whether sclerosis arising around a fracture is a sign of beginning union or indicates non-union'. Bohler et al (1954) in their detailed study on scaphoid fractures also addressed this question. They too, emphasised the great difficulty they experienced in diagnosing union both on clinical and radiographic appearances. They suggested that there was no need to immobilise the wrist until the fracture line was completely invisible as this might take months or even years.

Given this expressed difficulty in the diagnosis of union on radiographs one must question the reported incidence of non-union in all retrospective studies in which the diagnosis of union was based only on early radiographic evidence (Russe 1960, Leslie & Dickson 1981, Cooney et al 1980).

SECTION 2.5

Factors affecting union of scaphoid fractures

The following factors are considered to influence union of a scaphoid fracture:

1. Early diagnosis
2. Adequate immobilisation
 - (a) type of cast
 - (b) duration of immobilisation
3. Displacement of the fracture
4. Abnormal mobility : intercarpal instability
5. Avascularity of the proximal part of the scaphoid
6. Patient compliance to treatment

SECTION 2.6

EARLY DIAGNOSIS OF SCAPHOID FRACTURES

Alan Todd (1921) stated that the great majority of scaphoid fractures seen in Guys hospital at that time

were examples of old fractures and that these cases were not diagnosed as a fracture at the initial visit. He considered that careful clinical examination of the wrist should indicate a diagnosis of a scaphoid fracture and emphasised that this would ensure that such an injury was not missed.

A: THE IMPORTANCE OF EARLY DIAGNOSIS:

Stewart (1954) had only 3 non-unions in 323 patients with fresh fractures diagnosed within four weeks of injury and treated with immobilisation. Of 63 patients who presented after 4 weeks and in whom the results in the short term (12 weeks) were known three had developed a non-union. Bohler et al (1954) in their large study on this fracture, had only 23 non-unions in 557 recent fractures. In contrast, of 116 fractures which presented after an interval of time and were treated in a plaster cast for different periods, 21 developed a non-union. It therefore appears that any delay in treatment would predispose to failure of union.

B: CLINICAL EXAMINATION

Todd (1921) emphasised the importance of a careful clinical examination and described the findings (Codman and Chase 1905) one must look for when assessing the possibility of a scaphoid fracture in an injured wrist.

'The patient, usually a young adult male, presents with the history of some injury to the hand and he complains of pain or marked discomfort in the wrist, especially over the radial aspect, made worse on movement. The pain intensity is usually not very severe and a stoic individual may well disregard it to his detriment. There is a small group of patients with established scaphoid fracture non-union who do not even recall a specific injury or state that they thought it was merely a sprain and expected it to get better within a few weeks'.

Inspection of the wrist may reveal some swelling in the anatomical snuff box with blurring of its tendon boundaries in comparison to the opposite normal wrist. This swelling is well localised to the radial and dorsal aspects of the wrist and usually does not extend proximally over the distal radius. Todd (1921) suggests that it follows the distal border of the radius. Occasionally this swelling may extend towards the index finger. In traumatic tenosynovitis the swelling is more diffuse and in line with the involved tendons. It may be associated with soft crepitations palpated on movement of the appropriate tendons. A 'sprained' wrist has been considered to be a very rare diagnosis even as far back as 1917 by Speese (quoted by Todd 1921) who said that it is untenable to make this diagnosis. The swelling in a

distal wrist fracture is diffuse and is associated with obliteration of volar wrist creases and may also be associated with bruising.

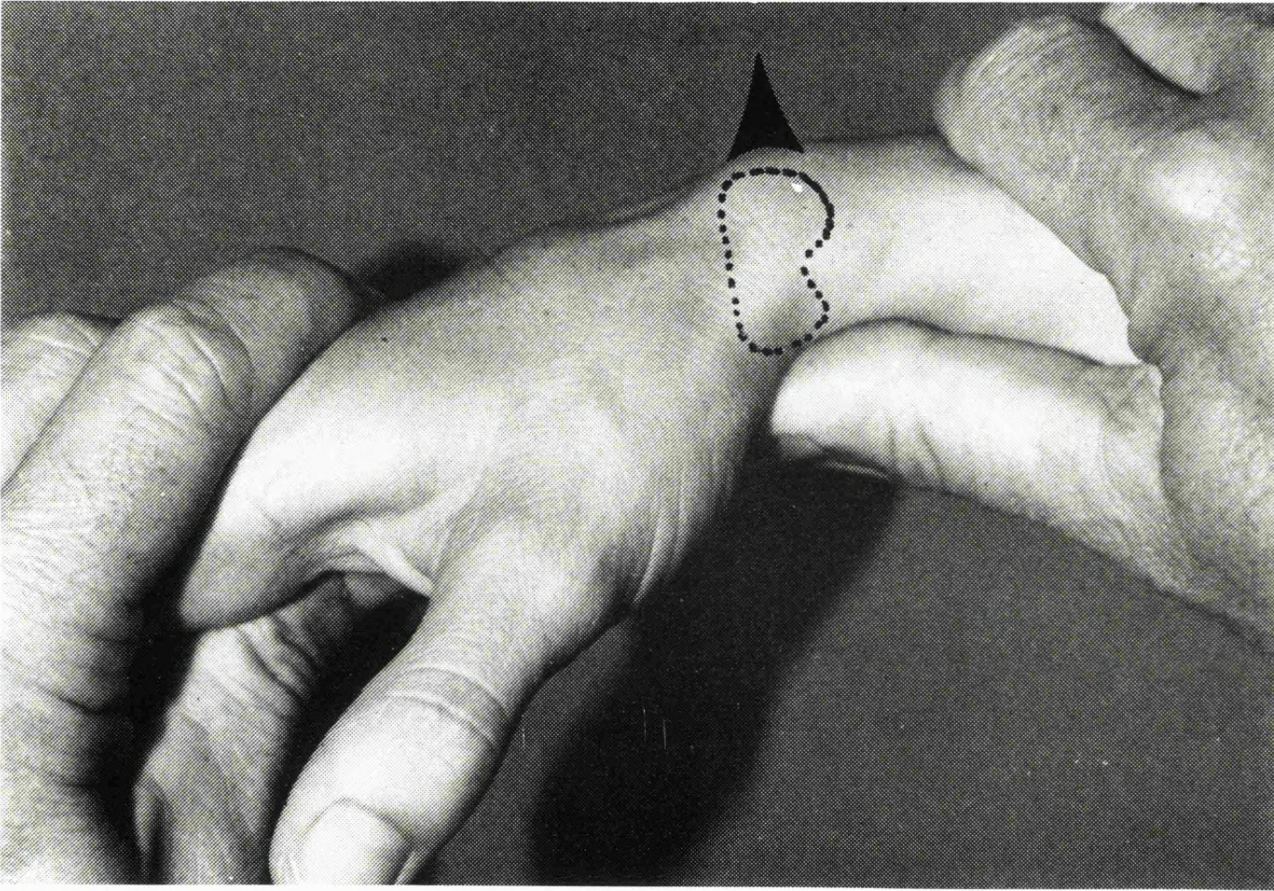
Careful palpation to determine the exact site and severity of tenderness is of paramount importance in the assessment of the injured wrist. Classically a scaphoid fracture is considered to produce marked tenderness in the anatomical snuff box. However, the mere fact that tenderness exists in the anatomical snuff box does not indicate a diagnosis of a scaphoid fracture. Todd (1921) stated, 'everyone is tender, to some extent, in the proximal half of the anatomical snuff box because of the dorsal branch of the radial nerve'. He suggested that nerve tenderness is never acute and usually subsides if pressure is sustained. Moreover it is equal to that experienced on the opposite side. Pressure in the anatomical snuff box causing a sudden 'wincing' and an attempt to snatch back the hand is suggestive of a significant injury or a very low pain threshold.

Movement of the wrist may cause pain. Extension of the wrist and radial deviation are usually restricted by pain. Todd (1921) suggested that wrist extension was always less than 45 degrees and that this restriction disappeared under anaesthesia. A clenched fist may produce pain in the radial aspect of the wrist as might

percussion over the second metacarpal head (Vaughan's test quoted by Todd 1921), percussion over the tip of the abducted and extended thumb. Alternatively, pain in the anatomical snuff box may be brought on by radial deviation and extension of the clenched fist. In all these tests pain must be localised to the anatomical snuff box or the radial aspect of the wrist to suggest a fracture of the scaphoid or suggest a significant ligamentous injury.

More recently Watson et al (1986) described a method of stressing the scaphoid in the context of assessment of the integrity of the scapho-lunate ligament. This test could be used for the assessment of the injured scaphoid in which doubt about the diagnosis exists. This test is conducted as follows : Pressure is exerted by one thumb on the tuberosity of the scaphoid (Figure 2.6-1) while the hand is moved from maximum ulnar deviation to maximum radial deviation. The production of tenderness during this manoeuvre suggests a significant injury to the scaphoid or to the scapho-lunate ligament.

Finally one would expect pain inhibition to adversely influence the patients grip strength and may even reduce his span.

FIGURE 2.6-1 : Scaphoid stress test

The thumb of the examining hand is placed over the tuberosity of the patients' scaphoid while the index finger is placed over the dorsum of the distal radius. Sustained pressure is applied over the tuberosity as the patients' hand is moved from maximum ulnar deviation to maximum radial deviation. In radial deviation, the proximal pole will tend to sublux dorsally (after Taliesnik et al 1986).

Most of these clinical findings were succinctly described by Alan Todd over half a century ago. He considered, 'it (was) incredible that anyone who was conversant with the physical signs of this fracture could ever miss a case'. What is surprising is that very few subsequent studies detail the clinical findings when proposing better methods of early assessment for scaphoid fractures !

C: EARLY DIAGNOSIS : RADIOGRAPHIC ASSESSMENT

Less than two months after the announcement of the discovery of x-rays by Roentgen, Etienne Destot (1864-1918) in Lyon was using these to assess injury. This led to the publication of his monograph, 'The wrist and the accidents at work. A radiographic and clinical study' in 1905. His great enthusiasm for this technique resulted in severe radiation damage to his hands forcing him to give up his commitments in 1913. He died in 1918 as the result of pneumonia while working as a medical officer on the Western front in World War I. During his career he described fractures and dislocations around the scaphoid and conducted a detailed study on this fracture.

After Roentgen discovered radiographs and for more than 20 years thereafter, only postero-anterior and lateral

radiographs were routinely used. There were some exceptions. In 1905, Codman and Chase reporting their findings in 30 patients, suggested that the postero-anterior view of the injured and opposite wrist be obtained in maximum ulnar deviation so that the extent of overlap of the scaphoid with other carpal bones be minimised. They recommended that radiographs of both wrists be taken on the same radiographic plate, in supination, pronation and in ulnar deviation for, 'this extends the scaphoid bone, that is, it lifts the distal end so that it comes nearer the plane of the proximal end.' In 1921, Todd proposed that the wrist be examined radiographically, 'antero-posteriorly and laterally, and sometimes obliquely as well' and mentioned the view described by Codman and Chase (1905). He explained that only those views which were obtained with the x-ray beam in the plane of the fracture were of any value, most other views would fail to show the fracture.

Toward 1930 it became obvious that postero-anterior and lateral views alone were not sufficient and that many fractures of the scaphoid could be missed shortly after injury, only to be diagnosed too late, when pseudarthrosis had developed (Taliesnik 1985). Additional views were recommended to detect this fracture. Ulnar deviation and some dorsiflexion of the

wrist designed to bring the normal volarflexed scaphoid to a plane parallel to the radiographic plate (Rothberg 1939) was also found to be useful (Stetcher 1937, Ziter 1973). This culminated in 1940 with Grazianni proposing 16 different views for an exhaustive radiographic study of wrist injuries. Fortunately, only four views are usually recommended: postero-anterior, lateral, semi-supine and semi-prone. Of these Leslie and Dickson (1981) considered that the postero-anterior and the semi-prone view were most reliable in demonstrating the fracture. In only 2.6 % of their cases was the fracture visible in only the lateral view or the semi-supine view. When a scaphoid fracture is strongly suspected on clinical grounds and routine radiographs fail to demonstrate it, additional views may be justified, designed to align the plane of the fracture with central rays. Ulnar deviation may be all that is required although Russe (1960) cautioned that ulnar deviation may cause distraction of the fracture fragments. Ziter (1973) described the method of obtaining an elongated image of the scaphoid with virtually no overlap of the adjoining carpal bones. The wrist is placed in slight flexion, pronation and the hand is placed in maximum ulnar deviation.

Scaphoid fractures are not usually visible on the lateral radiograph. This view is important, however, for

it allows the examiner to evaluate carpal alignment, and to detect the presence of a possible carpal instability pattern.

D: NORMAL APPEARANCES

The normal radiographic appearances can be mistaken for scaphoid fractures. This has been recognised from very early on. Todd (1921) and later Lindgren (1949) both described the two common errors in this respect. They suggested that if proper techniques were not employed it was easy to either overlook a fracture or to diagnose a fracture where none existed. This has been attributed to the individual variation of the scaphoid or the position of the hand when the x-ray is taken. They stated that sometimes the tuberosity stands out clearly and gives the impression of a step in the outer border of the scaphoid. This may suggest a fracture. These authors also pointed out that when the radiograph is taken in some radial deviation the scaphoid is flexed. On the postero-anterior view the lower rim of the tuberosity appears as a denser line which may be mistaken for a compression fracture of the waist of the scaphoid.

E: SOFT TISSUE SIGNS

Because routine radiography may miss the plane of the

fracture several authors have emphasised the importance of looking at soft tissue outlines on radiographs which may provide an indication of the severity of injury.

Terry and Ramin (1975) described the scaphoid fat stripe which, they said, is located between the combined tendon sheaths of the abductor pollicis longus and the extensor pollicis brevis and the lateral aspect of the scaphoid from which it is separated by the radial collateral ligament. The scaphoid fat stripe is seen on the postero-anterior view of the wrist as a thin radiolucent line paralleling the lateral surface of the scaphoid. This stripe is not seen in children under 12 years of age. These authors reviewed 438 radiographs of injured wrists. The scaphoid fat stripe was considered to be abnormal if it was either obliterated or displaced away from the scaphoid. Of 15 patients in their study who had a scaphoid fracture, 13 had an abnormal scaphoid fat stripe. However, they also pointed out that 4% of normal wrist radiographs may also demonstrate such an abnormality and stated that abnormality should alert the radiologist that an underlying fracture may be present.

Curtis et al (1984) reviewed 197 hand and wrist radiographs following injury and described the localised dorsal wrist swelling as seen on the lateral radiograph. This was normal when the dorsal soft tissue outline was

concave towards the wrist on a lateral radiograph in which the hand was in a neutral position (the metacarpals in line with the radius). The soft tissues were considered to represent a localised swelling if the outline was convex away from the carpal bones. They found that dorsal wrist swelling was usually associated with carpal fractures or dislocations.

Cetti and Christensen (1982) conducted a retrospective study of injured wrists and demonstrated that 73 of 78 patients with a scaphoid fracture had an abnormal scaphoid fat stripe while only 10 of 47 cases without a fracture had such an abnormality. They concluded that normal appearances in the radiograph taken at the time of the accident virtually excluded a fracture of the scaphoid. Haverling and Sylven (1978) repeated the study and emphasised the need to take adequate radiographs to demonstrate soft tissue outlines around the wrist. They too concluded that provided the soft tissues on adequate radiographs were normal a scaphoid fracture could be confidently excluded.

More recently, Carver and Barrington (1985) carried out a prospective study of radiographs in 200 patients with a clinically suspected scaphoid fracture and stated that they felt confident, 'to say that no fracture exists if the soft tissues are normal providing that the injury

occurred in the past 48 hours'.

SECTION 2.7

CLINICALLY SUSPECTED SCAPHOID FRACTURES

From very early on it has been recognised that initial radiographs may not demonstrate a fracture of the scaphoid which has been suspected clinically. This may be because none of the initial radiographs were obtained with x-rays in the plane of the fracture or the radiographs were of poor quality. Adams and Leonard (1928) suggested that in a clinically suspected scaphoid fracture if detailed radiography failed to demonstrate a fracture of the waist of the scaphoid, the wrist had to be splinted and a repeat radiographic examination conducted after 7 to 10 days. It has been suggested that resorbtion occuring at the fracture site may produce enough widening of the fracture line to allow its detection at that time. This advice has been repeated by most subsequent authors (Soto-Hall and Haldeman 1941, Rothberg 1939, Burnett 1934, Cleveland 1947, Hill 1970, Bohler et al 1954, Mazet and Hohl 1961, Russe 1960, Thorndike and Garrey 1940). Mclaughlin and Parkes (1969)

suggested that incomplete fractures without a haemarthrosis would heal under almost any circumstance. Leslie and Dickson (1981) in their review of 222 fresh fractures had 2% of the fractures in which initial radiographs were normal but subsequent radiographs revealed an incomplete 'compression' fracture of the scaphoid. They questioned the need for immobilisation of clinically suspected scaphoid fractures.

More recent studies (Duncan & Thurston 1985, Young et al 1988, DaCruz et al 1988) support this impression. Duncan and Thurston (1985) were unable to demonstrate a fracture in 108 patients in whom a scaphoid fracture was suspected clinically. These patients had spent an average of 21.9 days in a plaster cast which represented a significant loss of productivity to the community and caused inconvenience to the patient. They stated that it was inappropriate to treat such patients in a plaster cast.

Young et al (1988) reviewed 164 patients with a clinical diagnosis of a scaphoid fracture (half were retrospectively reviewed while the rest were collected prospectively) and were able to demonstrate a fracture on subsequent radiographs in only three instances. All these healed without complications. They suggested that the painful wrist be rested in a splint and reassessed

in three weeks. At this stage, however, their recommendation gets a bit confused. If a fracture is demonstrated the appropriate treatment is instituted but if no fracture can be seen and the wrist is still painful they recommend leaving the wrist free but advise further review after six weeks.

Finally, DaCruz et al (1988) prospectively studied 120 patients presenting with a clinically suspected fracture of the scaphoid. They had six scaphoid fractures of which 3 were, in fact, visible on the initial radiograph but were missed by the junior doctor. They suggested that if the initial radiographs failed to demonstrate a fracture the injured wrist should be rested in a sling and the patient reviewed in a weeks time. If the wrist was still painful but the radiographs were still negative, they recommended that it be splinted in a plaster cast for a further 3 weeks and then reassessed clinically and radiologically with or without a bone scan to establish the diagnosis.

It must be emphasised that all these studies make certain assumptions : (1) an adequate clinical examination of the injured wrist was carried out, (2) radiographic examination had all appropriate views and these were of good quality, and (3) that all these fractures represent incomplete crack fractures and would

heal uneventfully.

In difficult cases laminograms, trispiral tomography (Cooney et al 1980) and isotope bone scans have been recommended. Increased focal activity suggesting a fracture of the scaphoid has been demonstrated even if the fracture was not visible on radiographs obtained at that time (Ganel et al 1979, Jorgensen et al 1979). These bone scans could also provide information on the vascularity of the fracture fragments (Lichtman et al 1982).

SECTION 2.8

TYPE OF CAST

Once the fracture of the scaphoid is recognised, 'appropriate' treatment must be started. In the early part of this century, this involved resting the injured wrist in a splint for a short period of time (one to four weeks) followed by a period of massage for one month and then a gradual return to work over a two month period. The pendulum then swung the other way with Watson Jones (1948) stating that, 'all scaphoid

fractures will unite if immobilised well enough for long enough'. He also stated, 'every single movement of the wrist joint puts back the process of repair by several days. It is the neglected plaster cast which causes delayed union and non-union'. At present one of the few aspects (perhaps the only aspect) of scaphoid fractures on which there is universal agreement is that fresh fractures require immobilisation. However, both the position of the injured limb as well as the duration of immobilisation are subjects of debate and controversy.

A: THUMB IMMOBILISATION

Standard treatment of the scaphoid waist fracture consists of immobilisation of the wrist in a below elbow plaster cast with the thumb included upto the interphalangeal joint - the traditional scaphoid plaster. This is said to result in union within twelve weeks in around 95 % (Leslie & Dickson 1981). The remainder may require more prolonged plaster treatment or surgical fixation which itself may require a period of external splintage (Russe 1960, Herbert & Fisher 1984). Such protracted treatment makes this injury of considerable social and economic inconvenience to its victims who are predominantly young men (Leslie & Dickson 1981).

Despite its wide acceptance the use of the scaphoid

plaster is not universal. A simple dorsal slab with the thumb left free was considered adequate by Bohler et al (1954). On reviewing 580 of 734 cases accumulated over a 28 year period, a 96.5% union rate had been achieved and it was commented that in 35 who had the thumb included the non-union rate was even higher.

Others have considered inclusion of the thumb to be essential. Soto-Hall and Haldeman (1941) used a forearm cast with the wrist in extension and radial deviation and the thumb widely abducted to eliminate the effect of the abductor pollicis brevis which has part of its' origin from the tuberosity of the scaphoid. A 95 % union rate was achieved in four to five months by this method.

Stewart (1954) also included the thumb but considered position unimportant. He achieved a 95% union in a mixed series of fresh and old fractures immobilised for up to a year. Russe (1960) included the thumb metacarpal only to achieve 97% union by twelve weeks. Thumb immobilisation is thus of unproven benefit and may be a positive disadvantage. It also makes the cast more difficult to apply and slightly more expensive.

B: WRIST POSITION

Wrist position within the cast is also controversial. Berlin (1929) dissected 60 wrists post mortem and

concluded that the least separation of fracture fragments occurred in 45 % dorsiflexion and radial deviation. These findings were more recently confirmed by Thomaidis (1973). The position of dorsiflexion and radial deviation has been used in several studies (Soto-hall & Haldeman 1934, Burnett 1937). Squire (1959) recommended dorsiflexion and ulnar deviation but this position may distract the fragments and has been criticised (Fisk 1970).

C: ELBOW IMMOBILISATION

Cadaveric studies by Verdan (1960) suggested that pronation and supination of the forearm caused movement at the fracture site. For this reason above elbow casts have been used by several authors.

Broome et al (1964) with the forearm in a neutral position and the thumb included claimed a more rapid progression to union than with a standard cast (mean 11.4 weeks vs 16 weeks). This, however, was a very small series.

Goldman et al (1969) using the two types of cast in a non-randomised study in a rather elderly population found no difference in time to union. They did notice elbow stiffness in elderly patients placed in a long cast.

The thumb, wrist and forearm position in which osteotomised cadaveric scaphoids moved least when viewed through a windowed plaster was investigated by Thomaidis (1973). The ideal position was with the elbow at 90 degrees, forearm in the mid prone position, wrist 25 degrees dorsiflexed with 20 degrees of radial deviation and the thumb included to the interphalangeal joint, opposed to the middle finger. This position was tried in 25 patients and at 12.5 weeks 15 % were still considered to be ununited.

Alho et al (1975) using above and below elbow casts in a randomised group of approximately 50 patients each achieved 92% union (obliteration of the fracture line) in seven weeks in both groups. The above elbow casts were converted to below elbow forearm casts at six weeks and elbow stiffness thus avoided. Interestingly at twelve weeks delayed or non-union was present in four of the above elbow group and two of the below elbow group.

More recently King et al (1982) carried out further cadaveric studies and concluded that the forearm should be fully supinated with the wrist in full ulnar deviation and mid-dorsiflexion. They recommended this position under anaesthetic if necessary and claimed success particularly with delayed union or late treated

fractures. Their anatomical studies could be criticised for the degree of soft tissue dissection involved to demonstrate a clamping effect of the radial collateral ligament on the scaphoid in ulnar deviation. Additionally, studies on the pathomechanics of scaphoid fractures lead one to conclude that slight flexion of the wrist and radial deviation would be a more logical position (Weber 1980, Weber & Chao 1978, Kondoyannis 1982). The exact benefits of the above-elbow cast remain uncertain.

SECTION 2.9

DURATION OF IMMOBILISATION

Watson Jones stated that a scaphoid fracture should be immobilised until union had occurred even though prolonged immobilisation may be necessary. This view has been repeatedly emphasised (Dickison and Shannon 1944, Stewart 1954). Jahna (1954) applied to the scaphoid bone Pauwels' (1935) views on fracture of the neck of the femur. The more proximal the fracture the longer the period of immobilisation. The results obtained by these workers show that for fresh fractures near the middle of the bone an average time required for union was between

eight and twelve weeks. For older and more proximal fractures much longer periods of immobilisation were employed, 6 to 7 months of immobilisation has not been regarded as remarkable. In one case Robertson and Wilkins (1944) persisted with a plaster cast for 60 weeks before diagnosing union. They commended the man's patience but there seems to have been little else to commend in this instance.

While there is no controversy regarding the need for conservative management of scaphoid fractures (apart from highly unstable fractures associated with trans-scaphoid perilunate dislocation) the duration of immobilisation varies. One school of thought recommends prolonged immobilisation until union occurs while the other questions the wisdom of this and recommends early internal fixation. McLaughlin and Parkes (1969) suggested that the scaphoid fracture could be an 'economic catastrophe for the young male breadwinner' and put forward the concept that treatment should match the pathology. He suggested that all displaced fractures required internal fixation. Herbert and Fisher (1984) too, have recommended early internal fixation for displaced scaphoid fractures including open reduction and bone grafting. Finally Cooney et al (1980) also suggested that fractures, in which doubt about union existed at 12 to 16 weeks and in which special

investigations demonstrate a non-union, should be internally fixed.

Why do scaphoid fractures need longer immobilisation than most upper limb fractures ?

Johnson (1927) stated that carpal bones united slowly. He conducted an animal experiment to investigate union of scaphoid fractures in dogs. One scaphoid was divided while the opposite one was merely drilled. A fracture of the distal radius was used as a control. The dogs were serially killed and the three sites studied histologically. He demonstrated that in dogs, avascular necrosis was uncommon. Back death occurred from the site of the osteotomy and although there was early evidence of bone repair it was much more localised than the distal radius and not as active. The cartilage surface healed with fibrous tissue which formed a depressed line and there was increased scarring in the region of the ligament attachments. He attributed the slower response to the lack of periosteum.

SECTION 2.10

FACTORS AFFECTING UNION : FRACTURE MORPHOLOGY

Scaphoid waist fractures have been classified by Russe (1960) into transverse fractures, horizontal oblique fractures and verticle oblique fractures.

The transverse fractures, which in Russe's study (1960) were the most common (60%) are perpendicular to the long axis of the scaphoid but slightly oblique in relationship to the longitudinal axis of the radio-capitate link. Russe considered that these fractures should heal in six to twelve weeks provided that they were adequately immobilised. The horizontal oblique fractures are oblique to the long axis of the scaphoid but occur in the plane perpendicular to the longitudinal compressive forces acting across the wrist joint (Talesnik 1985). These fractures are considered to be most stable, offer the best prognosis and are expected to heal in six to twelve weeks. The rare vertical oblique fractures run almost parallel to the long axis of the forearm. They have a high shear component, are relatively unstable and are considered by some (Taleisnik 1985) to require longer immobilisation.

Leslie and Dickson (1981) too, suggested that non-union was more likely to occur in transverse and vertical oblique fractures.

In their large study, Bohler et al (1954) described the line of the fracture changing from the horizontal oblique position to the vertical oblique position. Of their 734 fresh fractures of the scaphoid 345 were horizontal oblique (47%), 366 were transverse (49.9%) and only 23 were vertical (3.1%). They, too, found that non-union occurred mostly in transverse and vertical oblique fractures. They compared this with the fracture of the neck of the femur where the more vertical the fracture line the more unstable the situation and the higher the complications !

SECTION 2.11

FACTORS AFFECTING UNION : FRACTURE DISPLACEMENT

Displacement of the fracture fragments during the healing phase has been shown to be more likely to be associated with a scaphoid non-union, especially if the displacement occurred during the course of treatment

(Leslie & Dickson 1981). In their study of 222 fresh fractures Leslie and Dickson (1981) had 11 non-unions. They found that non-union did not especially occur in fractures which were initially displaced but 18 % (n=2) of the cases occurred in those fractures which displaced during treatment. Such displacement occurred in only 3 % of patients in whom the fracture united.

Displacement has been defined as greater than one millimeter offset on the anteroposterior or oblique radiograph, greater than 15 degrees of luno-capitate angulation of the lateral radiograph or greater than 45 degrees of scapho-lunate angulation also on the lateral radiograph (Cooney et al 1980). Monsivais et al (1986) found that 85% of the patients in their series of non-unions were displaced or displaced during treatment. Several authors have equated displacement with instability, greater displacement implying greater soft tissue injury and instability (McLaughlin and Parkes 1969, Lichtman and Alexander 1982, Weber 1980). Weber (1980) found that when one of the ligaments was disrupted, there was a fracture angulation with abnormal lunate rotation (DISI pattern - dorsal intercalated segment instability). If both dorsal and volar ligaments were torn, displacement of the fragments occurred with a step-off on the capitate side.

SECTION 2.12

FACTORS AFFECTING UNION : AVASCULARITY

The nature of the blood supply of the scaphoid (described in detail in section 1.4) renders its' proximal part susceptible to avascular necrosis. 70 % to 80 % of the scaphoid, including the proximal pole, receives blood from vessels entering through the dorsal ridge. The tuberosity and the distal 20 % to 30 % of the bone is supplied by volar branches of the radial artery. There are no significant intraosseous anastomoses between the dorsal and volar branches. Obletz & Halbstein (1938) demonstrated that in 33% of 297 scaphoids studied there were either no foramina or a single small foramen proximal to the waist. They suggested that in such scaphoids the blood supply to the proximal pole was precarious. It is, perhaps, in such scaphoids that vascularity is seriously compromised by a fracture making them susceptible to non-union.

A: AVASCULARITY & RECENT FRACTURES

It has been suggested that avascularity is one of the factors in the pathogenesis of non-union (Cooney et al 1980). The incidence of radiographic evidence of

avascular necrosis of the proximal part of the scaphoid in recent fractures varies from 1 to 44 % (Leslie & Dickson 1981, Bohler et al 1954, Russe 1960). It has been emphasised (Russe 1960) that increased density is not a sign of impending non-union and does not contraindicate continued conservative treatment (Stewart 1954). The increased radiological density usually improves although it might persist for several years (Bohler et al 1954).

B: AVASCULARITY & FAILURE OF UNION

Herbert stated that 50% of fractures of this bone which demonstrated delayed union showed signs of ischaemia. The reported incidence of radiographic evidence of avascular necrosis in patients with an established non-union of scaphoid waist fractures varies from 9% to 40 % (Leslie & Dickson 1981, Cooney et al 1980, Mulder 1968). Ruby et al (1985) in their study on long term results of scaphoid fracture non-union, however, were surprised to note that only 2 of 55 patients had increased density of the proximal part of the scaphoid on radiographs.

SECTION 2.13

CARPAL INSTABILITY & SCAPHOID NON-UNION

Fisk (1970) noted that the fractured scaphoid rarely united in the presence of carpal instability. He concluded that the fracture with potential non-union was not an isolated injury, but was associated with perilunate ligament damage. He conceived the scaphoid as a part of a system bridging the mid carpal joint. With a fracture of the scaphoid bone and extensive soft tissue damage there is a resultant 'concertina' deformity. The scaphoid ceases to support the midcarpal joint and with severe soft tissue injury the midcarpal joint fails to support the broken scaphoid and a loss of stability results.

Carpal instability can be demonstrated by a variety of methods. Monsivais et al (1986) were impressed with the patients complaint of weakness, aching and a perception of a click in the wrist. The physical examination in these patients demonstrated focal tenderness, a palpable click with power grip or ulnar deviation and abnormal antero-posterior mobility of the wrist. Lateral radiographs demonstrated that many of the non-unions in

their study were associated with a dorsal intercalated segment instability (DISI) pattern with the lunate facing backwards. Arthrography was considered especially useful as it determined the extent of ligamentous disruption. They felt that scaphoid non-union was consistently associated with carpal instability. They suggested that fractures which displaced during treatment represented the ones with ligamentous damage and in one of their cases they were able to document a DISI pattern of collapse and produce a 'positive' arthrogram.

Mack et al (1984) in their study on the natural history of scaphoid fracture non-union found that the incidence of carpal instability increased with the duration of the non-union with 50% of non-unions less than 10 years old demonstrating this pattern while 94% of the non-unions over 20 years old showing carpal instability. Cooney et al (1980), too, stated that the DISI pattern did not develop acutely but occurred progressively with time. Vender et al (1987) in their study of degenerative change in symptomatic scaphoid non-unions found that the pattern of arthritis was that expected in a scapho-lunate advanced collapse wrist resulting from the rotatory subluxation of the distal scaphoid fragment. They demonstrated that instability was progressive and was associated with an earlier onset of arthritis.

Burgess (1987) in a cadaveric study on the effect of scaphoid malunion on wrist motion demonstrated that when the distal part of the scaphoid was flexed on the proximal part by 15 degrees there was significant loss of wrist extension; when the angulation was increased to 30 degrees some mid-carpal extension was also lost. In a separate study (Burgess 1987) it was demonstrated that rotatory subluxation of the scaphoid of 5 degrees reduced the contact of the proximal pole with the radius by 44%; while 20 degrees of subluxation reduced the contact by 77%. He suggested that these observations explained the progression of radio-scaphoid arthritis from the radial styloid proximally. Such a pattern would reflect the clinical observation that degenerative change following scaphoid non-union predominantly affects the articulation between the radial styloid and the distal part of the scaphoid (Vender et al 1987).

The question remains : is the instability the cause of the non-union or is it the result of the non-union ?

SECTION 2.14

FACTORS AFFECTING UNION : THE ROLE OF NON-COMPLIANCE

In a small percentage of non-unions of scaphoid fractures repeated attempts at achieving union can fail (Mazet and Hohl 1963). Kim et al (1983) suggested that these may well be related to non-compliance on the part of the patient. They found that only 15 of 28 wrists with one bone graft attempt achieved union and noted that patients with psychiatric disorders had a higher incidence of failure of treatment. Barr et al (1953) did actively seek a possible relationship between psychological factors and union of scaphoid fractures in a military population but could not find a significant association. Kim et al (1983), however, cautioned that a definite cause and effect relationship could not be proved. They suggested that when conventional treatment was unsuccessful and the results deviate greatly from what one would expect, the presence of associated psychiatric problems should be considered. The most common psychiatric illness encountered in their study was paranoid schizophrenia. These patients tended to be non-compliant (Freedman et al 1975) and appeared to have poor co-ordination, to be unpredictable and to have

difficulty in co-operating with other people. They were also at high risk of self mutilation and suicide. These authors pointed out that patients with psychiatric illness tended to have poor surgical and clinical results in general and were difficult to treat.

Section 3

Experimental Studies

SECTION 3.1

THE VALUE OF RADIOGRAPHIC ASSESSMENT OF SOFT TISSUE SIGNS IN THE DIAGNOSIS OF SCAPHOID FRACTURE

The troublesome sequelae of non-union of scaphoid fractures has led to a greater emphasis on early diagnosis. It has been established that soft tissue swelling noted on radiographs of the injured part is associated with fractures, and should alert the treating surgeon to the possibility of such an injury, even when the fracture is not visible (Curtis et al 1984; Terry and Ramin 1975). In fractures of the scaphoid, both dorsal wrist swelling, as seen on a lateral radiograph (Curtis et al 1984), and radial shift, or obliteration of the scaphoid fat stripe, on a postero-anterior radiograph (Terry and Ramin 1975) have been documented.

Some recent studies (Carver and Barrington 1985; Haverling and Sylven 1978) have suggested that when these signs were absent in patients presenting with pain in the radial side of the wrist following an injury, a fracture of the scaphoid could be confidently excluded. Conversely, the presence of these signs almost always indicated an underlying fracture (Cetti and Christensen

1982, Haverling and Sylven 1978).

The radiographs of a group of patients presenting with clinically suspected scaphoid fractures were reviewed to determine whether a scaphoid fracture could be present when both these signs were normal and to determine the prevalence of scaphoid fractures when these signs were abnormal.

PATIENTS

The radiographs of 127 patients referred from the Accident and Emergency department to the Orthopaedic Trauma Unit, Leicester Royal Infirmary, with suspected scaphoid injuries between October 1980 and June 1983 were reviewed. Their mean age was 25.8 years (range 13 to 61 years). Seventy six were men and fifty one were women. Twenty one patients who presented more than two days after injury were not included, as their soft tissue signs might have altered (Carver and Barrington 1985; Terry and Ramin 1975).

In 69 patients the scaphoid fracture was visible on the initial radiographic views. These patients were treated in a plaster cast for 6 to 12 weeks. The remaining 58 patients, in whom no fracture was initially visible, were treated in a scaphoid cast for approximately 2 weeks, at which time repeat radiographic examination was

carried out. These repeat radiographs demonstrated fractures in eight of the 58 patients (three lunate chip fractures, two radial styloid fractures and three scaphoid fractures).

METHOD

The initial radiographs were reviewed to document the soft tissue signs. The scaphoid fat stripe was noted on standard postero-anterior radiographs as being either normal, when it was concave towards the scaphoid, or abnormal (Figure 3.1-1), when it was convex away from the scaphoid or obliterated (Cetti and Christensen 1982; Terry and Ramin 1975). Similarly, the dorsal wrist soft tissues (Figure 3.1-2), as seen on the lateral radiograph with the wrist in neutral, were documented as normal, when concave towards the carpal bones, or abnormal, when convex away from the carpal bones (Carver and Barrington 1985; Curtis et al 1984). The initial and subsequent radiographs were then carefully scrutinised for scaphoid fractures and fractures of other carpal or metacarpal bones and those of the radial styloid.

RESULTS

No fractures were visible on the initial or subsequent radiographs in 50 patients. Seventy two patients had scaphoid fractures: 61 had fractures of the waist of the

scaphoid, six had fractures of the tuberosity, and five had fractured the proximal pole. Five patients had fractures of other bones: three had dorsal chip fractures of the lunate, while two had a radial styloid fracture.

A: SCAPHOID FAT STRIPE

Ninety one patients had an abnormal scaphoid fat stripe on postero-anterior radiographs (Table 3.1-I). It was shifted in 50 and obliterated in 41. Excluding the patients with other fractures, 88 patients had an abnormal scaphoid fat stripe. Of these, 60 (68.2%) had a scaphoid fracture. In the remaining 28 patients with an abnormal fat stripe no fracture was visible on the initial or subsequent radiographs.

B: DORSAL WRIST SWELLING

Ninety seven patients had abnormal dorsal wrist swelling (Table 3.1-I). Again excluding the patients with other fractures, of the remaining 92 patients 63 (68.5%) had a scaphoid fracture. Twenty nine patients, therefore, had dorsal wrist swelling but did not have an obvious fracture.

Abnormality in both the scaphoid fat stripe and dorsal wrist swelling, was present in 75 patients of whom 55 (73.3%) had scaphoid fractures.

DISCUSSION

It has been suggested that if either the dorsal soft tissues (Carver and Barrington 1985; Haverling and Sylven 1978) or the scaphoid fat stripe (Cetti and Christensen 1982) are normal on initial radiographs in patients with clinically suspected scaphoid fractures, one can virtually exclude such a fracture.

A: FALSE NEGATIVE RESULTS

Carver and Barrington (1985) could not demonstrate a fracture in 88 (of 200) patients with suspected scaphoid injuries in whom the soft tissue signs were normal. However, as only 61 patients in their study had repeat radiographs, they could not have conclusively excluded all scaphoid fractures. In the present study 26.9% (Table 3.1-I) of patients without dorsal wrist swelling had scaphoid fractures. A comparable incidence of false negative results (31.4%) was recorded for the scaphoid fat stripe. This incidence was much higher than that documented by Cetti and Christensen (1982), who noted that 13.5% of 42 patients with normal fat stripes had scaphoid fractures. Our results suggest that a scaphoid fracture may be present even when the soft tissue signs are normal. The reasons for this may be that special soft tissue imaging techniques have not been used (Curtis et al 1984; Haverling and Sylven 1978), and that

radiographs were obtained before oedema had occurred (Terry and Ramin 1975).

B: FALSE POSITIVE RESULTS

The value of abnormal soft tissue signs in the early diagnosis of scaphoid fractures has been stressed by all previous articles on the subject. The documented incidence of false positive results in patients with suspected scaphoid injuries varies from 12.1% (Cetti and Christensen 1982) to 17.5% (Haverling and Sylven 1978). Our results suggest that the incidence of an abnormal scaphoid fat stripe without an underlying fracture is much higher (32.5%). A similar proportion (33.1%) of patients with dorsal wrist swelling, too, had false positive results. Carver and Barrington (1985) recorded a 64% false positive rate (49 of 76 patients with suspected scaphoid fractures, excluding their 36 fractures involving the distal radius, pisiform, triquetrum and ulnar styloid, which could not be considered as possible scaphoid fractures on careful clinical examination). They did not provide details for the scaphoid fat stripe and dorsal wrist swelling separately.

False positive findings probably reflect a rupture of the ligaments on the radial side of the wrist, traumatic tenosynovitis (DaCruz et al 1986), or contusion.

Moreover, a shift or obliteration of the scaphoid fat stripe has been noted in 4% (Terry and Ramin 1975) to 6.4% (Cetti and Christensen 1982) of normal wrist radiographs.

CONCLUSION

Although any radiographic abnormality in the scaphoid fat stripe or dorsal soft tissues of the injured wrist should alert the treating surgeon to the possibility of a bony injury, it must be appreciated that approximately one in three patients with such abnormality might have no fracture. Conversely, approximately one in four patients with normal soft tissue signs might still have a scaphoid fracture.

Table 3.1-I. Relationship of soft tissue signs and scaphoid fractures

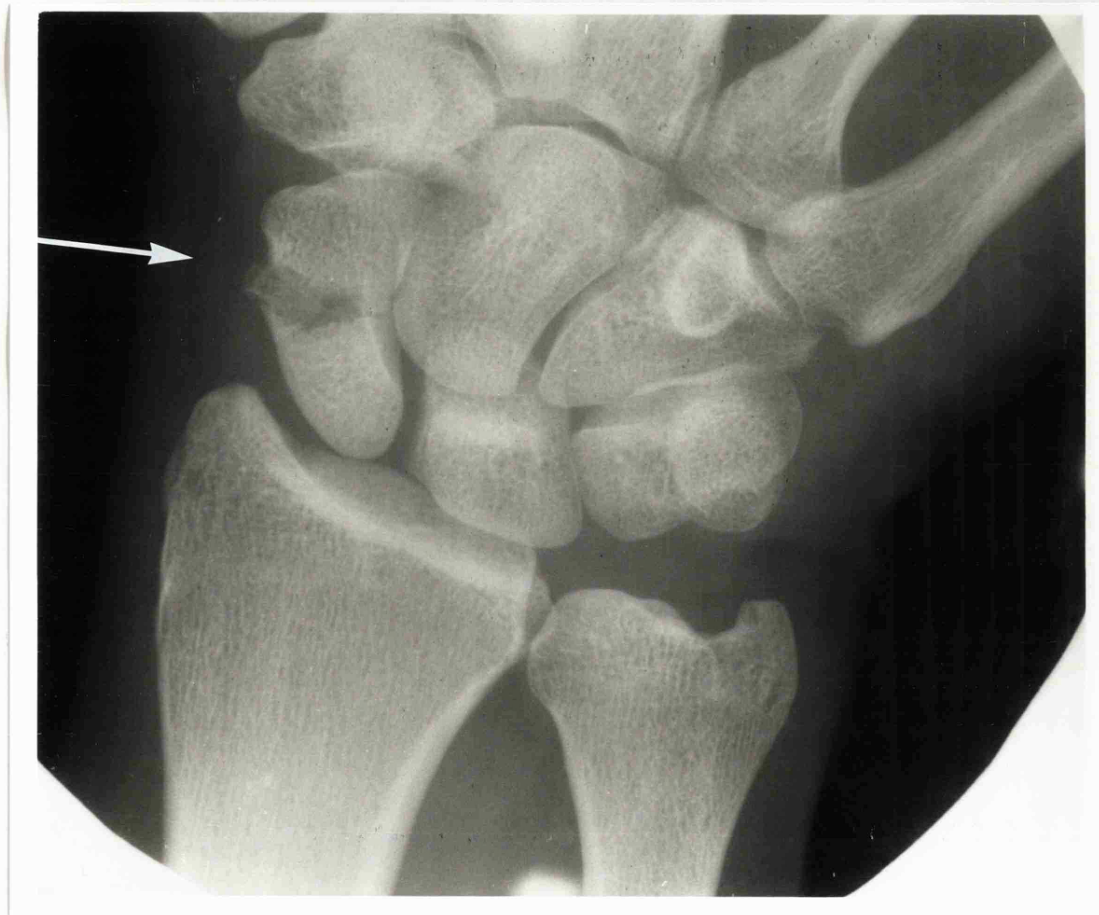
Scaphoid fat stripe (n = 126 *)				
	<u>Normal</u>	<u>Shifted</u>	<u>Obliterated</u>	<u>Total</u>
No fracture	22	13	15	50
Scaphoid fracture	11	35	25	71
Other fractures	2	2	1	5
Total	35	50	41	126

Dorsal wrist swelling (n = 123 **)				
	<u>Normal</u>	<u>Shifted</u>	<u>Equivocal</u>	<u>Total</u>
No fracture	19	29	0	48
Scaphoid fracture	7	62	1	70
Other fractures	0	5	0	5
Total	26	96	1	123

* In one patient the radial deviation of the wrist, as judged by the orientation of the third metacarpal to the radius, precluded comment on the state of the scaphoid fat stripe.

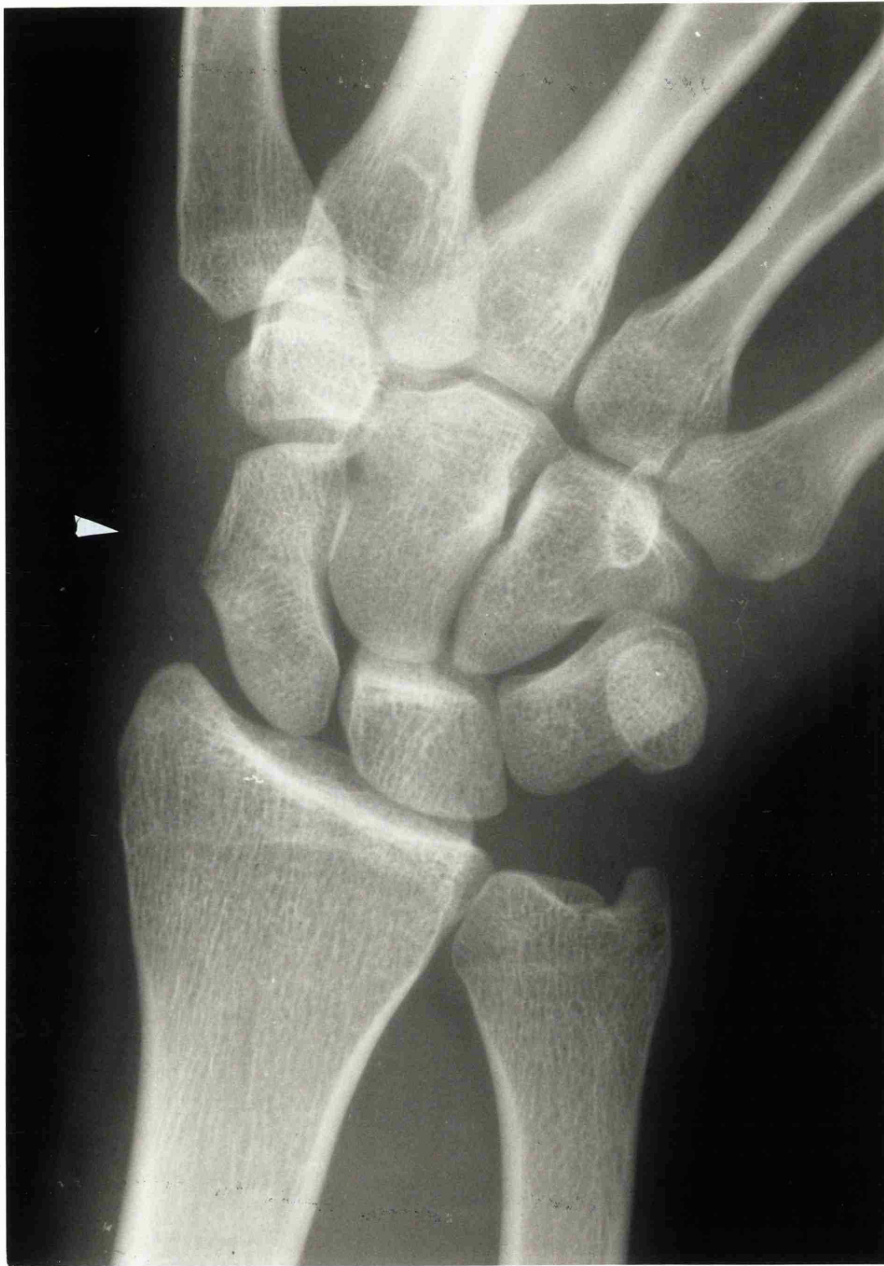** In four patients the lateral radiographs were obtained with the wrist in moderate dorsiflexion and the dorsal soft tissues appeared convex away from the carpal bones.

FIGURE 3.1-1 a : Shifted scaphoid fat stripe



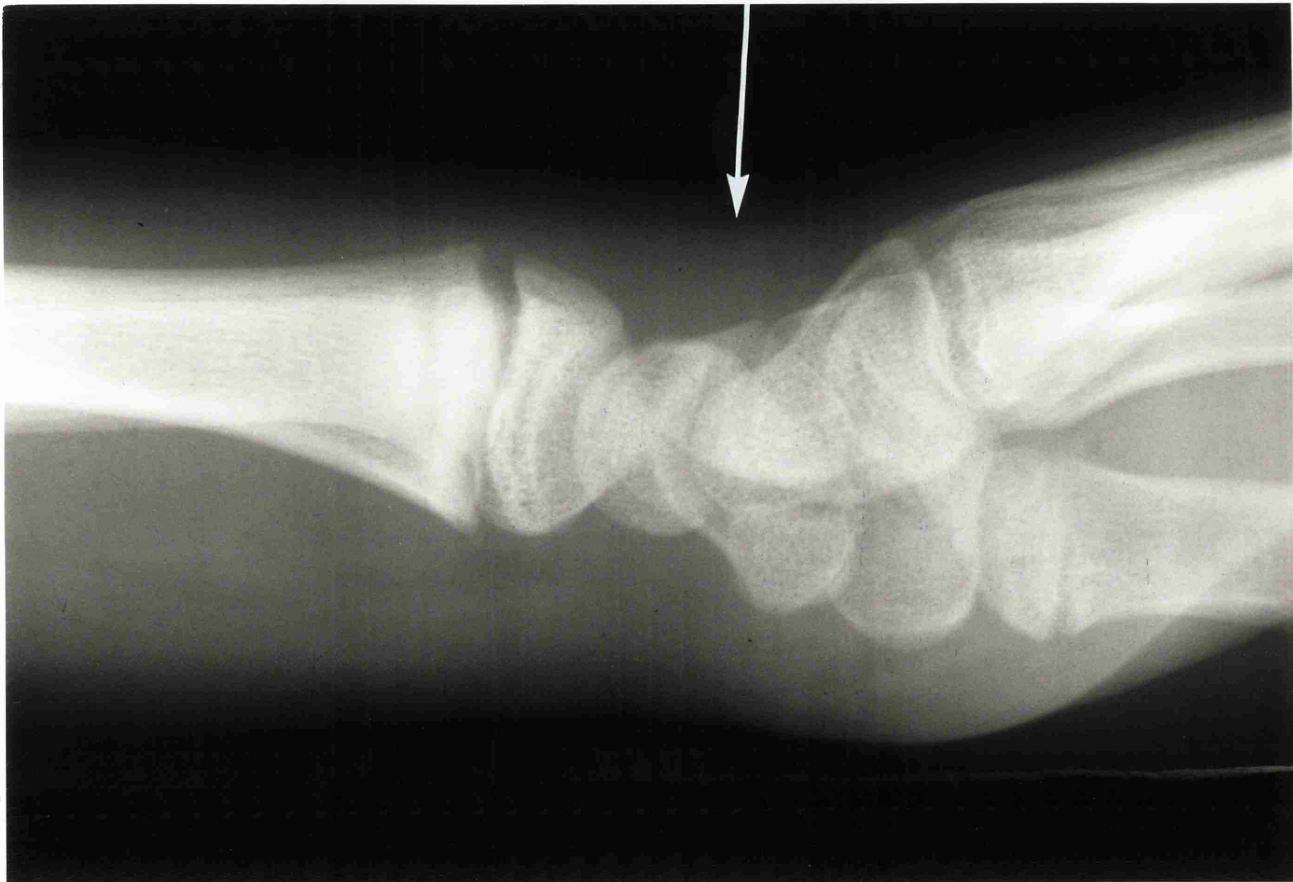The scaphoid fat stripe (arrow) is the radiolucent line extending distally from the radial styloid. (a) Fractured scaphoid showing a shifted fat stripe.

FIGURE 3.1-1 b : Obliterated scaphoid fat stripe



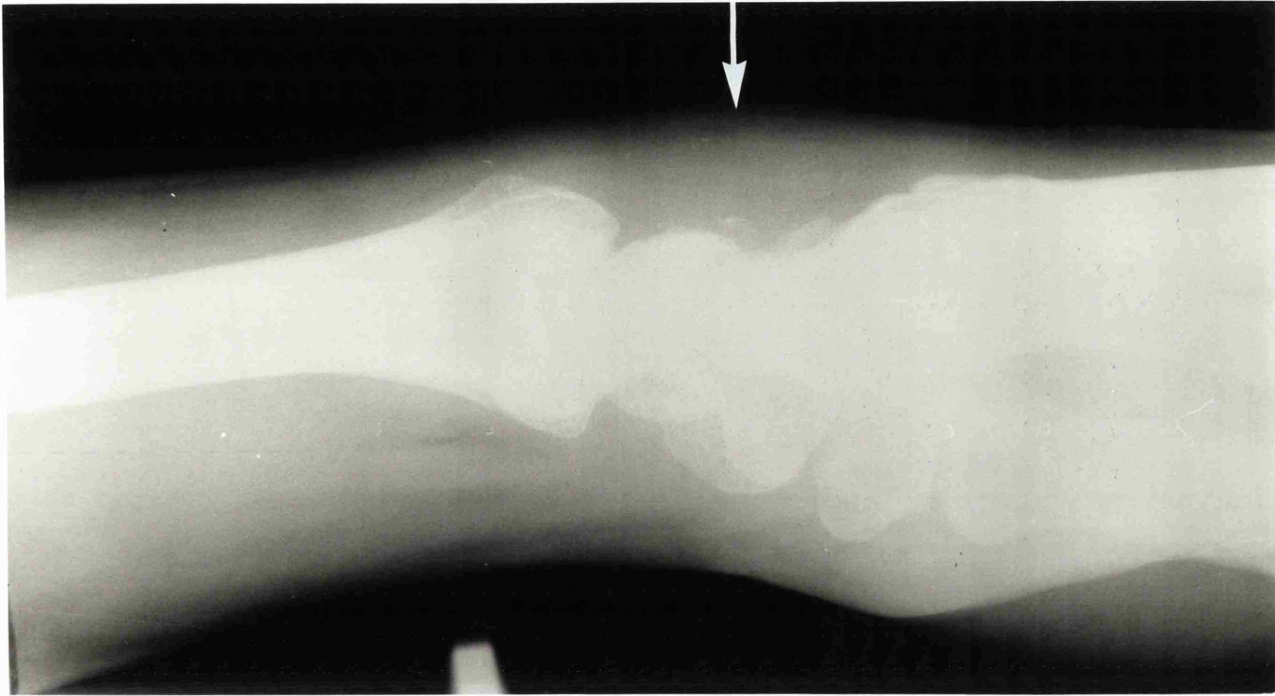
The scaphoid fat stripe (arrow) is the radiolucent line extending distally from the radial styloid. (b) Probably fractured scaphoid demonstrating obliteration of the fat stripe.

FIGURE 3.1-2 a : Normal dorsal wrist swelling



Normal dorsal wrist soft tissues concave towards the carpal bones. (the dorsal soft tissues are demonstrated by the arrow)

FIGURE 3.1-2 b : Abnormal dorsal wrist swelling



Dorsal wrist swelling convex away from the carpal bones.
(the dorsal soft tissues are demonstrated by the arrow)

SECTION 3.2

**THE VALUE OF MULTIPLE RADIOGRAPHIC VIEWS IN THE
ASSESSMENT OF ACUTE SCAPHOID INJURIES**

The scaphoid bone has an oblique orientation, the distal part lying anterior, radial and distal in relation to the proximal pole. In most radiographic projections, therefore, other carpal bones overlap the scaphoid to a varying degree. This makes the imaging of this bone difficult. In the assessment of a clinically suspected fracture of the scaphoid different authors have suggested a number of radiographic views, from the simple two plane radiographs (postero-anterior and lateral) to the four views (postero-anterior, lateral, semi-prone and semi-supine) recommended by Russe (1960). It is now common to include a fifth elongated view of the scaphoid (Ziter 1973) which has the minimum overlap of the surrounding carpal bones. Grazianni (1940) went as far as to suggest 16 different projections of the scaphoid. The reason for such comprehensive radiographic assessment of the scaphoid has been the observation that any delay in treatment could result in failure of bony union of a fractured scaphoid.

In a prospective study on the treatment of this fracture, the value of the five different views in establishing the diagnosis was investigated.

METHOD

Ninety seven consecutive initial radiographs of patients with scaphoid fractures who were entered into the prospective study were assessed. Each patient had five views of the scaphoid : the postero-anterior, lateral, semi-prone, semi-supine and Ziter (1973) view. Each of the views was studied to establish whether or not the fracture could be easily seen. In addition, the fracture was classified according to Bohler et al (1954) and Herbert and Fisher (1984). Chi square analysis was then conducted on the cross-tabulation of the results.

RESULTS

97 patients were included. The standard four views were available in all while the Ziter view was available in 89 patients. Table 3.2-I demonstrates the distribution of the type of fracture classified according to Bohler et al (1954) and Herbert & Fisher (1984).

A: RADIOGRAPHIC VIEWS DEMONSTRATING THE FRACTURE

Around three-fourths of the fractures were not easily seen on the lateral, semi-supine or semi-prone views. Most fractures were easily seen on the postero-anterior

and, in particular, the Ziter view. This is illustrated in the bar graph in figure 3.2-1.

B: FRACTURE TYPE vs RADIOGRAPHIC VIEW

Regardless of the Bohler type of fracture, it was well visualised on the postero-anterior and Ziter views. A proportion of horizontal oblique and distal fractures were also seen on the lateral and semi-supine views. This is illustrated in figure 3.2-2.

Crack fractures and distal fractures were usually only seen on the postero-anterior and Ziter views. Although a proportion of the distal third oblique fractures, displaced fractures and comminuted fractures were seen on the lateral, semi-supine and semi-prone views, these were also clearly demonstrated on the postero-anterior and Ziter views (Figure 3.2-3).

DISCUSSION

A: THE VALUE OF DIFFERENT RADIOGRAPHIC VIEWS

Untreated scaphoid fractures and those in which treatment is delayed may not unite. This, coupled with the difficulty of adequately visualising the scaphoid on radiographs, has led to the recommendation of between 2 and 16 (Grazianni 1940) views of the injured scaphoid in order to exclude a fracture. Some have even suggested early scintigraphy to establish the structural integrity

of the scaphoid.

The present investigation suggests that most fractures can be easily seen on the postero-anterior and Ziter views and that the lateral, semi-prone and semi-supine views do not appear to provide any additional information. This is in agreement with Leslie & Dickson (1981) who found the Postero-anterior view to be most reliable in demonstrating the fracture. In their study the lateral view showed the fracture in only 2.6% of 220 fractures. The Ziter view was not assessed.

B: RECOMMENDATION REGARDING EARLY RADIOGRAPHIC ASSESSMENT

These findings suggest that when a scaphoid fracture seems likely on clinical findings (wrist injury, swelling in the anatomical snuff box and the dorsum of the wrist, tenderness in the anatomical snuff box and tenderness on stressing the scaphoid as suggested by Watson et al 1986) the two standard views of the wrist (Ziter view or the postero-anterior view and the lateral view) provide adequate initial assessment. Although the lateral view is not sensitive for scaphoid fractures it does provide valuable information about carpal alignment.

C: ADDITIONAL REASONS FOR THIS RECOMMENDATION

(1) It has been demonstrated (section 3.3) that in clinically suspected scaphoid fractures in which a fracture was not easily visible on five radiographic views, there was significant disagreement between observers as to whether or not the scaphoid was fractured. In addition, these observers also misinterpreted overlap lines and vascular lines in the normal scaphoid as representing a fracture. Interpretation of scaphoid radiographs when the fracture is not immediately visible can be very difficult (Section 3.5). In such injuries a very small number have subsequently been diagnosed as a scaphoid fracture (DaCruz et al 1988).

(2) Leslie & Dickson (1981) suggested that incomplete fractures (2% of 220 fractures) always progress to union. This impression was supported by Herbert & Fisher (1984) who found that crack fractures without any displacement or comminution almost always united. It has also been suggested that delay in treatment for upto one month does not adversely influence fracture union (Eddeland et al 1975) .

(3) Finally, if comprehensive radiographic evaluation failed to demonstrate an obvious fracture currently accepted practice is to immobilise the injured wrist on

clinical suspicion and to reassess this wrist clinically and radiographically after an interval of two to three weeks (DaCruz et al 1988). At this interval if the signs and symptoms have persisted a more comprehensive radiographic assessment could be conducted.

D : POSSIBLE BENEFITS

I believe that this protocol has several advantages :

- (1) the demands on the acute radiographic services would be reduced as would be the cost of the investigation,
- (2) the exposure of the patient to radiation would be more than halved and
- (3) the quality of the subsequent radiographic evaluation would be better as it would be done in clinic hours by experienced staff and not in a busy accident service environment.

CONCLUSION

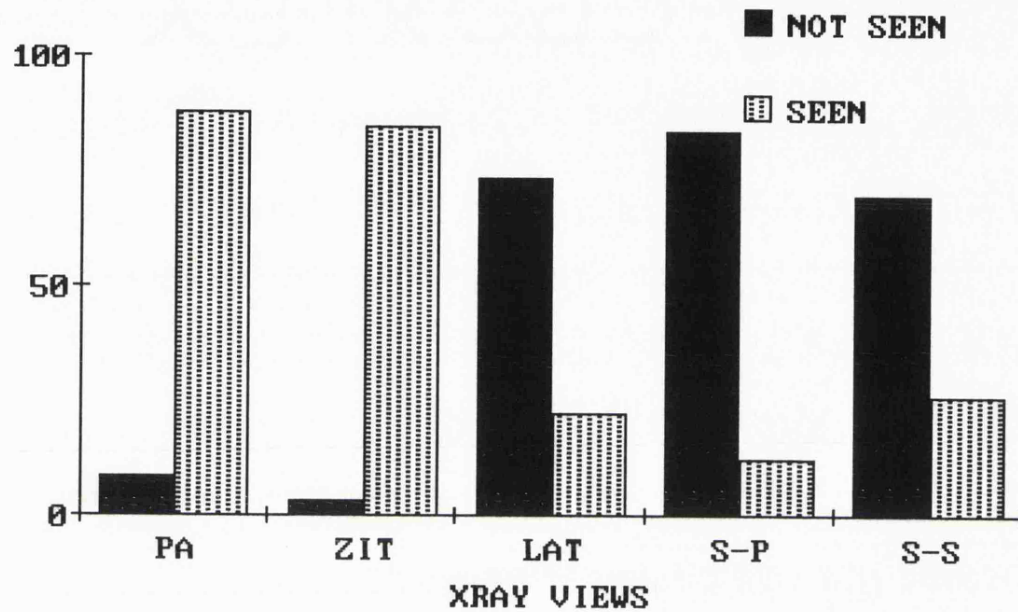
This investigation suggests that the Ziter view and the lateral view of the injured scaphoid provide adequate initial radiographic assessment of a clinically suspected scaphoid fracture.

Table 3.2-I : Type of fracture

Bohler et al classification :		
Distal pole	14	14.4%
Horizontal oblique	21	21.6%
Vertical oblique	3	3.1%
Transverse	58	59.8%
Proximal pole	1	1.0%
Total	97	

Herbert & Fisher classification		
Crack	26	26.8%
Distal 1/3 oblique	27	27.8%
Displaced fracture	25	25.8%
Comminuted fracture	14	14.4%
Tuberosity	5	5.2%
Total	97	

FIGURE 3.2-1 : Visibility of scaphoid fractures on different views

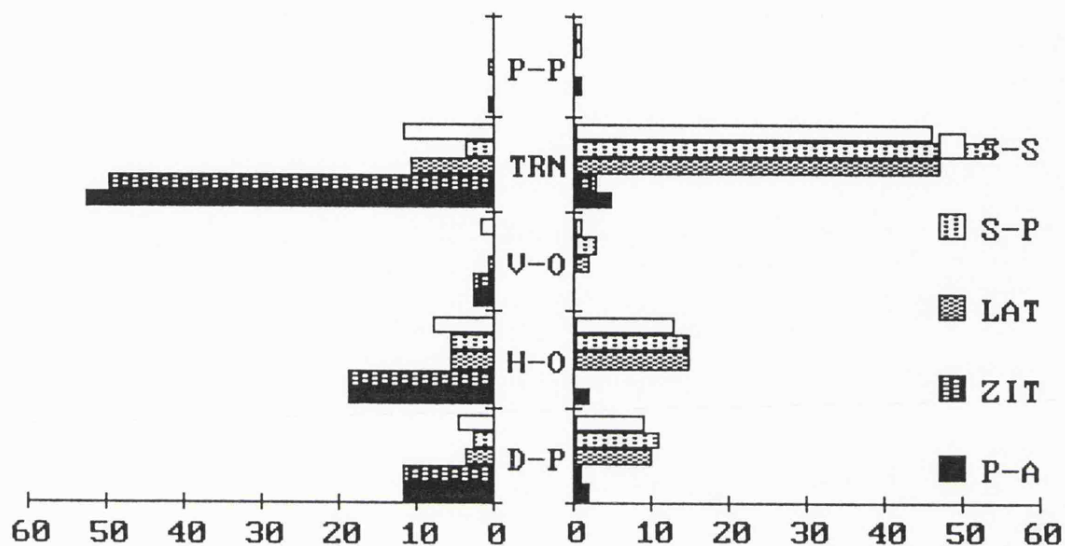


DATA TABLE 3.2-1 : Visibility of fractures on different views

	Not seen	Seen
Postero-anterior	9	88
Lateral	74	23
Semi-prone	84	13
Semi-supine	70	27
Ziter	4	85

The bar graph demonstrates that most scaphoid fractures are easily seen on the Ziter view and the postero-anterior view. Figures refer to number of patients

FIGURE 3.2-2 : Bohler type of scaphoid fracture vs radiographic view

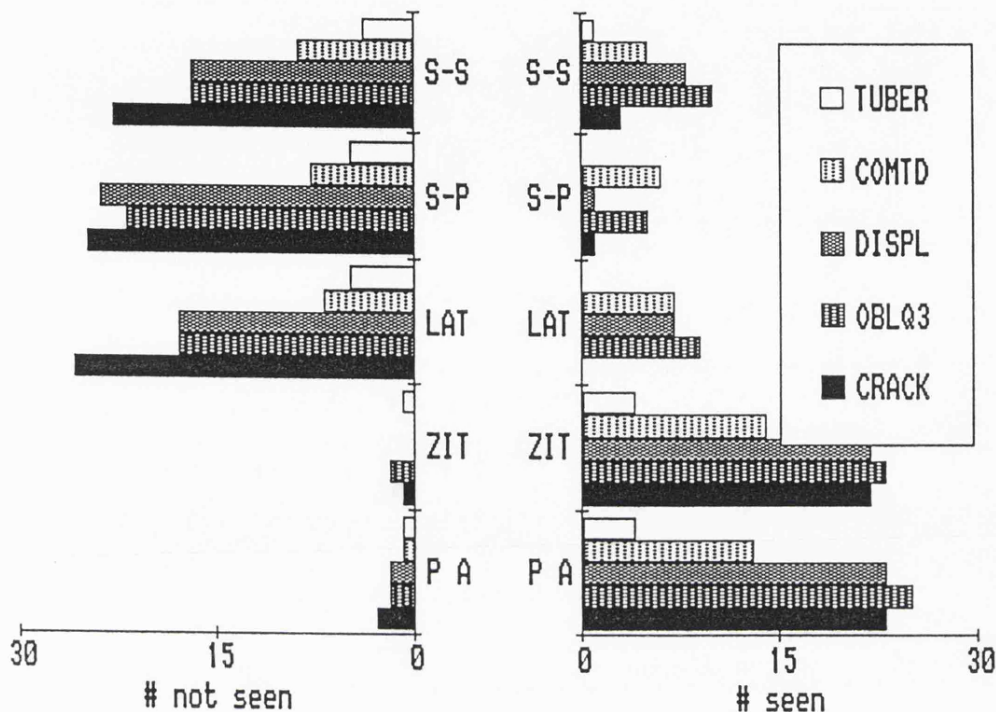


DATA TABLE 3.2-2 :

n=	PA 97	LAT 97	S-P 97	S-S 97	ZIT 89
D-pole	12/2	4/10	3/11	5/ 9	12/1
H-oblq	19/2	6/15	6/15	8/13	19/0
V-oblq	3/0	1/ 2	0/ 3	2/ 1	3/ 0
Trans	53/5	11/47	4/54	12/46	50/ 3
P-pole	1/0	1/ 0	0/ 1	0/ 1	0/ 1
$\chi^2 =$	0.85	4.55	7.67	5.64	2.73
p =	0.093	0.336.	0.104	0.227	0.997

Data is presented as SEEN/NOT SEEN for each type of fracture on each view. χ^2 - chi square, p - probability. Regardless of the Bohler type of fracture, it was well visualised on the postero-anterior and Ziter views. A proportion of horizontal oblique and distal fractures were also seen on the lateral and semi-supine views.

FIGURE 3.2-3 : Herbert & Fisher type of scaphoid fracture vs radiographic view



DATA TABLE 3.2-3 :

n=	PA 97	LAT 97	S-P 97	S-S 97	ZIT 89
CRACK	27/4	0/31	1/30	4/27	26/2
OBLQ-1/3	25/2	9/18	5/22	10/17	23/2
DISPL	23/2	7/18	1/24	8/17	22/0
COMM	13/1	7/7	6/ 8	5/ 9	14/0

$\chi^2 =$	1.07	16.62	15.80	5.37	10.60
$p =$	0.897	0.002	0.003	0.251	0.563

Crack fractures and distal fractures were seen on the postero-anterior and Ziter views. Although a proportion of the distal third oblique fractures, displaced fractures and comminuted fractures were seen on the lateral, semi-supine and semi-prone views, these were also clearly seen on the postero-anterior and Ziter views. The 5 tuberosity fractures are included in the crack fractures

SECTION 3.3

CLINICALLY SUSPECTED SCAPHOID FRACTURES : THE VALUE OF SECOND WEEK RADIOGRAPHS

There is controversy regarding the management of a clinically suspected scaphoid fracture in which initial radiographs are normal.

Any patient presenting with marked tenderness in the anatomical snuff-box following an injury to the hand and in whom the initial radiographs failed to demonstrate an obvious fracture is usually treated as a possible fracture of the scaphoid. It has been suggested that, in this group of patients, a second set of radiographs of the scaphoid obtained about two weeks later would demonstrate any fracture due to resorption around the fracture line (Bohler et al 1954, Russe 1960).

Leslie & Dickson (1981) suggested that fractures diagnosed on the later radiographs represent incomplete fractures which heal uneventfully. In a retrospective study, Duncan & Thurston (1985) confirmed this and concluded that, in patients presenting in this manner, it is probably inappropriate to immobilise the wrist in

a plaster cast.

During the prospective study of the union of scaphoid fractures, all patients with clinical scaphoid injuries were also reviewed by a single observer (JJD) in a special scaphoid clinic which was held weekly for two years. In clinically suspected scaphoid injuries, difficulty was experienced in deciding whether or not a fracture was present, even on the radiographs obtained after two weeks. In this group of patients, the value of further radiographs obtained two to three weeks after injury in providing reliable and reproducible information on the presence or absence of a fracture of the scaphoid was investigated.

METHOD

A: SELECTION OF RADIOGRAPHS OF CLINICAL SCAPHOID FRACTURES

Eighteen patients were selected at random from sixty nine patients who were seen with clinical scaphoid fractures. They had all sustained an injury to the wrist and had marked tenderness in the anatomical snuffbox. Initial radiographs had either failed to reveal a fracture or the first doctor (usually the orthopaedic senior house officer) had missed a subtle fracture. All these eighteen patients had at least three radiographic

views of the scaphoid obtained at presentation and between two and three weeks later. The initial and 2-3 week radiographs of two patients in whom a scaphoid fracture was missed and who developed a non union were also included. In both cases, the fracture could be seen in retrospect, on the initial and interval radiographs.

There were, therefore, initial and interval radiographs in 20 patients with clinical scaphoid fractures.

B : NORMAL RADIOGRAPHS

As great difficulty was experienced in distinguishing 'lines' in the normal scaphoid from fractures, this was investigated further. Sixty four patients had scaphoid radiographs taken of the opposite (uninjured) wrist. All denied having any pain or previous injury in this wrist. Ten of these radiographs were selected at random and introduced into the previous set of forty radiographs. The twenty observers (described later) were not aware of this and viewed them as representing a clinically suspected scaphoid fracture. Their comments on the state of the scaphoid were recorded.

C : REPRODUCIBILITY

We also assessed reproducibility for each observer. Ten radiographs were selected at random from the previously chosen set of fifty radiographs (A & B above). These radiographs were copied and mixed with the previous set. Thus each observer commented on ten randomly selected radiographs twice.

OBSERVERS

The sixty radiographs were shuffled and presented to twenty observers. There were five registrars, five senior registrars and five senior consultants in Orthopaedic and Accident surgery. In addition, these radiographs were also viewed by five consultant radiologists. Each observer was told that the radiographs were of patients who had fallen and injured their wrist and were very tender in the anatomical snuff-box. They were asked whether, on the radiographs, there was a fracture of the scaphoid and were instructed to disregard any associated injury. There were five possible answers : definitely not fractured, probably not fractured, don't know, probably fractured and definitely fractured.

When they had finished studying the radiographs, the first and interval radiographs of the twenty patients with clinically suspected scaphoid fractures were

immediately presented again as sets. The initial radiograph and those obtained two weeks later for each patient were viewed together and the observer asked to comment on the integrity or otherwise of the scaphoid. This was done to reproduce the clinical situation where both radiographs are usually viewed together.

ANALYSIS

All twenty patients had been followed up for at least one year. The outcome was, therefore, known. Eleven had sustained a fracture of the scaphoid, while in 9 no fracture could be seen on the six and twelve week radiographs. These nine patients were considered not to have sustained a fracture of the scaphoid. After the observers had individually assessed each of the radiographs, their assessment was matched with the actual outcome and was re-categorised as correct or incorrect. For example, if there was no fracture, an assessment of definitely not or probably not was considered to be a correct assessment.

Tables of the percentage of errors were prepared and the significances of differences were calculated using the logistic regression option, CATMOD, in the statistical package - SAS (SAS users guide, 1985). The reproducibility for each observer was measured by

calculating the degree of agreement with his own observations and measuring the kappa value (Cohen 1968, Landis & Koch, 1977).

RESULTS

A: VALUE OF 2-3 WEEK RADIOGRAPHS

The percentage of errors made by each group of observers was comparable to that made by the other groups (Degrees of Freedom (DF) 3, $P=0.83$) for the initial radiographs, 2-3 week radiographs as well as the sets (initial and interval radiographs viewed at the same time). Table 3.3-I also shows that the 2-3 week radiographs did not improve the accuracy of diagnosis of a fracture of the scaphoid. The mean percentage error for all twenty observers for the 2-3 week radiograph was 43%. When both the initial and interval radiographs were viewed together, the mean error remained essentially unchanged ($P=0.56$) at 40 %. Of the two scaphoid fractures which went on to develop a non-union, one (Figure 3.3-1) was considered to be normal in 77 % of the observations while the other was considered normal in 92 percent of the observations.

B: NORMAL RADIOGRAPHS

Table 3.3-II reveals that of the ten normal radiographs almost all were mistaken by some observer as being

fractured. Of the 200 observations, these normal radiographs were thought to show a fracture 39 times. There was no difference between the four groups of observers (DF 3, $\chi^2 = 5.49$, $p = 0.1391$). No single radiograph was more likely to suggest a fracture (Figure 3.3-2a,b) with an analysis of variance for the individual radiographs being insignificant (DF 9, $\chi^2 = 7.49$, $p = 0.5861$).

C: REPRODUCIBILITY

The diagnosis first given on a set of 10 radiographs by each observer was compared to the diagnosis given the second time on the same radiographs and the level of agreement was calculated and expressed in terms of Kappa values. The mean kappa value for each group of observers is listed in table 3.3-III. This table demonstrates that the ability to reproduce observations improved with experience from registrars ($k = 0.299$) to consultants in orthopaedic surgery ($k = 0.528$) although these differences were not statistically significant. The radiologists were best able to reproduce their observations, although the wrong diagnosis was often made.

DISCUSSION

A: CLINICALLY SUSPECTED SCAPHOID FRACTURE

There is controversy about the management of clinically

suspected scaphoid fractures in which initial radiographs do not show an obvious fracture.

Soon after Etienne Destot (1905), one of the first to use radiographs, described scaphoid fractures, it was recognised that lines in a normal scaphoid could be mistaken for a fracture (Lindgren 1949). In order to improve diagnostic accuracy, it has been suggested that one should obtain three (Watson Jones 1934), four (Russe 1960) and as many as 16 radiographic views (Graziani 1940) of the injured scaphoid. Lindgren (1949) was convinced that a definite diagnosis could always be obtained with careful radiographic technique. Others, however, did not share this view and recommended that a clinically suspected scaphoid fracture, in which the initial radiographs failed to reveal a fracture, should be immobilised in a plaster cast and have further radiographic evaluation after an interval of two or three weeks. It was suggested that the decalcification on either side of the fracture line would render any fracture visible on the subsequent radiographs. This is the accepted method of managing such an injury in Great Britain.

Recent studies have cast doubt on the need to immobilise clinically suspected scaphoid injuries. Duncan & Thurston (1985), based on a retrospective study of 108

patients, concluded that the incidence of fractures of the scaphoid in those with normal initial radiology was very low. They suggested that it was inappropriate to treat these patients in a plaster cast. Young et al (1988), in a partially retrospective study, also found that the incidence of subsequently proven scaphoid fractures in this type of a patient was very low but acknowledged that 3% of these fractures may be missed initially by JUNIOR doctors. It has been suggested that the 2 % of scaphoid fractures which become visible on the subsequent radiographic examination (Leslie & Dickson, 1981, Duncan & Thurston, 1985, Young et al 1988) represent incomplete fractures which invariably heal (McLaughlin & Parkes, 1969). All these studies, however, assumed that the initial and interval radiographs provided objective evidence of the presence or otherwise of a scaphoid fracture.

The results of our study suggest that the errors in diagnosis made on the 2-3 week radiographs were comparable to those made on the initial radiographs. The reliability did not improve when the initial and 2-3 week radiographs were viewed together. The seniority and experience of the observer did not improve the ability of the observers to interpret radiographs correctly.

Radiographs cannot be relied upon to provide conclusive

proof that the scaphoid is not fractured. This is especially true in clinical practice with different observers and differences in imaging equipment and techniques. In this study, subtle changes suggesting a complete fracture were missed, even by experienced observers. The initial and 2-3 week radiographs of the two patients in this study, who developed non-union, were misdiagnosed as being normal by over 75% of the observers (Figure 3.3-1).

B: THE NORMAL SCAPHOID

Alternatively, the diagnosis of a fracture, too, may be incorrect. As Lindgren (1949) observed, lines in the normal scaphoid can be mistaken for fractures. The presence of 'lines' within a scaphoid do not, therefore, invariably represent a fracture. Abnormalities of surrounding soft tissues (scaphoid fat stripe & dorsal wrist swelling), too, are not diagnostic of a fracture (Section 3.1). The only unequivocal radiographic signs of a scaphoid fracture are, in our opinion, (1) a clear lucent line across the scaphoid, (2) a distinct break in continuity of the cortex and (3) a distinct sharp step in the cortex.

Finally, this study has also shown that most observers were unable to reproduce their observations satisfactorily.

Radiographs, therefore, appear to be of little value in the early management of clinically suspected scaphoid injuries. The management of these injuries must depend entirely upon a careful clinical examination. Every attempt must be made to arrive at a precise diagnosis. The scaphoid tubercle, lunate and radial styloid must be carefully palpated and observed on radiographs to pick up injuries to these regions. Traumatic tenosynovitis (DaCruz et al 1986) and traumatic scapho-lunate instability (Linscheid et al, 1972) as a cause of radial wrist pain and tenderness must be considered.

C: RECOMMENDATION REGARDING EARLY MANAGEMENT

If the diagnosis is still in doubt, the management must, in my opinion, be based entirely on clinical assessment. Such an assessment can be difficult and usually depends on the experience of the treating surgeon. However, if the patient (1) has some swelling in the anatomical snuff box of the wrist, (2) is distinctly tender in the anatomical snuff-box and (3) stressing the scaphoid (Watson et al, 1986) is very painful, the patient must be treated in a plaster cast or other splint to restrict wrist movement. If the clinical examination two weeks later finds persistence of marked tenderness in this region especially on stressing the scaphoid, the wrist must continue to be immobilised for a further period

even if repeat radiographs fail to reveal a fracture. I agree with Young et al (1988) that, at around six weeks if no fracture is seen on radiographs, it is probably safe to discontinue immobilisation.

CONCLUSION

This study suggests that initial and 2-3 week radiographs of a clinical scaphoid injury do not provide reliable or reproducible evidence of a scaphoid fracture and cannot be relied on either to detect or to rule out a scaphoid fracture. Normal radiographs can be mistakenly interpreted as representing a fracture. These radiographs cannot, therefore, form the sole basis of a decision about management.

TABLE 3.3-I : Value of interval radiographs in the diagnosis of scaphoid fractures : Percentage errors

GROUP	Initial	2-3 week	Sets	Mean
Registrars	37	43	37	39
Senior Registrars	43	42	39	49
Consultants	42	43	39	41
Radiologists	42	43	43	43
Mean	41	43	40	41

Each group had five observers. The Analysis of variance for Groups : DF 3, $\chi^2=0.86$, $p=0.83$; for observers : DF 19, $\chi^2=31.3$, $p=0.04$; for radiographs : DF 19, $\chi^2=297.7$, $p=0.0001$.

TABLE 3.3-II : Interpretation of normal radiographs

A : GROUP	Not #ed	#ed
Registrars	36	14
Senior Registrars	38	12
Consultants	43	7
Radiologists	44	6

DF 3 : $x=5.49$: $p= 0.1391$

B: Radiograph	Not #ed	#ed	20 obs
1	16	4	
2	16	4	
3	15	5	
4	15	5	
5	20	0	
6	15	5	
7	17	3	
8	12	8	
9	17	3	
10	18	2	

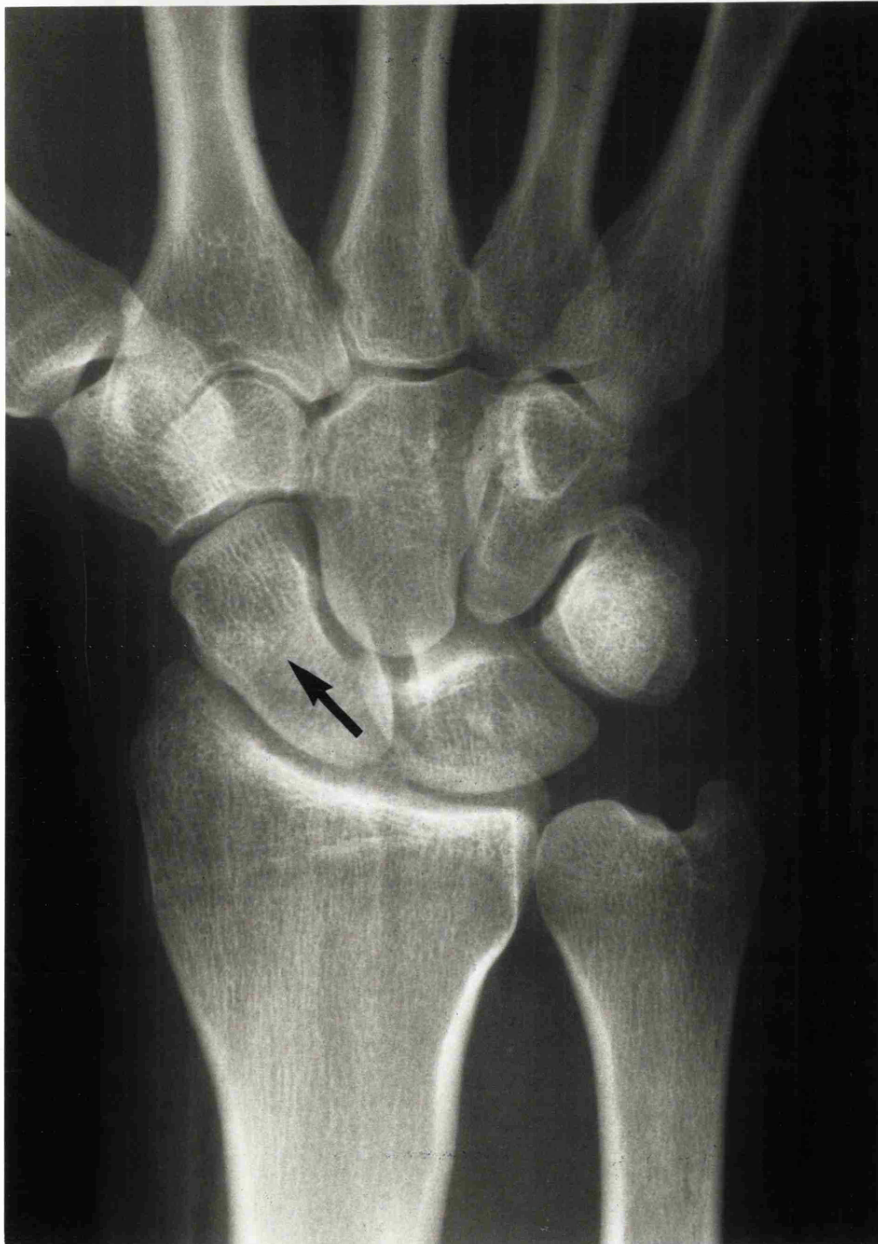DF 9 , $x =7.49$, $p= 0.5861$

TABLE 3.3-III : Reproducibility - intra-observer agreement

GROUP	RIGHT TWICE	WRONG TWICE	CHANGED MIND	k =	SE
Registrar	27	8	15	0.299	0.143
Senior Registrar	29	9	12	0.429	0.139
Consultant	26	13	11	0.528	0.124
Radiologist	34	12	4	0.802	0.094
	116	42	42	0.513	0.065

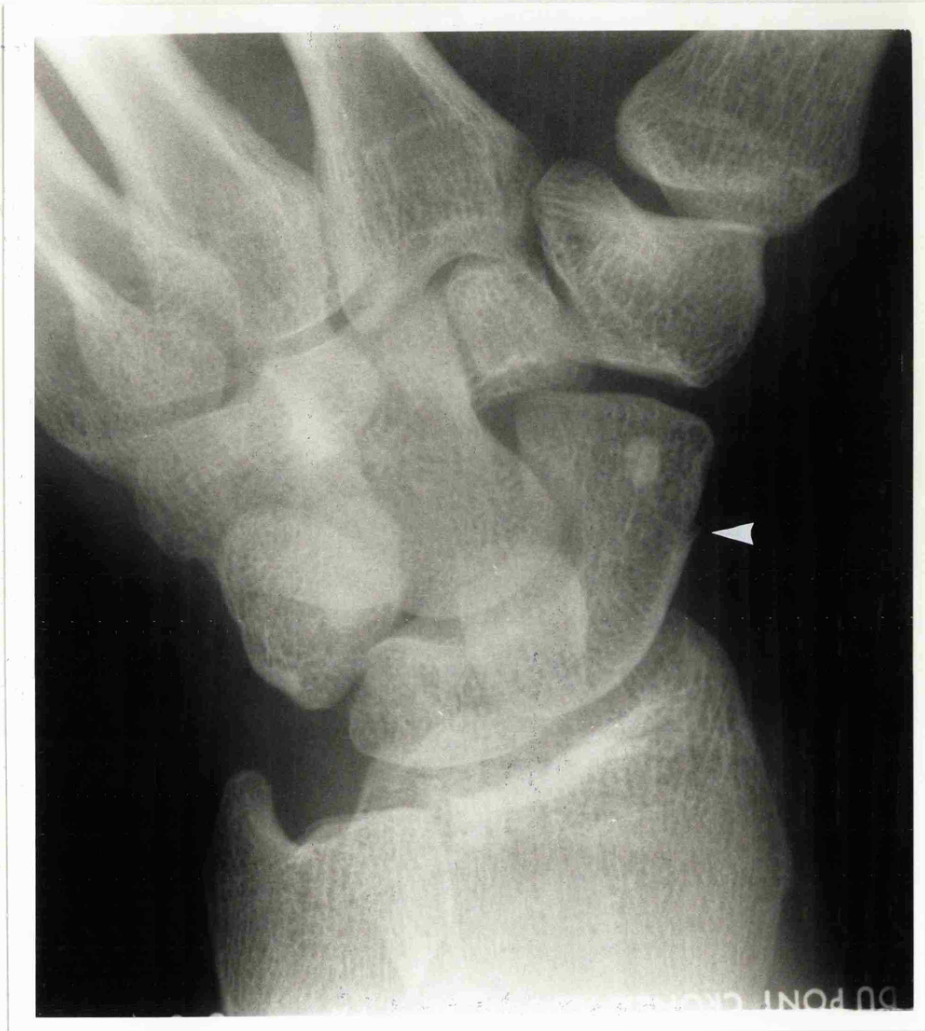k = kappa which can vary from -1 (complete disagreement), through 0 (chance agreement) to +1 (complete agreement) - after Landis & Koch, 1977. SE= standard error. Each of the four groups consisted of five observers.

FIGURE 3.3-1 : 2nd week radiograph of a scaphoid fracture which developed a non-union



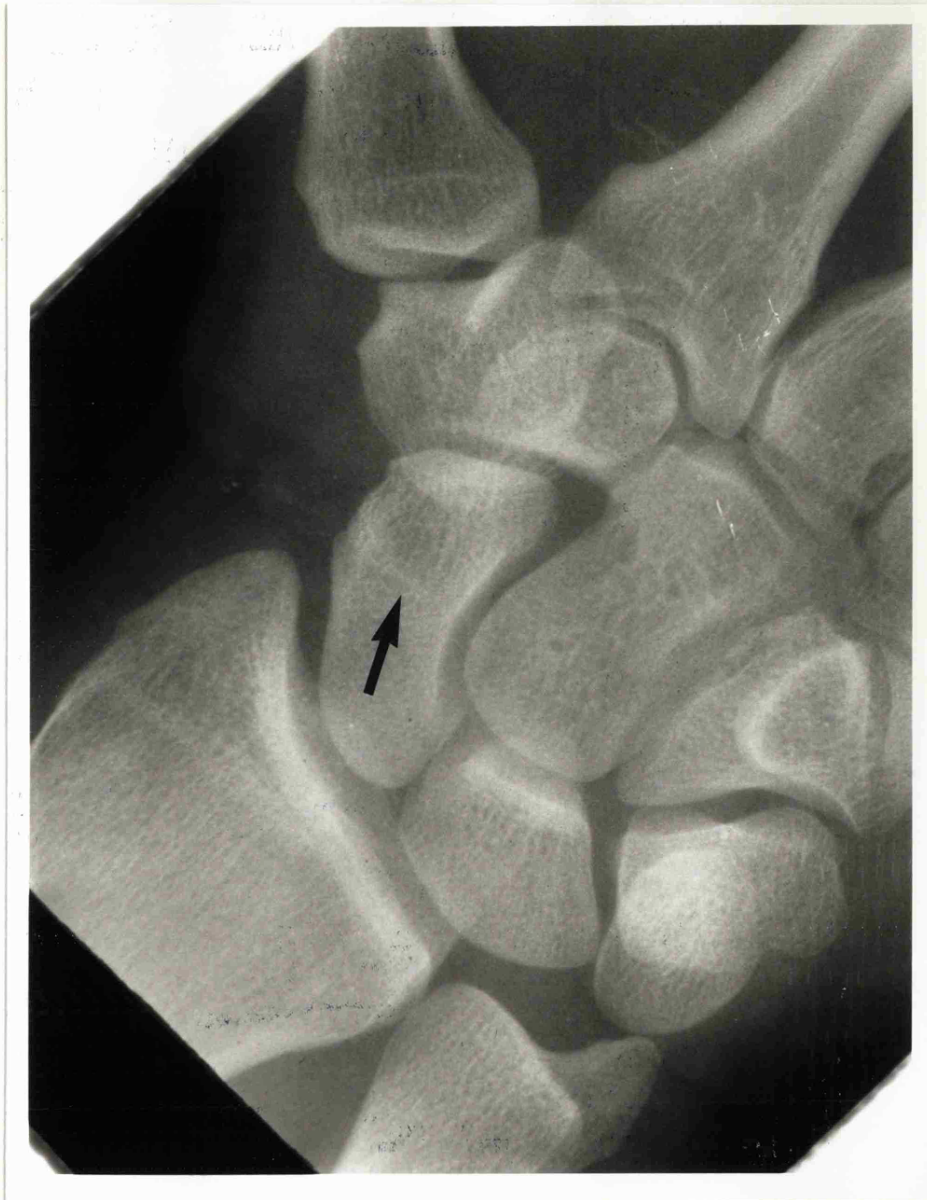
This is a radiograph of a scaphoid obtained 2 weeks after injury which went on to develop a non-union. In retrospect a fracture line is just visible. In sixty observations (initial radiograph -20, 2-3 week radiograph- 20 and sets-20) this was considered not fractured in 77%.

FIGURE 3.3-2b : Normal scaphoid radiograph



Normal radiographs (b) this normal ridge was misinterpreted as a fracture by 5 observers.

FIGURE 3.3-2a : Normal scaphoid radiograph



Normal radiographs (a) this line was considered to represent a fracture by 8 of 20 observers.

SECTION 3.4

COLLES' vs SCAPHOID CAST IN THE TREATMENT OF SCAPHOID FRACTURES

Standard treatment of the scaphoid waist fracture consists of immobilisation of the wrist in a below elbow plaster cast with the thumb included up to the interphalangeal joint - the traditional scaphoid plaster. This is said to result in union within twelve weeks in around 95 % (Leslie & Dickson 1981). Such protracted treatment makes this injury of considerable social and economic inconvenience to its victims who are predominantly young men (Leslie & Dickson 1981).

Despite its wide acceptance the use of the scaphoid plaster is not universal. A simple dorsal slab with the thumb left free was considered adequate by Bohler et al (1954). Russe (1960) included the thumb metacarpal only to achieve 97% union by twelve weeks. Others have considered inclusion of the thumb to be essential (Soto-Hall 1945, Stewart 1954). Thumb immobilisation is thus of unproven benefit and may be a positive disadvantage. It also makes the cast more difficult to apply and slightly more expensive.

The effect of thumb immobilisation on the outcome in scaphoid fractures was studied in a prospective randomised trial.

PATIENTS

All patients presenting with a fresh scaphoid fracture within one week of injury to the Leicester Royal Infirmary from November 1985 to December 1987 were included in the study. Any patient in whom the fracture was not visible to the doctor starting treatment but in whom there were strong clinical grounds for suspecting the fracture had their injured wrist immobilised in a Colles' cast and were seen in the Scaphoid clinic after two weeks for repeat radiographic and clinical assessment. Those in whom a fracture was subsequently identified (n=3) were included in the study group.

One hundred and eighty five patients were included in the study. There were 146 males and 39 females. Their mean age was 30 years (range 11 to 81 years).

METHOD

A: RANDOM ALLOCATION

All patients were randomised into two groups by drawing a number from a previously prepared set. Patients allocated an even number were treated in a scaphoid cast

while those allocated an odd number were treated in a Colles' cast.

The scaphoid cast was a below elbow cast which included the thumb in a position of function up to the inter-phalangeal joint. The Colles ' cast was a below elbow cast which did not include the thumb or the thumb metacarpal. In both casts the wrist was in a functional position (slight dorsiflexion) and care was taken to ensure that the movement of the metacarpo-phalangeal joints of the fingers was not restricted by the cast.

All patients were encouraged to use their hand as much as possible while in the cast but were instructed to avoid any activity which caused wrist discomfort.

B: CLINICAL ASSESSMENT

All patients were reviewed at 1, 2, 4, 8, 12, 16 and 26 weeks after injury in a special clinic organised for the purposes of this study. At each visit the condition of the plaster was noted and the degree of discomfort documented as none, mild, moderate or severe. Any restriction in the following everyday activities was noted : dressing, washing, using the knife and fork, writing, putting on socks or stockings. Their answers were categorised into three groups : (1) unable to perform that particular activity [score = 1], (2) able

to perform but with difficulty [score = 1.5] and (3) able to perform without any difficulty [score = 2]. The sum of these scores was expressed as a percentage of the maximum possible score which was 10 if the dominant hand was involved and 8 if the non-dominant hand was injured.

At eight weeks all casts were removed and the wrist assessed clinically and radiographically. Any patient in whom there was some tenderness in the anatomical snuff box and whose radiographs cast any doubt regarding union were further immobilised in a similar cast up to 12 weeks. At twelve weeks all casts were removed.

From eight weeks tenderness in the anatomical snuff box to deep pressure in comparison to the opposite uninjured side was assessed. Any restriction in daily activities was assessed as before. The range of wrist movement (dorsiflexion, palmarflexion, radial and ulnar deviation) was measured using a goniometer and the sum of the four measurements was expressed as a percentage of the contralateral wrist movements. Grip strength and thumb opposition was assessed clinically in comparison to the uninjured side. The strength and opposition was expressed as being essentially equal to the opposite side, appreciably less or markedly less than the opposite side. Such a broad categorisation was used in order to overcome the obvious limitations of a clinical

assessment. The span was measured in centimeters and expressed as a difference from the opposite side. No adjustment was made for non-dominance.

C: RADIOGRAPHIC ASSESSMENT

Radiographs were obtained at the initial presentation, 8,12,16 and 26 weeks. If the initial radiographs failed to demonstrate an obvious fracture radiographs were repeated out of the cast at two weeks. Five views were obtained - the postero-anterior, lateral, semi-prone, semi-supine and the Ziter (1973) view (with the hand in semi-pronation, slight flexion and maximum ulnar deviation). These radiographs were reviewed and the fracture classified according to Bohler et al (1954) and Herbert & Fisher (1984). From the eighth week onwards the healing was documented as definitely united if the fracture line was no longer visible, probably united if the site of the fracture could be easily identified and ununited if a clear gap was present at the fracture line (Maudsley and Chen, 1972).

The data was analysed using the Statistical Package for Social Sciences (SPSS- X) program , University of Leicester.

RESULTS

A scaphoid cast was used in 90 patients while 95 had a

Colles plaster. The two groups were comparable for age, sex, side of injury and dominance, and duration of immobilisation (Table 3.4-I). In addition they were comparable for type of fracture (Figure 3.4-1, 3.4-2) and mechanism of injury (Figure 3.4-3) ,

At six months after injury the fracture had united in 60 patients who were treated in a scaphoid cast, the fracture site could be easily identified in 18 although the fracture had probably united, while in 11 the fracture had clearly failed to unite. The fracture had definitely united in 69 of the patients treated in a Colles' cast, 17 had probable union while the fracture was ununited in 9. The state of union of the fracture was similar in the two groups (Figure 3.4-4).

Figure 3.4-5 a & b demonstrates the % restriction of activities while immobilised in the cast and in the subsequent four months. Those treated in a Colles' plaster cast were less restricted in their activities initially although there was no significant difference after the 4th week.

The recovery of wrist movement and span was similar in the two groups (Figure 3.4-6 a & b). However patients treated in a scaphoid cast had greater restriction of both grip strength and opposition in the initial period

after cast immobilisation (Figure 3.4-7 a & b).

The condition of the cast during the period of immobilisation, pain experienced while in the cast, tenderness in the anatomical snuff box after cast removal are represented in Figures 3.4-8, 3.4-9 and 3.4-10. There was no difference between the two groups.

DISCUSSION

Despite its wide acceptance the use of the scaphoid plaster is not universal. A simple dorsal slab with the thumb left free was considered adequate by Bohler et al (1954). On reviewing 580 of 734 cases accumulated over a 28 year period, a 96.5% union rate had been achieved and it was commented that in 35 who had the thumb included the non-union rate was even higher.

Others have considered inclusion of the thumb to be essential. Soto-Hall (1945) used a forearm cast with the wrist in extension and radial deviation and the thumb widely abducted to eliminate the effect of the abductor pollicis brevis which has part of its' origin from the tuberosity of the scaphoid. A 95 % union rate was achieved in four to five months by this method.

Stewart (1954) also included the thumb but considered

position unimportant. He achieved a 95% union in a mixed series of fresh and old fractures immobilised for up to a year. Russe (1960) included the thumb metacarpal only to achieve 97% union by twelve weeks.

The present study suggests that scaphoid fractures treated in a cast which does not immobilise the thumb heal as well as those treated in the conventional scaphoid cast. While there is no essential difference in the stiffness, tenderness or functional outcome in the two groups studied, patients treated in the Colles' cast had better function while in the cast than those treated in the scaphoid cast.

CONCLUSION

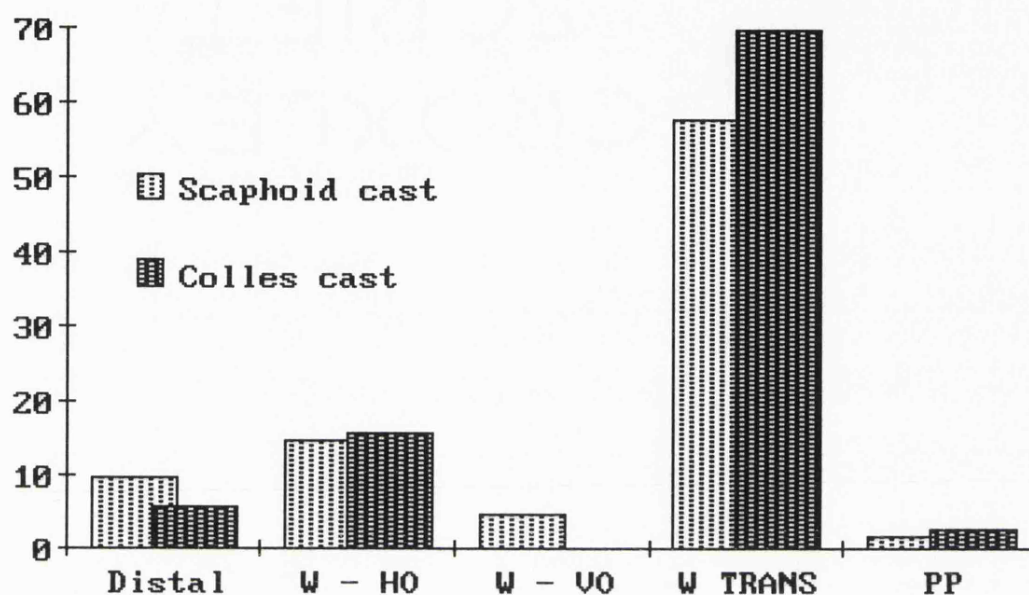
Thumb immobilisation does not appear to influence the outcome with regard to fracture union and may be a positive disadvantage in that it makes the cast more difficult to apply and slightly more expensive.

Table 3.4-I : Comparison of the two groups

	Scaphoid cast	Colles Cast	p=
Age	30.31 (17.5)	29.75 (15.1)	0.8
sex	M/F 76/14	M/F 70/25	0.1
side injured	R/L 45/45	R/L 42/53	0.5
Time in cast	9.6 wks (2.0)	9.0 wks (2.1)	0.1

For age and time in cast the figures refer to mean values with the standard deviation in brackets. p = probability

FIGURE 3.4-1 : Bohler (1954) type of fracture



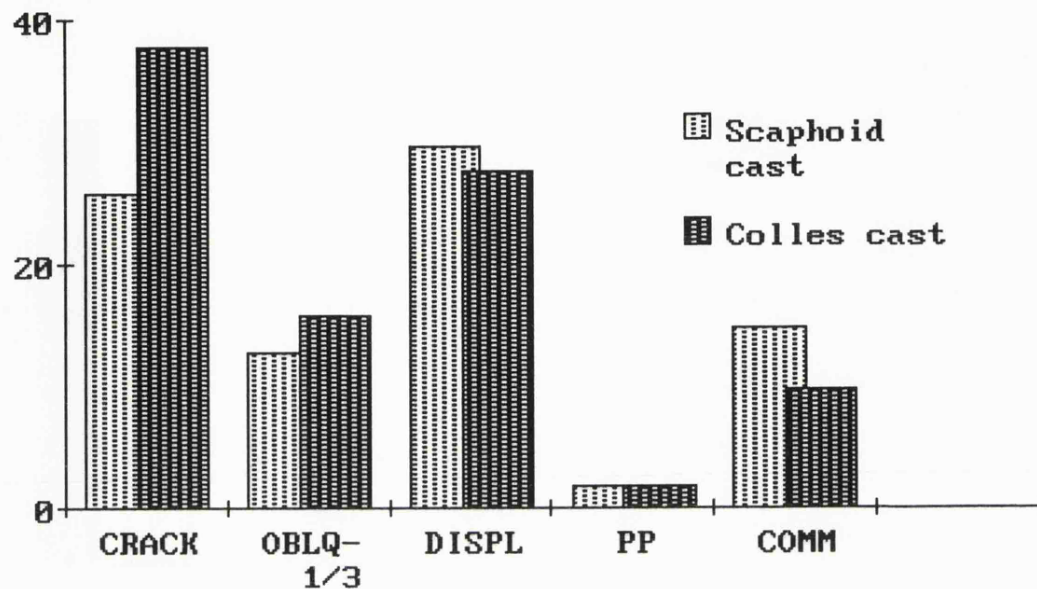
DATA TABLE 3.4-1 :

	Distal	W-HO	W-VO	W-Trans	PP
Scaphoid cast	10	15	5	58	2
Colles' cast	6	16	0	70	3

$$\chi^2 = 7.23, p = 0.124$$

Distal - distal pole fractures, W-HO - horizontal oblique fracture, W-VO - vertical oblique fracture, W-Trans - Transverse waist fracture, PP - proximal pole fracture.

FIGURE 3.4-2 : Herbert & Fisher (1984) Type of fracture



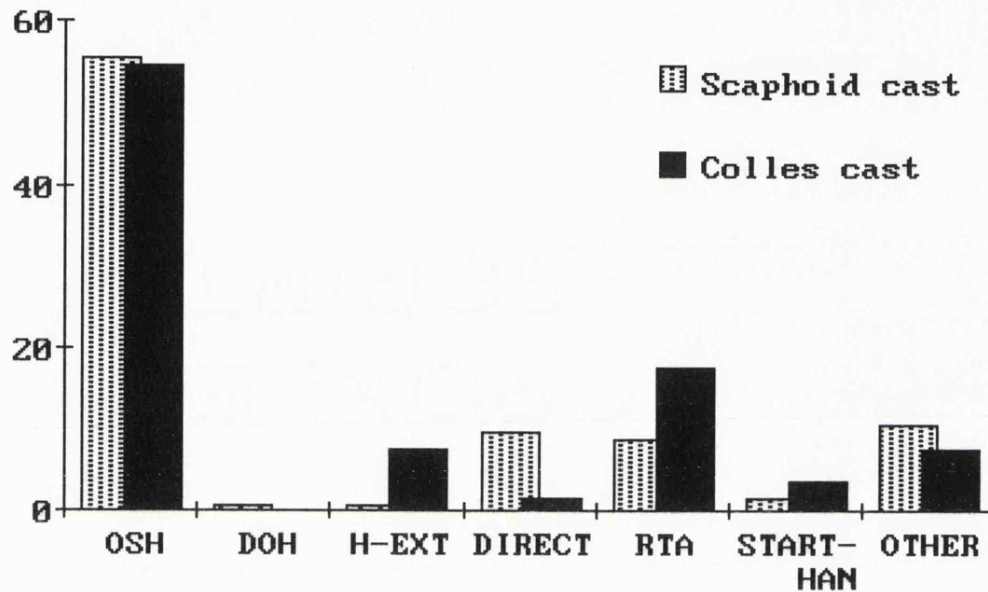
DATA TABLE 3.4-2 :

	CRACK	OBLQ-1/3	DISPL	PP	COMM
Scaphoid fracture	26	17	30	2	15
Colles' cast	38	17	28	2	10

$$\chi^2 = 5.30, p = 0.381$$

CRACK - undisplaced crack fracture, OBLQ-1/3 - oblique fracture of the distal third, DISPL - displaced fracture : (1) gap greater than 1 mm, (2) step greater than 1mm, (3) scapho-lunate angle different from opposite side by 15 degrees, PP - proximal pole fracture, COMM - comminuted fracture but without displacement. χ^2 - chi square, p - probability.

FIGURE 3.4-3 : Mecahnism of injury



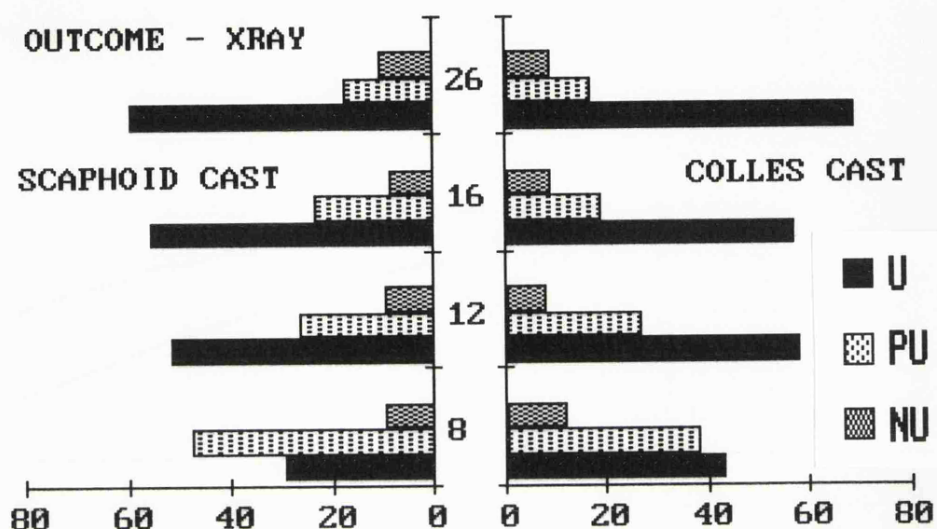
DATA TABLE 3.4-3 : Mechanism of injury

	OSH	DOH	H-EXT	DIRECT	RTA	START-HAN	OTHER
Scaphoid cast	56	1	1	10	9	2	11
Colles' cast	55	0	8	2	18	4	8

$$\chi^2 = 16.7, p = 0.020$$

OSH - fall on the outstretched hand, DOH - fall on the dorsum of the hand, H-EXT - hyperextension injury, RTA - Road traffic accident, START-HAN - injury sustained while using a starting handle.

FIGURE 3.4-4 : Outcome at six months

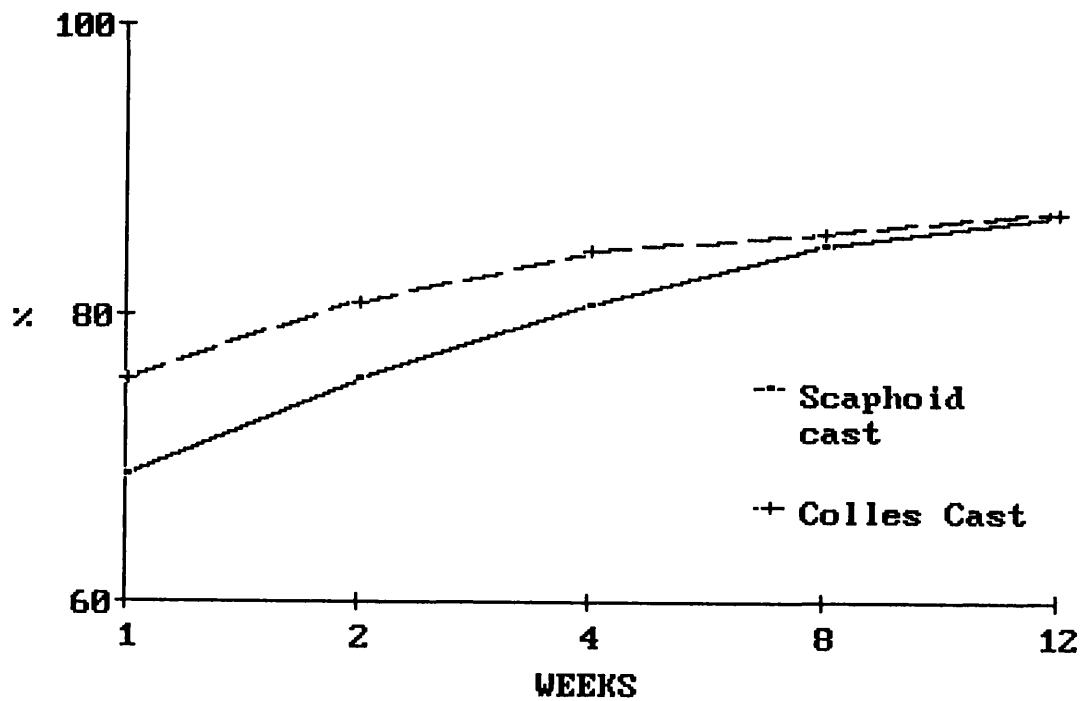


DATA TABLE 3.4-4 : State of fracture union

Week	Scaphoid cast			Colles' cast			χ^2	p =
	U	PU	NU	U	PU	NU		
8	(88) 30	48	10	(93) 43	38	12	3.52	0.683
12	(89) 52	27	10	(93) 58	27	8	0.46	0.794
16	(89) 56	24	9	(85) 57	19	9	0.50	0.779
24	(89) 60	18	11	(95) 69	17	9	0.66	0.718

U - united, PU - probably united, NU - not united. Chi square analysis was carried out (χ^2 - chi square, p - probability). () - number of patients with adequate data

FIGURE 3.4-5a : Activity in the plaster cast



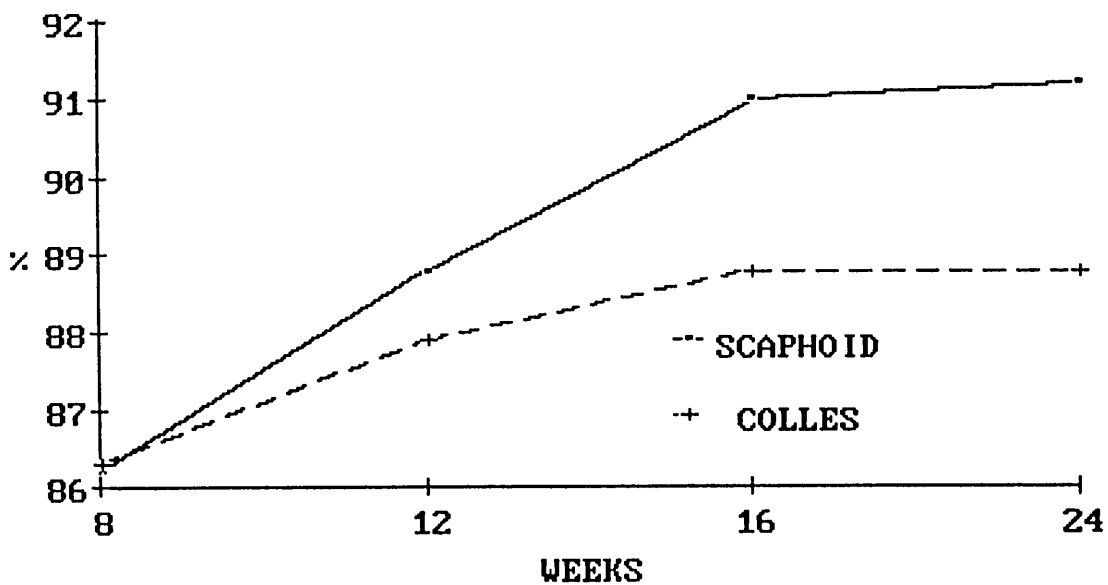
DATA TABLE 3.4-5a : Activity in the cast

Week	Scaphoid cast			Colles'cast			p =
	(SD)	(SE)		(SD)	(SE)		
1	68.9	13.1	1.2	75.5	13.1	1.5	0.002
2	75.5	13.0	1.4	80.9	11.9	1.3	0.005
4	80.7	12.6	1.3	84.5	11.3	1.2	0.039
8	84.9	12.2	1.3	85.7	10.7	1.1	0.614
12	87.1	12.1	2.1	83.2	10.9	2.3	0.218

SD : standard deviation, SE : standard error.

The activity is represented as the percentage of expected level of activity. The details are given in the Methods section of this study.

FIGURE 3.4-5b : Activity after cast removal



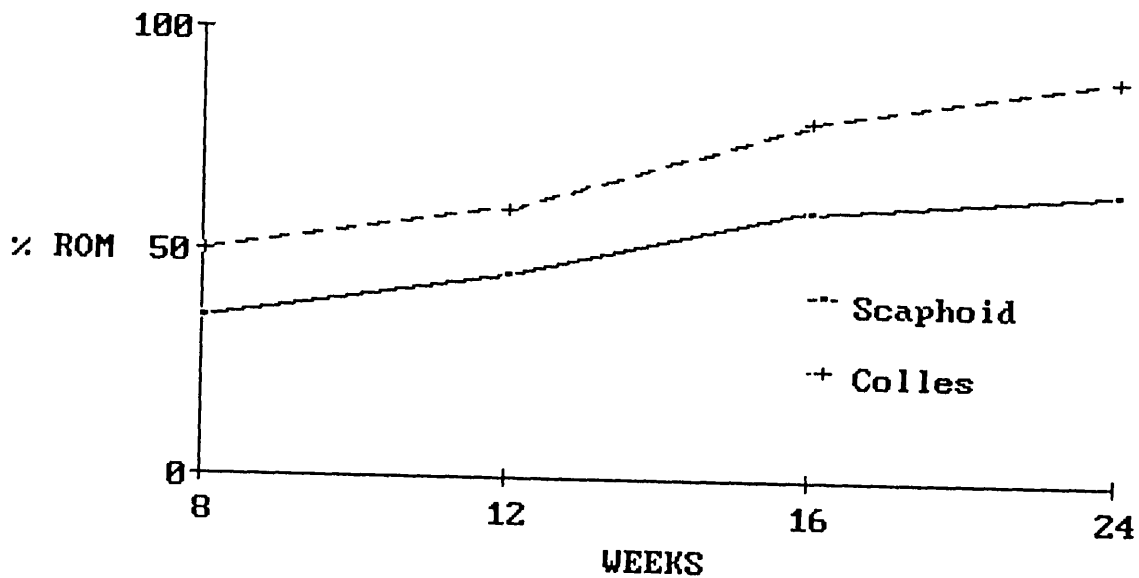
DATA TABLE 3.4-5b : Activity after cast removal

Week	Scaphoid cast			Colles' cast			p =
	(SD)	(SE)		(SD)	(SE)		
8	86.2	11.8	1.2	86.3	10.7	1.1	0.992
12	88.8	11.3	1.2	87.9	10.4	1.1	0.569
16	91.0	10.0	1.1	88.8	10.0	1.1	0.140
24	91.2	10.0	1.1	88.8	9.9	1.0	0.104

SD : standard deviation, SE : standard error.

The activity is represented as the percentage of expected level of activity. The details are given in the Methods section of this study.

FIGURE 3.4-6a : Recovery of movement

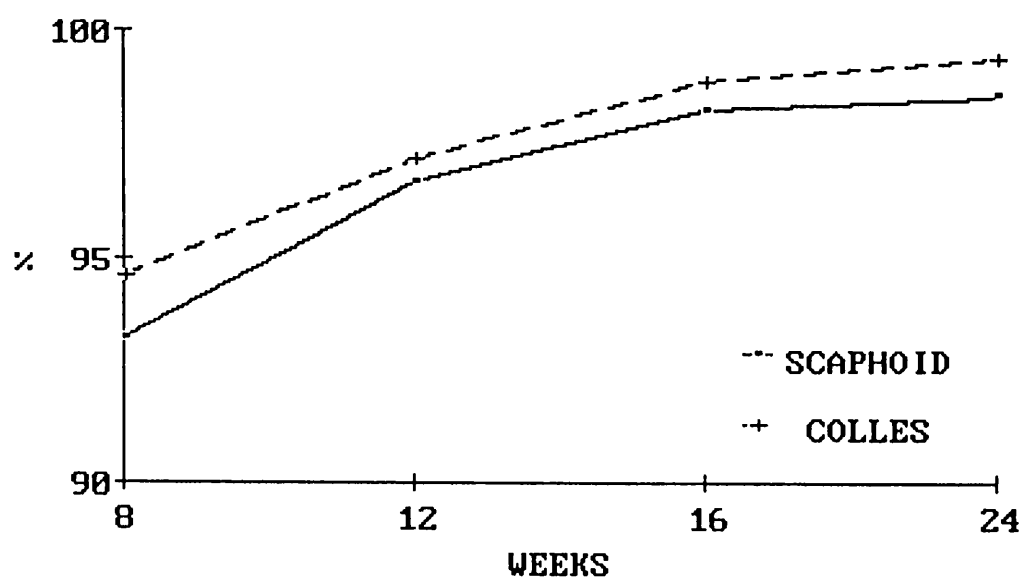


DATA TABLE 3.4-6a : Recovery of wrist movement

Week	Scaphoid cast			Colles' cast			p =
	(SD)	(SE)		(SD)	(SE)		
8	59.3	18.7	2.0	61.6	17.1	1.8	0.393
12	75.1	20.6	2.2	77.1	21.2	2.2	0.532
16	86.4	13.9	1.5	89.5	13.3	1.4	0.133
24	88.9	12.9	1.4	92.9	9.7	1.0	0.018

SD : standard deviation, SE: standard error
 Wrist movement (sum of dorsiflexion, palmarflexion, radial and ulnar deviation) is expressed as a percentage of the opposite side.

FIGURE 3.4-6b : Recovery of span



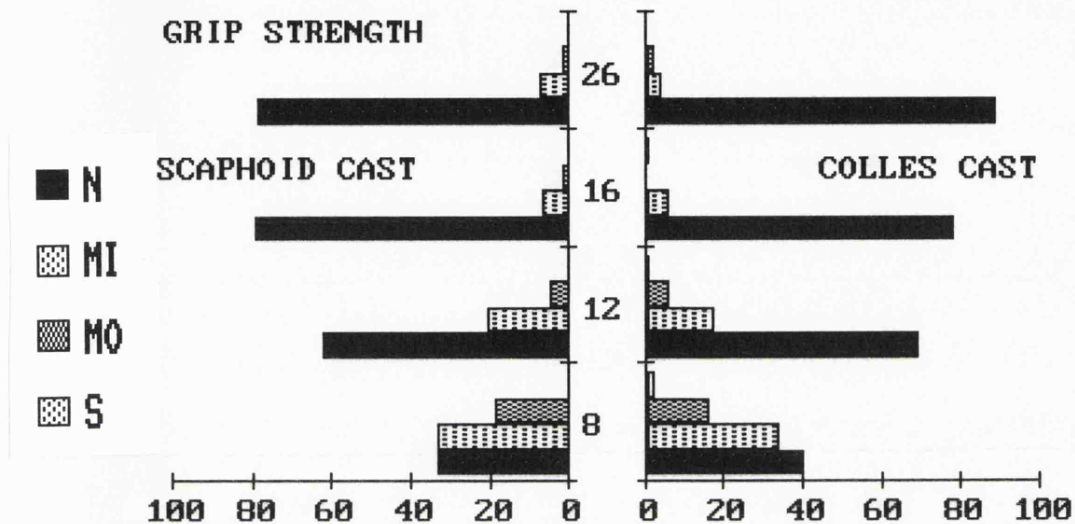
DATA TABLE 3.4-6b : Recovery of span

Week	Scaphoid cast			Colles' cast			p =
	(SD)	(SE)		(SD)	(SE)		
8	93.2	5.2	0.6	94.6	5.1	0.5	0.062
12	96.7	4.4	0.5	97.2	4.0	0.4	0.445
16	98.3	3.2	0.3	98.9	2.7	0.3	0.149
24	98.6	3.0	0.3	99.4	2.5	0.3	0.055

SD : standard deviation, SE: standard error

The span is expressed as a percentage of that on the opposite side.

FIGURE 3.4-7a : Recovery of Grip strength

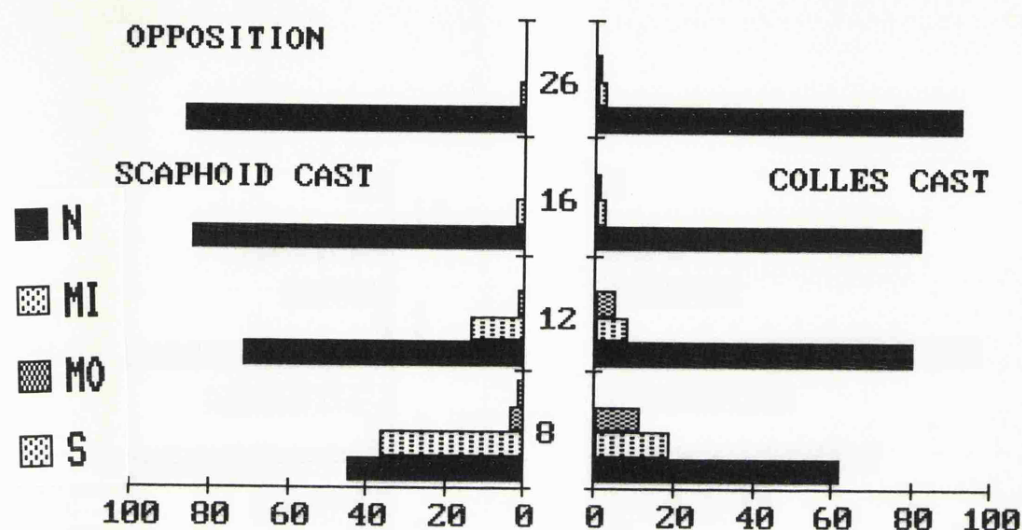


DATA TABLE 3.4-7a : Recovery of grip strength

Week	Scaphoid cast				Colles' cast				χ^2	p =
	N	Mi	Mo	S	N	Mi	Mo	S		
8	(88) 34	34	19	1	(92) 40	34	16	2	0.90	0.804
12	(89) 63	21	5	0	(93) 69	17	6	1	1.70	0.638
16	(89) 80	7	2	0	(85) 78	6	0	1	3.02	0.390
24	(89) 79	8	2	0	(95) 89	4	2	0	1.73	0.420

N - no restriction, Mi - mild restriction, Mo - moderate restriction, S - severe restriction. χ^2 - chi square, p - probability. () - number of patients with adequate data

FIGURE 3.4-7b : Recovery of opposition

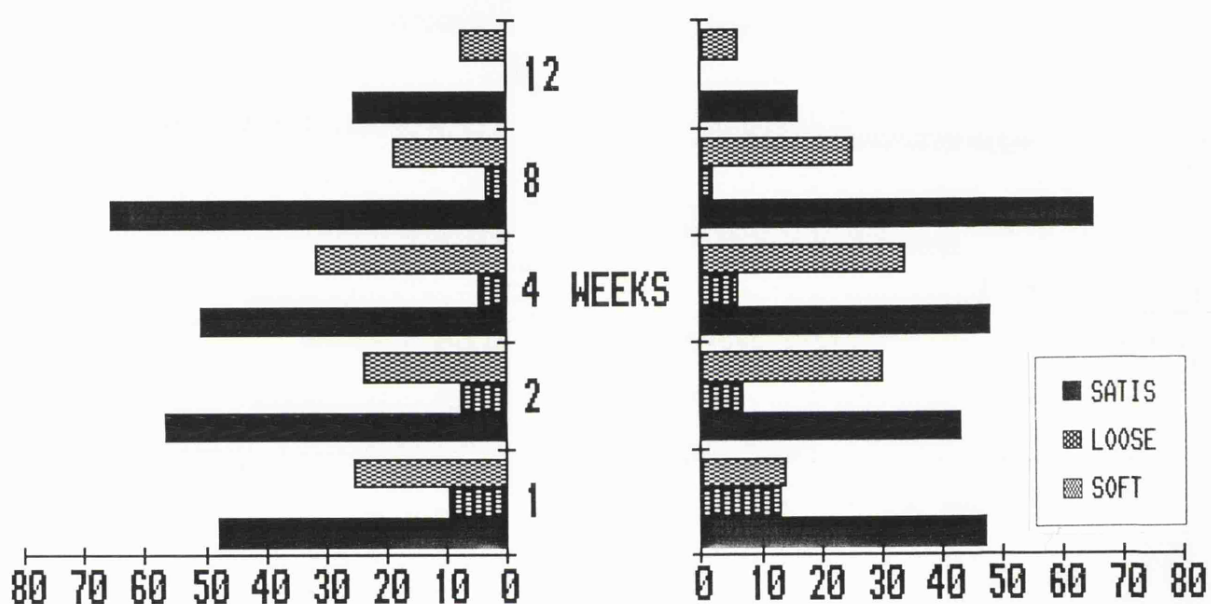


DATA TABLE 3.4-7b : Recovery of opposition

Week	Scaphoid cast				Colles' cast				χ^2	p =
	N	Mi	Mo	S	N	Mi	Mo	S		
8	(88) 45	37	4	2	(92) 62	19	11	0	13.67	0.003
12	(88) 72	14	2	0	(93) 80	8	5	0	3.21	0.201
16	(88) 85	3	0	0	(85) 82	2	1	0	1.20	0.548
24	(89) 87	2	0	0	(95) 92	2	1	0	0.95	0.623

N - no restriction, Mi - mild restriction, Mo - moderate restriction, S - severe restriction. χ^2 - chi square, p - probability. () - number of patients with adequate data

FIGURE 3.4-8 : Condition of the cast

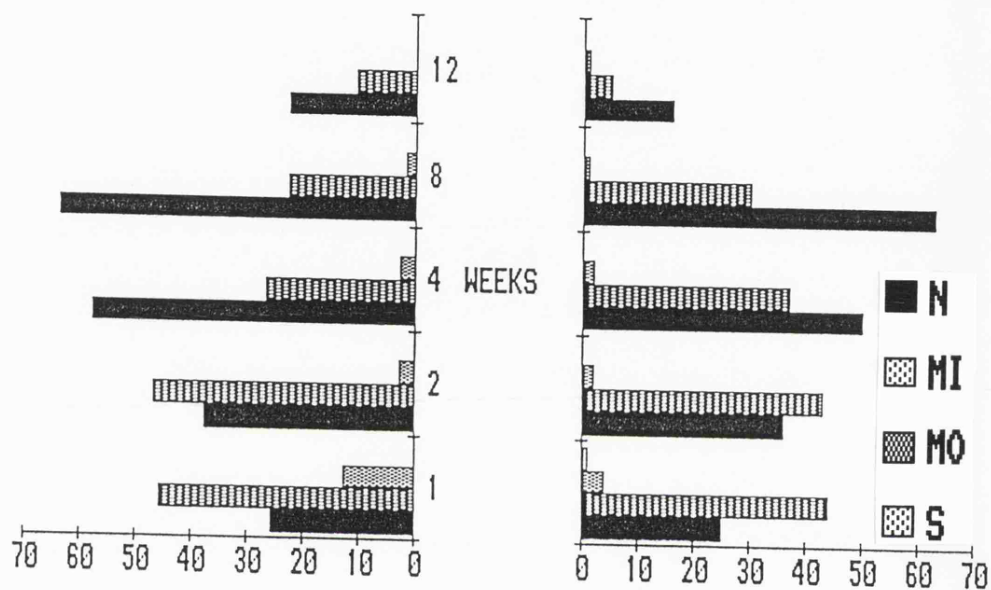


DATA TABLE 3.4-8 : Condition of the cast

Week	Scaphoid cast			Colles' cast			χ^2	p =
	Sat	Lo	Soft	Sat	Lo	Soft		
1	(84) 48	10	26	(74) 47	13	14	3.89	0.273
2	(89) 57	8	24	(80) 43	7	30	3.03	0.387
4	(88) 51	5	32	(88) 48	6	34	0.24	0.970
8	(89) 66	4	19	(92) 65	2	25	3.01	0.390
12	(34) 26	0	8	(22) 16	0	6	0.10	0.752

Sat - satisfactory cast, Lo - loose cast, Soft - any softening of the cast, especially of the palmar band which allowed wrist movement - patients' impression).
 χ^2 - chi square, p - probability. () - number of patients with adequate data

FIGURE 3.4-9 : Discomfort in the cast

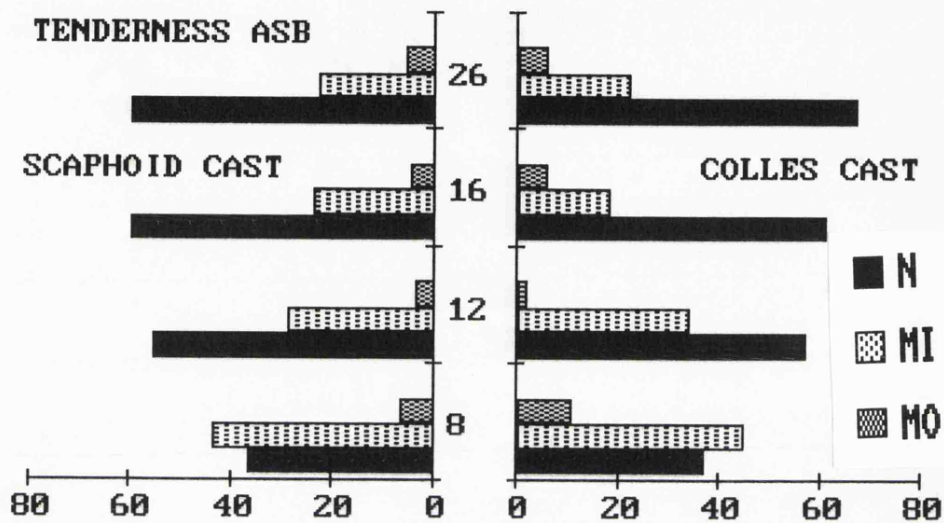


DATA TABLE 3.4-9 : Discomfort while in a cast

Week	Scaphoid cast				Colles' cast				χ^2	p =
	N	Mi	Mo	S	N	Mi	Mo	S		
1	(85) 26	46	13	0	(74) 25	44	4	1	5.09	0.165
2	(88) 38	47	3	0	(81) 36	43	2	0	0.14	0.931
4	(88) 58	27	3	0	(89) 50	37	2	0	2.35	0.309
8	(89) 64	23	2	0	(94) 63	30	1	0	1.13	0.568
12	(34) 23	11	0	0	(22) 16	5	1	0	2.02	0.363

N - no discomfort, Mi - mild discomfort, Mo - moderate discomfort, S - severe discomfort. χ^2 - chi square, p - probability. () - number of patients with adequate data

FIGURE 3.4-10 : Tenderness in the anatomical snuff box



DATA TABLE 3.4-10 : Tenderness in the anatomical snuff box

Week	Scaphoid cast			Colles' cast			χ^2	p =
	none	mild	moderate	none	mild	moderate		
8	(88) 37	44	7	(93) 37	45	11	0.76	0.683
12	(89) 56	29	4	(93) 57	34	2	0.99	0.611
16	(89) 60	24	5	(85) 61	18	6	0.87	0.649
24	(89) 60	23	6	(95) 67	22	6	0.21	0.899

Chi square analysis was carried out (χ^2 - chi square, p - probability). () - number of patients with adequate data

SECTION 3.5

**RADIOGRAPHIC SIGNS OF UNION OF SCAPHOID FRACTURES : AN
ANALYSIS OF INTER-OBSERVER AGREEMENT AND REPRODUCIBILITY**

Fractures of the waist of the scaphoid are usually treated in plaster for 6 to 12 weeks. The decision to start mobilising the wrist is made at that time and is based on the absence of "significant" tenderness in the anatomical snuff box (London 1961) and on radiographic "evidence" of union.

The presence of trabeculae crossing the fracture or sclerosis at the site are thought to reflect fracture healing, and these two signs are the only objective assessments of union in most published studies (Russe 1960, Leslie and Dickson 1981). Radiographs of the scaphoid at 12 weeks, however, can be difficult to interpret (Herbert and Fisher 1984). Trabeculae may appear to cross the fracture line if the radiographic beam is not exactly in the plane of the fracture, and sclerosis of the fracture line may appear as a single line or as a double line, perhaps produced by overlap of images (Lindgren 1949).

These factors question the value of radiographs in providing a reliable and objective indication of union of scaphoid fractures around 12 weeks after injury. This study was, therefore, designed to determine the reliability of the radiographic diagnosis of union of such fractures by testing the degree of inter-observer agreement.

METHOD

A: SELECTION OF RADIOGRAPHS

Of 212 sets of radiographs of fractures of the waist of the scaphoid taken at about 12 weeks after injury, 20 of good quality were selected at random. Each set included at least four views (Russe 1960): postero-anterior, lateral, semi-pronated and semi-supinated.

B: OBSERVERS & METHOD

Eight observers were tested: four orthopaedic consultants and four consultants in radiology. Each was presented with the 20 sets of radiographs, labelled A to T and each was asked to answer four questions for each set; these, and the five possible answers, are listed in Table 3.5-I.

Two months later the 20 sets of radiographs were

relabelled from 1 to 20 and presented to the same eight observers, who had no prior knowledge that they would be asked to review the films again.

C: ANALYSIS

Data was then analysed and expressed in terms of inter-observer agreement in pairs. Calculation was by weighted kappa statistics (Landis and Koch 1977) so that the degree of disagreement was taken into account and allowance was made for chance agreement. Weighted kappa values can vary from -1.0 (complete disagreement) through 0 (chance agreement) to +1.0 (complete agreement).

RESULTS

One example of a single view from a set of radiographs taken 12 weeks after injury is shown in Figure 1; this produced considerable disagreement, with the spread of opinions shown in Table 3.5-I. For all 20 sets of radiographs, the degree of agreement between each pair of observers was calculated. An example is given in Table 3.5-II; this demonstrates the level of agreement between one observer and each of the remaining seven observers. The weighted average inter-observer agreement, k , was calculated on the basis of a similar analysis for each of the other observers.

A: AGREEMENT BETWEEN OBSERVERS

This inter-observer agreement was calculated for each question. On whether there were trabeculae crossing the fracture line, k was 0.104, for sclerosis at the fracture line it was 0.371 while for proximal scaphoid avascularity it was 0.214. As regards fracture union, the inter-observer agreement was 0.386 (Table 3.5-III). Even when the five possible answers were regrouped as (1) definitely or probably yes, (2) don't know and (3) definitely or probably not there was no improvement in inter-observer agreement (Table 3.5-III).

B: REPRODUCIBILITY

The degree of agreement between the opinions of each observer at his first and at his subsequent reviews of the same set of radiographs is presented in Table 3.5-IV. The ability of the eight observers to reproduce their own opinion regarding trabeculae crossing the fracture line ($k=0.297$), sclerosis at the fracture line ($k=0.576$) and proximal scaphoid avascularity ($k=0.414$) was too poor for the use of these signs to assess bony union. The reproducibility as regards to union of the fracture was better ($k=0.705$), though as mentioned above inter-observer agreement for this was poor ($k=0.386$).

DISCUSSION

Russe (1960) suggested that fractures of the scaphoid should be immobilised until radiographs demonstrated definite signs of union, which included the presence of bony trabeculae bridging the defect and increased density at the site of, or on each side of, the fracture line. These signs have been used as an objective method of assessing union in many reports (Stewart 1954; Leslie and Dickson 1981).

A: AGREEMENT & REPRODUCIBILITY

This study has shown that even 12 weeks after injury there was very poor agreement between observers on these factors and therefore on union of the fracture, with an unacceptably low degree of reproducibility. The poor levels of agreement were surprising, since the 20 sets of radiographs had been chosen to reflect clinical practice and were all of good quality; a situation better than that in a busy fracture clinic. Radiographs obtained 12 weeks after injury, cannot, therefore, be reliably and reproducibly used to assess union of a scaphoid fracture.

B: CLINICAL IMPLICATIONS

The clinical implications of this unreliability have a medicolegal significance. London (1961) recognised the difficulty of interpreting radiographs and suggested

that more emphasis be placed on careful examination of the injured wrist. In our opinion the decision to discontinue immobilisation after 8 to 12 weeks should be based on the absence of marked tenderness in the scaphoid region and absence of a clear radiographic gap at the fracture line. However, as the interpretation of radiographs is so unreliable, continued follow-up for a further three to six months is advised. Patients such as motor mechanics who make heavy use of the hand and wrist should perhaps be provided with a removable wrist splint for a period after removal of the plaster cast.

Our results also cast doubt on the conclusions drawn from previous studies which have been based on radiographic evaluation of union at or before 12 weeks (Table 3.5-V). Most of the studies which include large numbers of cases suggest that 95% of fresh scaphoid fractures will unite uneventfully. By contrast, several recent reports (Cooney, Dobyns and Linscheid 1980a,b; Herbert and Fisher 1984) have suggested that the incidence of non-union is 25% to 50% and some authors (Mulder 1968; Cooney et al. 1980a,b) have been able to collect large numbers of patients with established pseudarthroses. The exact incidence of non-union of scaphoid fractures defined as the presence of a clear gap at the fracture line on radiographs taken one year after injury (Maudsley and Chen 1972), is unknown.

CONCLUSION

Radiographs obtained 12 weeks after injury cannot be used reliably and reproducibly to assess union of a fractured scaphoid. Radiographic criteria should not be used as an objective assessment of union in clinical studies.

Table 3.5-I. Opinions given at eight initial and eight subsequent reviews of the scaphoid fracture shown in Figure 3.5-1

	Definitely yes	Probably yes	Don't know	Probably not	Definitely not
Has the fracture united?	4	3	0	9	0
Are there trabeculae crossing the fracture line?	4	1	1	6	4
Is there sclerosis at the fracture line?	11	2	0	1	2
Is there avascularity of the proximal part ?	6	3	0	3	4

Table 3.5-II. The weighted kappa values * for agreement between Observer 1 and each of the other seven observers

Observer	Union	Trabeculae crossing	Sclerosis	Avascular necrosis.
2	0.173	0.091	0.457	0.320
3	0.322	-0.057	0.597	0.196
4	0.528	0.528	0.583	0.066
5	0.226	0.142	0.543	0.318
6	0.113	0.370	0.183	0.091
7	0.479	0.077	0.338	0.455
8	0.239	0.204	0.556	0.000

* weighted kappa statistics show (-1) for complete disagreement, (0) for chance agreement and (+1) for complete agreement (Landis and Koch 1977). Each observer was paired with the others in the same way.

Table 3.5-III. Average agreement between observers on radiographic signs of scaphoid fractures at 12 weeks, assessed by five original possible replies and by combining "definitely" and "probably" to give three possible replies (see text)

	Five replies	Three replies
Has the fracture united	0.386	0.387
Are there trabeculae crossing the fracture line?	0.104	0.175
Is there sclerosis at the fracture line?	0.371	0.395
Is there avascularity of the proximal part?	0.214	0.028

* weighted kappa statistics show (-1) for complete disagreement, (0) for chance agreement and (+1) for complete agreement (Landis and Koch 1977). Each observer was paired with the others in the same way.

Table 3.5-IV. Reproducibility by each observer of his opinion* on radiographic signs of union of scaphoid fractures.

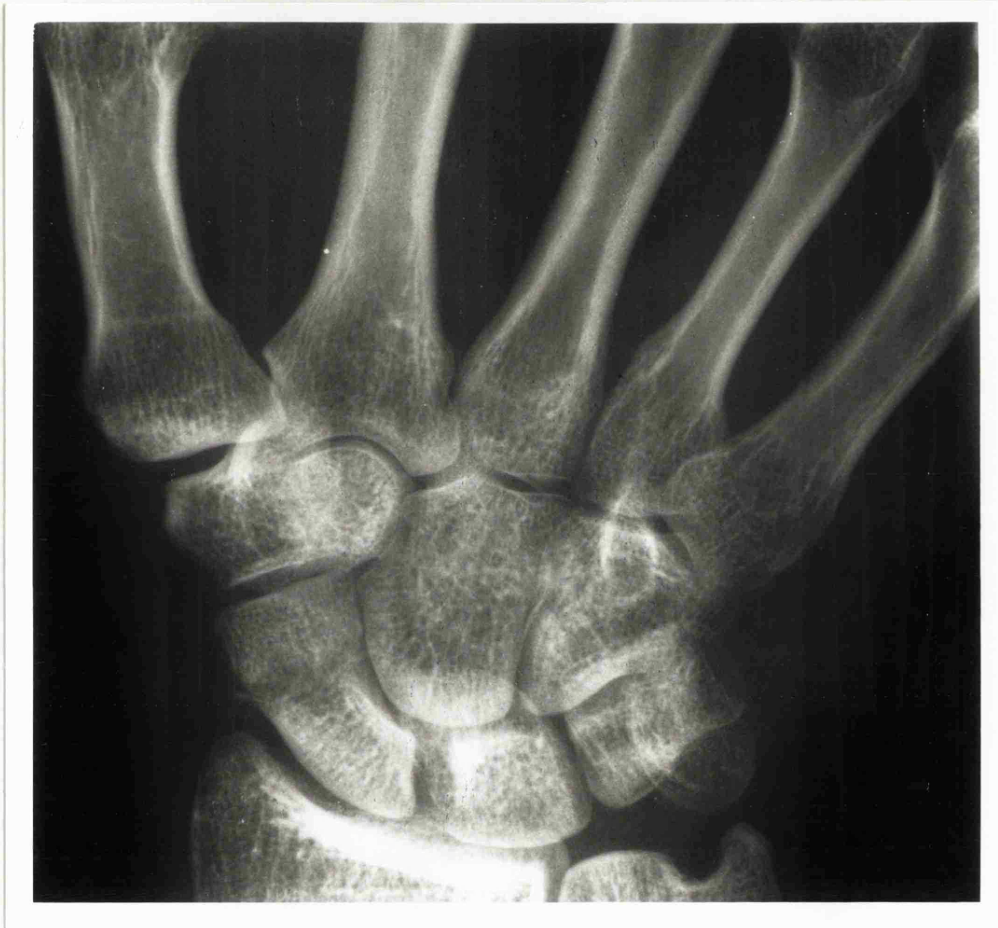Observer	Union	crossing	Trabeculae		A
			Sclerosis	necrosis.	
1	0.926	0.477	0.531	0.322	
2	0.579	0.654	0.627	0.653	
3	0.550	-0.061	0.677	0.367	
4	0.679	0.603	0.558	0.167	
5	0.847	0.845	0.490	0.462	
6	0.257	0.267	0.115	0.000	
7	0.556	0.470	0.357	0.563	
8	0.525	0.525	0.761	0.000	
<hr/>					
Weighted average 0.705		0.297	0.576	0.414	

Weighted kappa statistics show (-1) for complete disagreement, (0) for chance agreement and (+1) for complete agreement (Landis and Koch 1977). Each observer was paired with the others in the same way. * The level of agreement between the initial opinion and that given two months later was calculated for each observer. The weighted average for all eight observers is also given

Table 3.5-V. The results from large retrospective series of fresh scaphoid fractures

Author	Number of fractures	Time of radiograph (weeks)	Non-union (per cent)
Stewart 1954	320	8 to 12	5
Russe 1960	220	6 to 12	3
London 1961	227	8 to 12	5
Leslie & Dickson 1981	222	6 to 8	5

FIGURE 3.5-1 : Agreement on union ?



Postero-anterior view of a fracture of the scaphoid taken 12 weeks after injury. Conflicting opinions of this radiograph are given in DATA TABLE 3.5-1.

SECTION 3.6

SCAPHOID WAIST FRACTURES : PATTERNS OF UNION

The reported incidence of non-union following scaphoid fractures varies from 5% (Russe 1960, Linscheid et al 1972, Leslie and Dickson 1981) to as high as 25% (Cooney et al 1980) or 50 % (Herbert and Fisher 1984). There are two possible reasons for this wide variation. In most studies the diagnosis of union was based on radiographs obtained at or less than twelve weeks after injury. The reliability of such radiographic evidence has been questioned (Section 3.5). Secondly, non-union has not been clearly defined.

A non-union may be considered to exist when, given adequate time, the fracture has not united and is unlikely to unite without intervention. Regarding the scaphoid, Maudsley and Chen (1972) used the term 'non-union' when a clear gap was present at the fracture line one year after injury.

Eighty two consecutive scaphoid waist fractures over one year after injury were studied to document the incidence of non-union and to determine disability one year after

such a fracture.

PATIENTS

One hundred and twenty nine patients were treated as scaphoid fractures at the Leicester Royal Infirmary over a one year period (1st January to 31st December, 1985). In 12 patients no fracture could be demonstrated in the initial films and at review. Thirty patients had sustained a fracture of the tuberosity. The remaining 85 patients had sustained a definite fracture of the waist of the scaphoid : 82 of these were reviewed and form the basis of this report.

The mean age of these 82 patients was 30.6 years (SD 15.6, range 11 to 76 years). Sixty four were male and eighteen were female. Seventy one fractures were transverse, eight were horizontal oblique while one was vertical oblique. Two fractures involved the proximal pole. The right hand was injured in 44 patients of whom 34 were right handed; the left hand was injured in 38 patients of whom 32 were right handed.

All 82 patients had been treated in a below elbow plaster cast which included the thumb in a position of opposition with the wrist in slight dorsiflexion. The plaster cast was retained for a mean of 8.5 weeks (SD 3.2 weeks, range 3 to 22 weeks). The decision to

discontinue plaster cast immobilisation was made by the treating orthopaedic surgeon and appeared to be based on the absence of 'significant' tenderness in the scaphoid region and on the radiographic impression of 'fracture union'.

METHODS

A: CLINICAL ASSESSMENT

The 82 patients were reviewed at a mean of 2.1 years (range 1.7 to 2.6 years). At review the patients were asked about pain and stiffness. The site, severity, aggravating and relieving factors were recorded. Any effect of these symptoms on their occupation and leisure activities was documented. The scaphoid region was carefully palpated for local tenderness; the site and severity being recorded. The scaphoid was stressed as described by Watson et al (1986) and the severity of discomfort noted as mild, moderate or severe. The range of dorsiflexion, palmarflexion, radial and ulnar deviation at the wrist was measured using a goniometer and the span was measured in centimeters. Similar measurements on the opposite uninvolved side were done for comparison. Grip strength was assessed clinically by comparing the injured and contralateral side simultaneously (as in section 3.4).

B: RADIOGRAPHIC ASSESSMENT

Radiographs of both wrists were then taken. Five views of the scaphoid were obtained. These included the postero-anterior, lateral, semi-supine and semi-prone radiographs as recommended by Russe (1960). The fifth view was that recommended by Ziter (1973) with the wrist in slight flexion and maximum ulnar deviation.

The radiographs were carefully reviewed. The initial radiographs provided information of the type of the fracture which was classified according to Bohler (1954). The presence of pre-existing degenerative change or carpal instability was also noted.

The state of fracture union was determined on radiographs obtained at review. The fracture was considered to have united if the scaphoid looked normal and the site of the fracture could not be easily recognised. The fracture was considered to be ununited if a clear gap (Figure 3.6-1) existed at the fracture line (Maudsley and Chen 1972). If the fracture site was easily recognised or if there was any doubt about the state of union the fracture was listed as being 'probably' united (Figure 3.6-2).

In addition to noting the state of union, the presence and severity of osteoarthritis in the radio-carpal and

inter-carpal joints was documented (Mack et al 1984; Ruby et al 1985). Any carpal instability, as defined by Linscheid et al (1972) was noted.

The data was analysed using the SPSS X version 2.2 program, University of Leicester, 1987.

RESULTS

A: SCAPHOID FRACTURE UNION

The fracture had definitely united in 52 of the 82 patients (63%). In 20 patients (24.7%) the fracture had 'probably' united. Thus 72 (87.7%) patients had definite or 'probable' union of a fracture of the waist of the scaphoid. In 10 patients (12.3%) a clear gap was visible at the fracture line.

B: CLINICAL FEATURES OF THE THREE GROUPS

The patients with a non-union were as young as those in whom the fracture had united. In both these groups the patients were predominantly male. Patients with a probable union were much older (Table 3.6-I) and the male to female ratio was lower than in the other two groups. Patients in all three groups had spent a considerable time in plaster.

Neither pain in the radial aspect of the wrist nor stiffness in the wrist assisted in predicting a

non-union (Table 3.6-II). Of the 33 patients who said they had some pain and discomfort in the anatomical snuff box only 9 had an ununited fracture. Although the symptom of pain was not specific for non-unions, as 9 of the 10 non-unions had pain, this symptom is quite sensitive. Only 3 patients in the entire series had to change their jobs because of the fracture and only one had a non-union.

Local tenderness on deep pressure, too, did not always indicate a non-union (Table 3.6-III). However, half the patients with a probable union and non-union had local tenderness. Discomfort on stressing the scaphoid (after Watson et al 1986) also, was not specific for non-union. The grip strength did not appear to be appreciably affected by non-union. Six patients with a probable union, however, had appreciable weakness of grip strength.

The only parameter which demonstrated a significant difference was the range of wrist movement. The sum of dorsiflexion, palmarflexion, radial and ulnar deviation was expressed as a percentage of opposite wrist movement (Dias et al 1987). This indicated the percentage of wrist movement and took individual variation into account. Table 3.6-IV demonstrates that the range of wrist movement in patients in whom the fracture was

definitely or 'probably' united was essentially equal to that of the opposite side. However, in patients with a non-union the range of movement was significantly reduced. Of the 11 patients with significant ($> 25\%$) loss of wrist movement, 5 had ununited scaphoid fractures.

C: RADIOGRAPHIC RESULTS

Evaluation of the follow-up radiographs demonstrated early degenerative change in 6 of the 52 patients in whom the fracture had united, while one third of those with probable union had such changes. Five of the 10 patients with a non-union had radiological changes suggesting secondary osteoarthritis. Similarly, patients with a non-union were more likely ($\chi^2 = 17.80$, $p = 0.0001$) to have dorsal intercalated segment instability (Table 3.6-V).

DISCUSSION

A: SCAPHOID FRACTURE UNION

Using the precise definition of non-union as the presence of a clear gap at the fracture site over one year after injury, the present study suggests that the incidence of non-union of the scaphoid fracture is 12.3%. This is much higher than commonly expected (Russe 1960; Leslie and Dickson 1981) but not as high as that observed by Cooney et al (1980) and suggested by Herbert

and Fisher (1984).

The radiological outcome over one year after injury appears to separate the patients into three distinct clinical groups.

B: UNITED FRACTURES

Patients with an united fracture were in their twenties with a male preponderance (M:F 4:1). Only 9 of the 52 patients had any symptoms and, without exception, these were mild. 25% had local tenderness but this was of moderate severity in only 3 patients. 20% had discomfort on the scaphoid stress test (Watson et al 1986) but the range of wrist movement, span and grip strength was essentially normal. None of these patients had to change their occupation.

C: NONUNION

Patients with a non-union were also in their twenties with a marked male preponderance (M:F 9:1). Almost all were symptomatic at review. Objectively, 50% had local tenderness which was usually of moderate severity, and 4 patients had discomfort on the scaphoid stress test. Although grip strength was essentially normal the restriction of wrist movement (and diminished span) clearly distinguished these patients from those in the other two groups. 50% of these patients had degenerative

changes (Mack et al 1984, Ruby et al 1985) and carpal instability (Fisk 1970, Monsivais et al 1986) at review. Interestingly only one patient had to change his occupation because of the fracture.

D: PROBABLE UNION

An unexpected finding was the distinct clinical profile in 25% of the patients with fractures of the scaphoid waist in whom the site of the fracture could be easily identified on radiographs over one year after injury. These did not correspond to the 'delayed union' group described by Maudsley and Chen (1972) in that the fracture had probably united. These patients were much older (mean 39 years) and there were proportionately more females (M:F 2:1) than in the united and ununited groups. In spite of the fracture having probably united, 75% of these patients had symptoms and over half had local tenderness. One third had appreciable weakness of grip strength but wrist movement was essentially normal. A third of these patients had recognisable degenerative changes around the scaphoid and two had to change their occupation because of the fracture.

CONCLUSION

This study suggests that the incidence of non-union (as described by Maudsley and Chen 1972) was 12.3% and most of these patients were symptomatic and had restriction

of wrist movement. A further 25% of patients, in whom the fracture site could be easily identified over one year after injury, continued to have symptoms and weakness but did not have restriction of wrist movement.

Table 3.6-I. Age and duration of immobilisation versus outcome

	Age in years (SD)	Sex M : F	Weeks in plaster (SD)
Definitely united (n = 52)	27.9 (13.7)	41:11	8.0 (2.3)
Probably united (n = 20)	38.8 (19.8)	14: 6	9.8 (4.3)
Not united (n = 10)	26.0 (9.5)	9: 1	9.3 (4.2)
p =	0.018	NS	NS

p= significance on analysis of variance. SD standard deviation

Table 3.6-II. Symptoms versus outcome

	Pain	Stiffness	Change in occupation	Change in leisure
Definitely united (n = 52)	9	5	0	3
Probably united (n = 20)	15	3	2	1
Not united (n = 10)	9	2	1	0
$\chi^2 =$	14.46			
p =	0.0007	NS	NS	NS

χ^2 = chi square , p = significance of differences.

Table 3.6-III. Objective evaluation versus outcome

	Tenderness	Stress test	Grip strength
Definitely united (n = 52)	13	10	1
Probably united (n = 20)	12	6	6
Not united (n = 10)	5	4	1
$\chi^2 =$	8.16		13.20
p =	0.016	NS	0.039

χ^2 = chi square , p = significance of differences.

Table 3.6-IV. Wrist movement versus outcome

A:	% wrist movement (SD)	Span (SD)
Definitely united (n = 52)	94.1 (11.2)	1mm (4mms)
Probably united (n = 20)	90.1 (11.6)	7mms (11mms)
Not united (n = 10)	67.9 (23.5)	12mms (20mms)
p =	< 0.0001	= 0.0019
B:	< 25%	> 25%
Definitely united (n = 52)	48	4
Probably united (n = 20)	18	2
Not united (n = 10)	5	5
χ^2 =	14.74	
p =	0.0006	

The sum of the dorsiflexion, palmarflexion, radial deviation and ulnar deviation of the involved side was expressed as the percentage of the range of movement of the opposite normal wrist. Span was expressed as the difference from the contralateral side.

χ^2 = chi square , p = significance of differences.

Table 3.6-V. Radiographic evaluation versus outcome

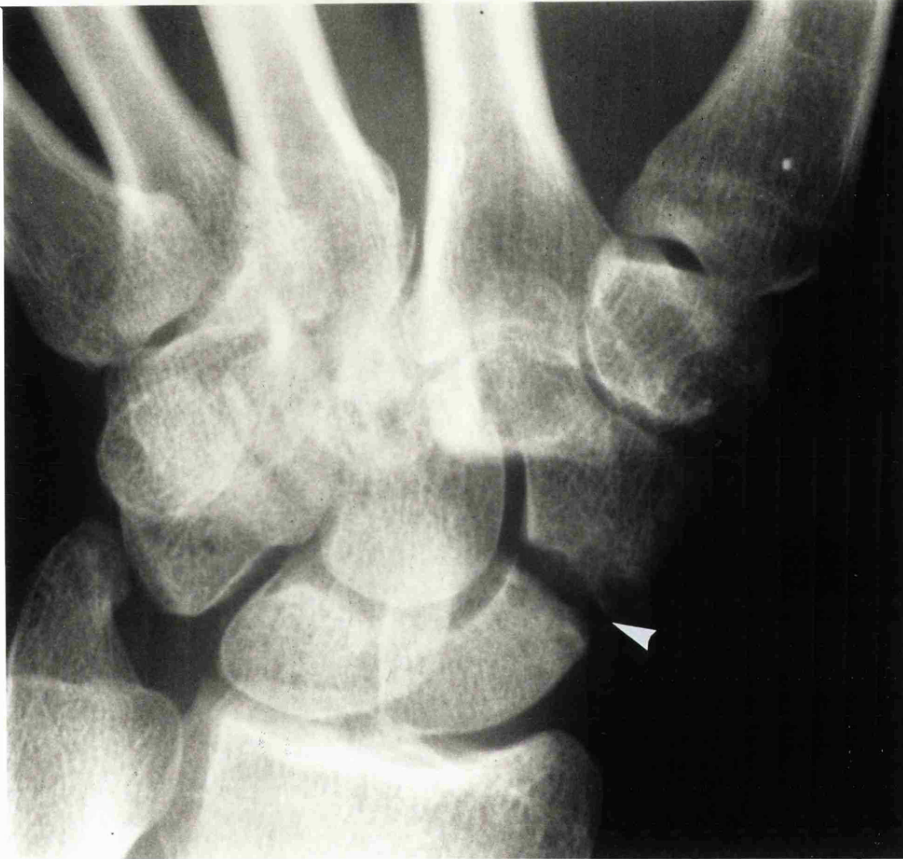	Osteoarthritis	DISI
Definitely united (n = 52)	6	1
Probably united (n = 20)	7	2
Not united (n = 10)	5	5
$\chi^2 =$	32.48	21.68
p =	0.0034	< 0.0001

Osteoarthritis in the radio-scaphoid, scapho-lunate or scapho-capitate joint.

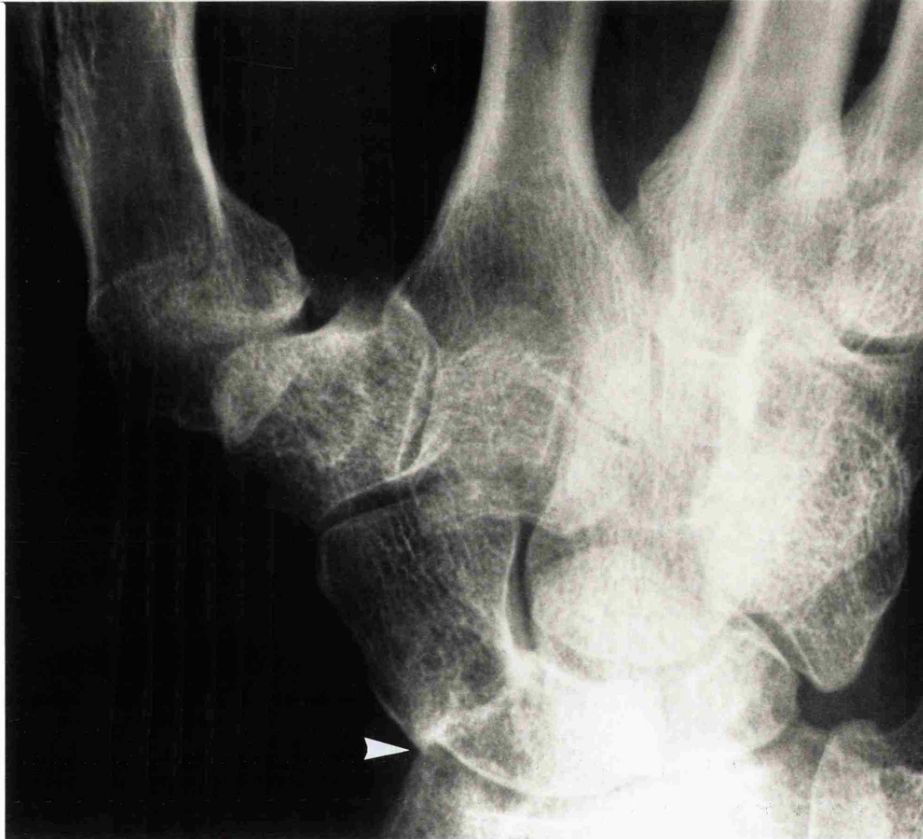
DISI : Dorsal intercalated segment instability : change in capito-lunate angle of > 15 degrees when compared to the opposite side.

χ^2 = chi square, p = significance of differences.

FIGURE 3.6-1 : Ununited scaphoid fracture



Radiographs of the scaphoid obtained at review showing a definite non-union of the scaphoid defined as a clear gap (arrow) at the fracture site one year after injury

FIGURE 3.6-2 : Probably united scaphoid fracture

Radiograph of the scaphoid obtained at review. The site of the scaphoid waist fracture can be easily identified (arrow) but the fracture appears to have united. These fractures were considered to be 'probably' united. There is a small step on the outer aspect of the scaphoid. Five of the 20 patients with 'probable' union had such a step, only three of whom were symptomatic

SECTION 3.7

UNION IN TREATED FRACTURES OF THE SCAPHOID

The study outlined in the previous section (3.6), suggested that there were three patterns of union : the fracture could have (1) united, (2) not united or (3) probably united if the site of the fracture could be easily identified. The prospective study described in section 3.4 demonstrated that there was no difference in the outcome between patients treated in a scaphoid cast and those treated in a Colles' cast. I therefore investigated whether there were any differences between patients in whom the fracture had united, those in whom it had probably united and those in whom there was failure of union.

PATIENTS & METHOD

One hundred and eighty five patients described in section 3.4 were studied. The clinical and radiographic methods used are detailed in that section. These patients were divided into three groups : those in whom the fracture had united, those in whom it had probably united and those in whom the fracture was ununited.

RESULTS

The mean age, sex distribution, duration in plaster cast and mechanism of injury in the three groups is listed in Table 3.7-I. Those with a probable union were older than those with definite union and non-union. There were proportionately more females in this group. The duration in plaster cast reflected the outcome with those progressing to non-union being immobilised for a longer period. The mechanism of injury was similar in the three groups.

Figure 3.7-1 demonstrates that all the distal fractures had united, while 10 of the 31 patients with a horizontal oblique fracture were either probably united (n=6) or ununited (n=4). Four of the 5 vertical oblique fractures were probably united at six months. Of the 128 transverse waist fractures 90 were united, 24 were probably united while 14 were not united. Of the 5 proximal pole fractures one had probably united while 2 were ununited. Displaced fractures were particularly prone to develop a non-union (Figure 3.7-2)

The level of activities while immobilised in the cast was greater in patients who developed a non-union although the differences were not significant (analysis of variance $p > 0.2$ for 1,2 4,8 and 12 weeks after injury). There was no difference between the three

groups in the level of activities after removal of the cast (Figures 3.7-3 & 3.7-4). The state of the cast was recorded as satisfactory or unsatisfactory if the cast was soft (especially in the palm) or loose. A greater proportion of patients with probable union or non-union had unsatisfactory plaster casts. The differences between the three groups (Figure 3.7-5) was assessed by analysis of variance and was not significant ($p > 0.08$ at 1,2,4,8,12 weeks). However, a linear trend with insignificant deviation from linearity could be identified between the state of union and the state of the cast.

The range of movement (Figure 3.7-6) was significantly poorer in those with a probable union and even less in those with a non-union throughout the study period ($p < 0.0001$ for the 8,12,16 and 26 weeks assessment).

DISCUSSION

This study confirmed earlier observations that there appeared to be three patterns of union. Those in whom the fracture had united were younger and there were more males (M:F 4:1). Their range of movement, grip strength and span was excellent. Their activity in the cast was more restricted but the condition of the cast was superior.

Those in whom the fracture was probably united were older and there were proportionally more females (M:F 3:1) Their activities in the cast was better than patients with definite union, but over 50% of the patients had loose or soft casts as noted at each review while in the cast. Their wrist movement was as good as that in patients with definite union.

Patients with a non-union were as young as those with a definite union and were almost all male. Their activity while immobilised in the cast was the best of the three groups and this was reflected in the observation that over 50% had unsatisfactory casts. Their range of movement was around 75% that of the opposite wrist. Horizontal oblique and transverse fractures accounted for most of the non-unions while 2 of the 5 proximal pole fractures had a non-union.

CONCLUSION

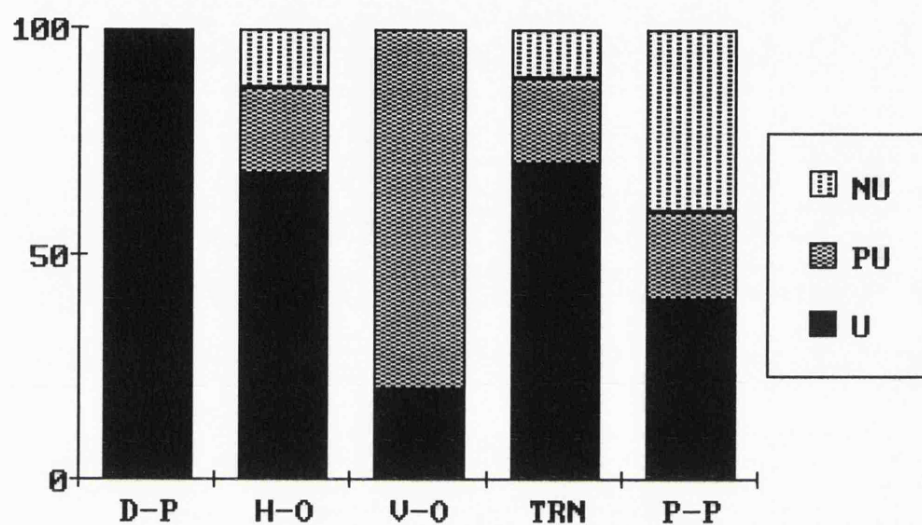
This analysis confirmed the conclusions in the previous section and also suggested that the level of activity while in the cast and the condition of the cast could both adversely influence the outcome.

Table 3.7-I : Comparison of three outcome groups

	United	Probably united	Ununited	p =
Age (years)	28.5(15.9)	34.9(18.2)	28.4(7.7)	0.098
Sex	101/28	26/9	19/1	0.163
Time in cast (weeks)	8.7(1.8)	10.3(2.0)	11.9(1.0)	0.000
	n = 128	n = 35	n = 20	

The standard deviation is noted in brackets.

FIGURE 3.7-1 : Bohler type vs Outcome



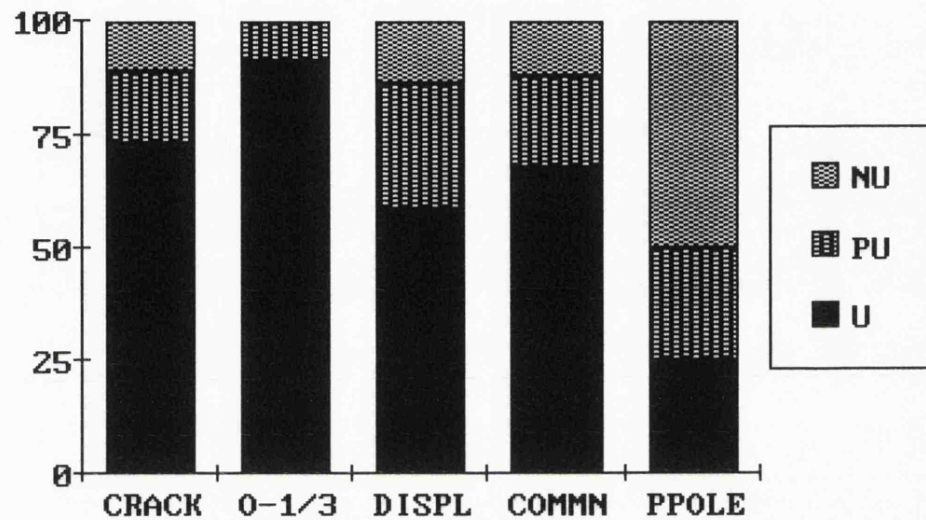
DATA TABLE 3.7-1 : Bohler type vs Outcome

Type	U	PU	NU
D-POLE	15	0	0
H-OBLQ	21	6	4
V-OBLQ	1	4	0
TRANSV	90	24	14
P-POLE	2	1	2

$\chi^2 = 23.20, p = 0.003.$

D-POLE - distal third fractures, H-OBLQ - horizontal oblique fractures, V-OBLQ - vertical oblique fractures, TRANSV - transverse waist fractures, P-POLE - proximal pole fractures.

FIGURE 3.7-2 : Herbert type vs Outcome



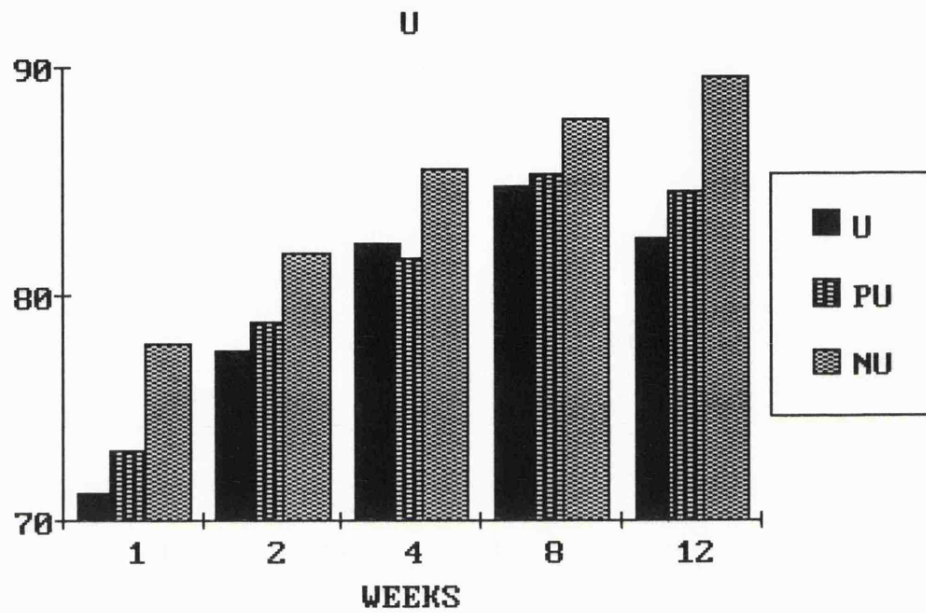
DATA TABLE 3.7-2 : Herbert type of fracture and outcome

Type	U	PU	NU
Crack	47	10	7
Oblq-1/3	30	3	0
Displ	34	16	8
Comm	17	5	3
PP	1	1	2

$\chi^2 = 18.86, p = 0.042.$

Crack - crack fracture without any displacement, Oblq 1/3 - distal third oblique fractures, Displ - displaced fractures (see section 3.4), Comm - comminuted fractures, PP - proximal pole fractures, 1 was displaced

FIGURE 3.7-3 : Activity in the cast

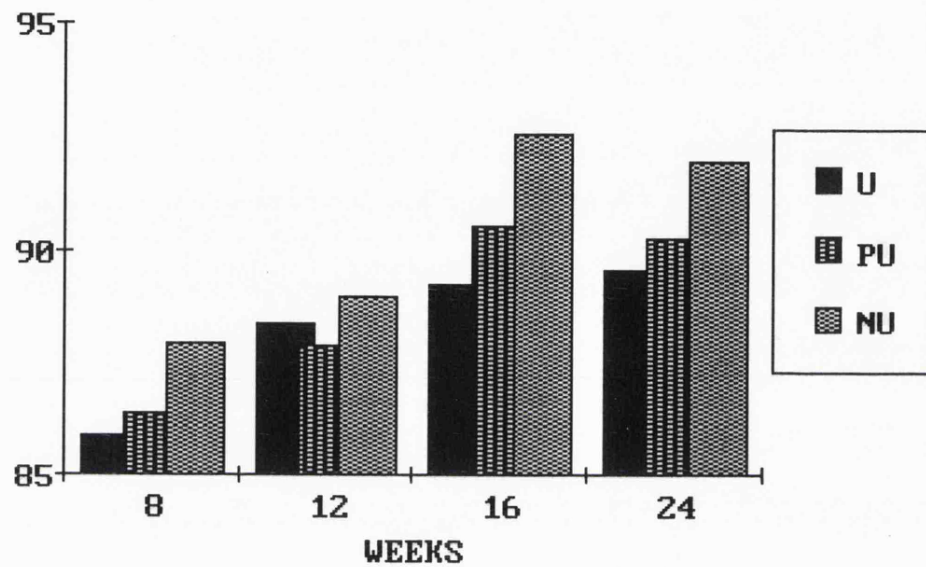


DATA TABLE 3.7-3 : Activity while in the cast

Week	U	PU	NU	p =
1	71.3 (13.8)	73.1 (12.9)	77.9 (9.6)	0.213
2	77.6 (13.0)	78.9 (11.6)	81.9 (10.7)	0.377
4	82.4 (12.4)	81.7 (11.8)	85.6 (10.6)	0.470
8	84.9 (11.7)	85.4 (10.7)	87.8 (10.4)	0.588
12	82.6 (11.6)	84.7 (11.7)	89.7 (11.0)	0.747

U - united fractures n=128, PU - probably united fractures n=35, NU - ununited fractures n=20. (standard deviation). The calculation of the activity level is described in section 3.4

FIGURE 3.7-4 : Activity after cast removal

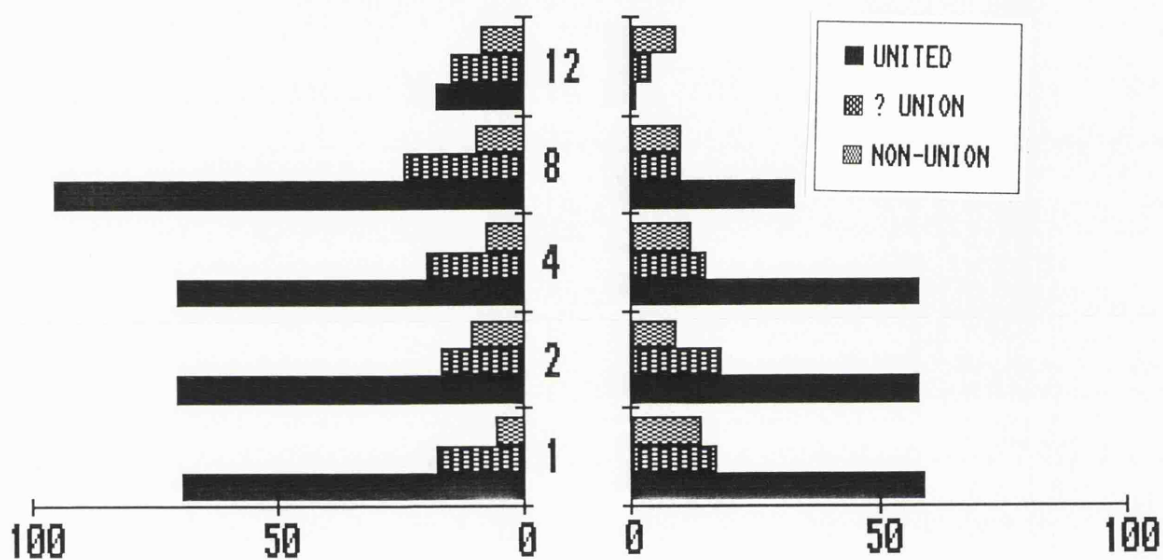


DATA TABLE 3.7-4 : Activity after cast removal

Week	U	PU	NU	p =
8	85.9 (11.3)	86.4 (11.3)	88.0 (10.7)	0.747
12	88.4 (10.6)	87.9 (11.7)	89.0 (11.1)	0.940
16	89.3 (10.0)	90.6 (10.1)	92.6 (9.9)	0.369
24	89.6 (9.9)	90.3 (10.1)	92.0 (10.0)	0.600

U - united fractures n=128, PU - probably united fractures n=35, NU - ununited fractures n=20. (standard deviation). The calculation of the activity level is described in section 3.4

FIGURE 3.7-5 : Condition of the cast



DATA TABLE 3.7-5 : Condition of the cast

Week	U		PU		NU		p =
1	70	(59)	18	(17)	6	(14)	0.130
2	71	(58)	17	(18)	11	(9)	0.788
4	71	(58)	20	(15)	8	(12)	0.412
8	96	(33)	25	(10)	10	(10)	0.081
12	18	(1)	15	(4)	9	(9)	0.006
		n = 128		n = 35		n = 20	

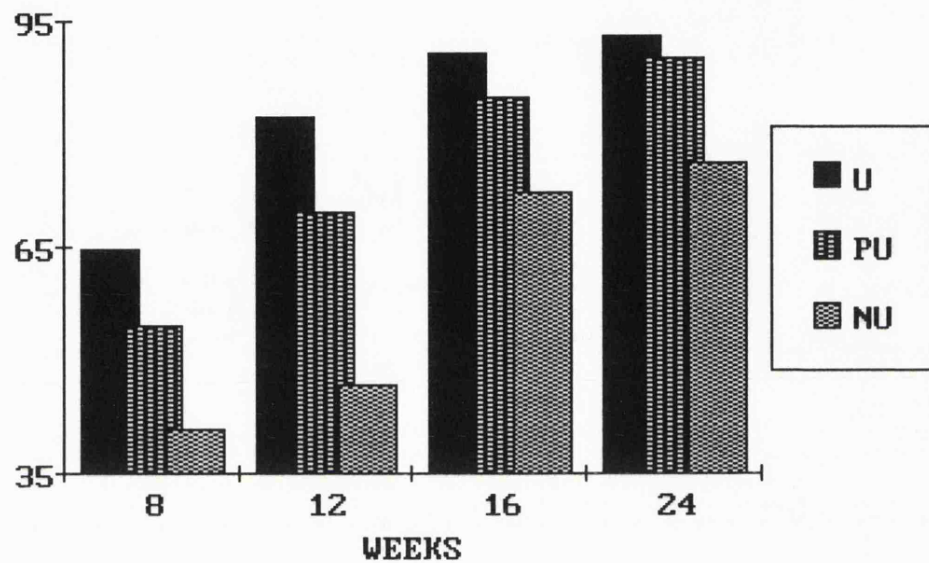
Overall cast condition (see text for description)

5.6 sd 1.3 5.7 sd 1.4 6.3 sd 1.1 0.013

Linearity : Sum Squares - 6.0, p = 0.066, Deviation from linearity p = 0.429

Figures represent : satisfactory casts (unsatisfactory casts).

FIGURE 3.7-6 : Recovery of wrist movement



DATA TABLE 3.7-6 : Recovery of wrist movement

Week	U	PU	NU	p =
8	64.9 (15.0)	55.0 (19.1)	41.3 (18.7)	0.000
12	82.4 (15.9)	69.9 (22.6)	47.2 (18.6)	0.000
16	91.1 (11.3)	85.1 (15.8)	72.4 (12.0)	0.000
24	93.4 (9.1)	90.4 (12.7)	76.2 (18.0)	0.000

U - united fractures n=128, PU - probably united fractures n=35, NU - ununited fractures n=20. (standard deviation). The calculation of the percentage wrist movement is described in section 3.4

SECTION 3.8

REAL TIME ULTRASONOGRAPHY IN THE ASSESSMENT OF MOVEMENT AT THE SITE OF A SCAPHOID FRACTURE NON-UNION

The exact incidence of non-union of fractures of the waist of the scaphoid is not known. Almost all previous studies (Leslie & Dickson 1981, Russe 1960) which have noted an incidence of non-union ranging from 5 to 50% have based their observations on a set of radiographs of the injured scaphoid obtained at or before 12 weeks following injury. These studies have used 'established' criteria of trabeculae crossing the fracture line or sclerosis at the fracture line (Lindgren, 1949) as demonstrating union at the fracture site. It has been demonstrated (section 3.5) that these signs could not be used to provide reliable evidence of union of a scaphoid fracture.

The only relatively certain method of demonstrating union of any fracture is to show that no movement occurs at the fracture site on stressing the fracture. While this is possible in long bones such as the tibia, it is unreliable near joints or when the bone is small. The scaphoid suffers from both these disadvantages. Nevertheless, using patients with a definite non-union of the scaphoid as a model, the use of real time

ultrasonography in determining movement at the fracture site was investigated.

PATIENTS

27 patients with established non-unions of fractures of the waist of the scaphoid were studied. Their mean age was 27.4 ranging from 16 to 71 years. There were 24 males and three females. Twenty four patients were seen over one year after injury and on radiographs obtained at this interval the fracture was not considered to be united if a clear, unequivocal gap was seen at the fracture site (Maudsley & Chen 1972). Three patients in whom tenderness was present at 12 to 16 weeks after injury and radiographs of the scaphoid were equivocal were also assessed using ultrasonography.

METHOD

A: ULTRASONOGRAPHIC ASSESSMENT OF NON-UNION

The stability of the non-union was assessed using a 5MHz linear probe of the Acuson 128 ultrasound imaging system. The scaphoid was imaged as follows : With the forearm supine and the wrist in neutral the hand was placed on the examination table and the tuberosity of the scaphoid was identified by palpation. The 5MHz probe was then placed on the hand over the tuberosity of the scaphoid and the radius as shown in Figure 1. The first metacarpal and the trapezium could be easily identified and, by gradual movement of the probe proximally, the volar surface of the scaphoid could be visualised as a

surface which slopes away from the probe proximally (figure 2 a,b). In the uninjured wrist, this surface resembled the anterior aspect of the scaphoid as seen on the lateral radiographic view of the wrist. This surface was seen to be continuous. The wrist was then moved from a maximum ulnar deviation to maximum radial deviation (figure 3 a,b). In ulnar deviation the scaphoid straightened out while in radial deviation it flexed forward. Next the wrist was moved passively from about 30 degrees of dorsiflexion to neutral and the movement of the scaphoid was noted.

Examination of the injured wrist was done in a similar manner. Any discontinuity of the volar scaphoid surface was noted (figure 4 a,b). The wrist was then moved in the sagittal and coronal planes as described above. Any widening/ narrowing of the volar gap on further stressing (movement of the hand from ulnar deviation to radial deviation and on dorsiflexing the wrist) was documented. Finally, the relative movement between the proximal and distal poles of the scaphoid could be documented although in the absence of movement at the gap this was often difficult to appreciate. These real-time images were recorded on a VHS video cassette.

Three factors were, therefore, assessed : (1) the presence of a volar gap, (2) further opening of the gap on wrist movement and (3) relative movement between the proximal and distal poles of the scaphoid.

B: PER-OPERATIVE ASSESSMENT

Twenty four patients had surgery to bone graft and internally fix the non-union using a countersunk A.O. small fragment cancellous screw. At operation the following details were documented : (1) Presence of a volar gap, (2) opening of the gap on wrist movement and (3) relative movement between the two poles on radio-ulnar deviation and on flexion-extension of the wrist. The stability of the non-union was, thereby, determined.

The data was analysed using the Statistical package for social sciences (SPSS-X) at the University of Leicester.

RESULTS

29 patients were listed for bone grafting and internal fixation of a scaphoid fracture non-union. Two patients, one who had left the county and another who refused to participate in the study were excluded. Twenty-seven patients were studied. Their mean age was 27.4 years (SD 11.5 years, range 16 to 71). Twenty four were male and three were female. There were 18 transverse waist fractures, 6 horizontal waist fractures and three fractures of the proximal pole of the scaphoid.

Fifteen of these patients had had their wrist immobilised in a below elbow cast (including the thumb) for over six weeks (mean 12.1 weeks). Five patients did not have their wrists immobilised after injury. A further 7 patients had the wrist immobilised between 2 and 6 weeks.

Twenty four patients were reviewed over one year after injury (mean 2.5 years, SD 1.7, range 1 to 7 years). Three patients were seen between 12 and 16 weeks after injury; their radiographs had failed to provide definite evidence of a non-union. These patients had been immobilised between 6 and 10 weeks (mean 8.5 weeks).

A: ULTRASONOGRAPHIC EXAMINATION OF THE SCAPHOID

All 27 patients had ultrasonographic assessment of the scaphoid (Table 3.8-I). A definite volar gap was present in 22 patients (Figure 3.8-5). In 18 of these patients this gap widened on wrist dorsiflexion and ulnar deviation and narrowed on palmar flexion and radial deviation. Of the remaining 4 patients with a gap only one was shown to have relative movement of the proximal and distal parts of the scaphoid : in 3 no movement could be demonstrated at the fracture site (case numbers 12,22,23). Two of these patients had surgical exploration. In both an anterior defect in the scaphoid was found. This contained fibrous tissue. However the scaphoid appeared to have united dorsally and no

movement could be elicited either at the gap or between the proximal and distal parts of the scaphoid. Tomograms obtained prior to surgery had suggested such a possibility but were not conclusive. The third patient was a 47 year old female who did not have any pain in the wrist and therefore surgery was not recommended.

In 5 patients ultrasonography did not demonstrate a gap in the volar surface of the scaphoid. In one of these a gap appeared on dorsiflexion and ulnar deviation of the wrist. In the remaining four patients no movement could be detected between the proximal and distal parts of the scaphoid. Three of these had proximal pole fractures.

B: ULTRASONOGRAPHIC FINDINGS vs SURGICAL OBSERVATIONS

Twenty four of the 27 patients had surgery. Three patients did not have surgery: one refused surgery in spite of demonstration of movement at the gap in the scaphoid. The other two were not offered surgical fixation as no movement could be demonstrated at the fracture site. Of the 24 patients who had surgery 21 had an obvious gap on ultrasonography - 17 were confirmed at surgery (Table 3.8-III). Four patients had a gap on ultrasonography which was not confirmed at surgery. These represented the 'peanut' fracture with a large cavity at the site of the fracture with a cartilaginous rim which is non echogenic and therefore not seen on ultrasonography. The correlation between the surgical and ultrasonographic assessment of movement at the

fracture site was very high ($r = 0.948$, $p = 0.0000$).

DISCUSSION

A: ULTRASONOGRAPHIC ASSESSMENT OF SCAPHOID NON-UNION

Assessing scaphoid fracture union can be difficult as radiographs may not clearly and reproducibly demonstrate union (Dias et al, 1988). The small size of the scaphoid, its' oblique orientation and its' articulation with several bones makes assessment of mobility of the fracture site very difficult, if not impossible. Radiographic stress views to demonstrate movement are difficult to obtain and interpret. Invasive investigations such as wrist arthrography (Roy et al 1985) and scaphoid tomograms have been suggested to try and overcome this difficulty. Real time ultrasonography provided a non invasive method of assessing scaphoid fracture union. The volar defect, if present, could be easily visualised. This in itself was not an indicator of non-union as partial dorsal bony union could have occurred. Conclusive evidence of non-union was only established by demonstrating movement at the fracture site.

Early surgical reduction and internal fixation of scaphoid waist fractures which 'fail to unite' after 6 (Herbert & Fisher 1984) to 12 weeks (Cooney et al 1980, Maudsley & Chen 1972) has been recommended. Cooney et al (1980) suggested that in displaced fractures, if the

reduction was lost or not achieved open reduction should be carried out. They suggested stress radiography, traction oblique views or trispiral tomography to assess union of these fractures. Others have based the decision to operate on radiographs obtained between 6 and 12 weeks following injury. While the benefits of internal fixation with regard to shorter immobilisation period and earlier return to work (Maudsley & Chen 1972) are attractive it would be difficult to recommend internal fixation on the basis of radiographic findings which have been shown to be unreliable (Dias et al, 1988). Three patients with scaphoid fractures in whom radiographs at 12 to 16 weeks were inconclusive were investigated by ultrasonography in this study. In one patient with a proximal pole fracture it was found to be of no value. However, in both remaining patients, ultrasonography demonstrated movement at the fracture site. These patients had surgical fixation which resulted in bony union.

B: DIFFICULTIES IN DEMONSTRATING THE SCAPHOID

Proximal pole fractures were very difficult to image and the findings were, in all three cases in this study, inconclusive. This probably reflects the site of the fracture as well as the absence of a volar gap and absence of any gross instability at the fracture site. In these patients the avascularity of the proximal pole probably plays a major role in the etiology of

non-union.

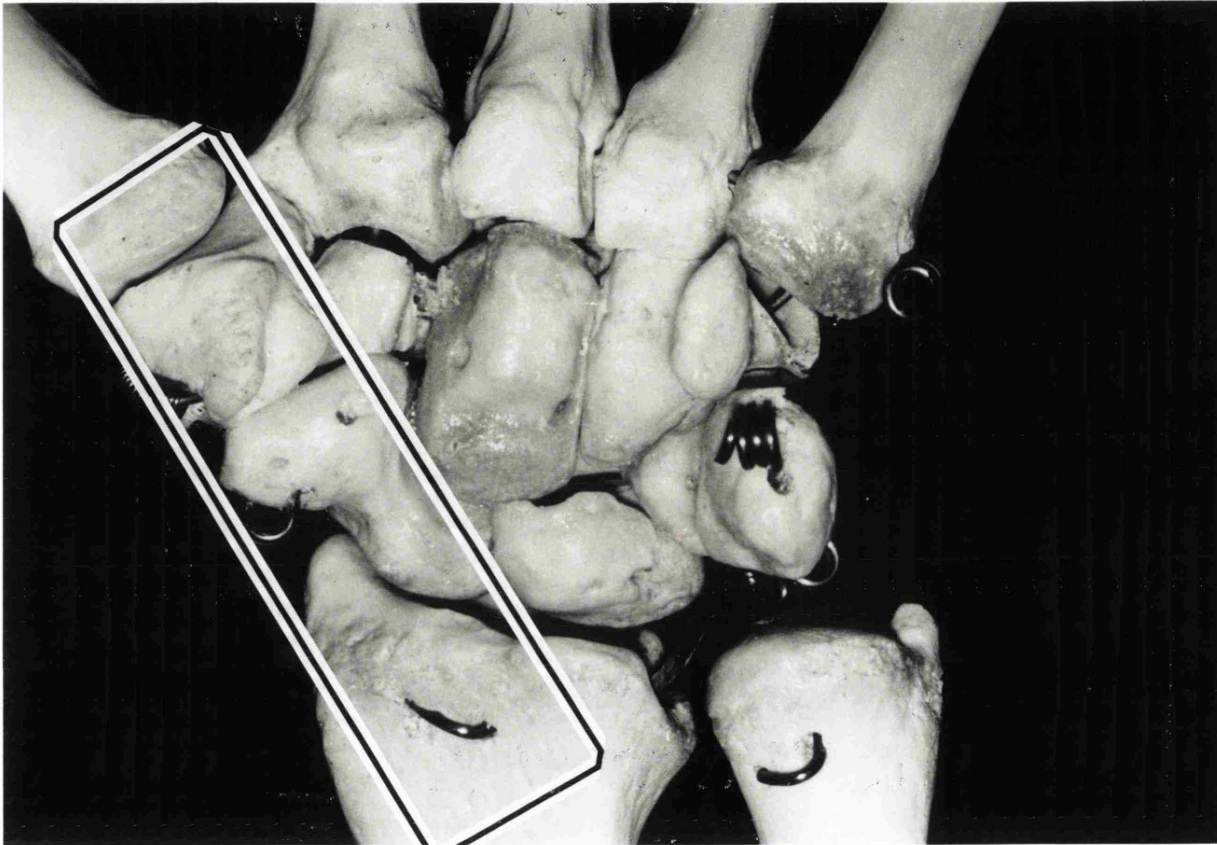
Generally, assessment of the injured wrist was more difficult than the contralateral normal wrist. Patients with marked wrist stiffness were especially difficult to image and assess movement at the fracture site. Non-unions in which the distal part was flexed on the proximal part were also difficult to image. In order to avoid mistaking either the scapho-trapezium joint, the radio-scaphoid or the scapho-lunate joint for a fracture we routinely assessed the normal side before the injured side. Finally, since ultrasonography is observer dependant, the real time investigation was always recorded on VHS video cassette and was therefore available for review.

By demonstrating movement at the fracture site, real time linear ultrasonography could be of great value in assessing the state of union of a scaphoid fracture after 8 to 12 weeks of immobilisation in which radiographs were inconclusive. The demonstration of movement at the volar gap would provide definite evidence of failure of union and would indicate the need for surgical fixation of the fracture. Scaphoid injuries (apart from those of the proximal pole) in which no movement at the fracture site could be demonstrated should perhaps be treated expectantly; the wrist being protected in a removable splint.

CONCLUSION

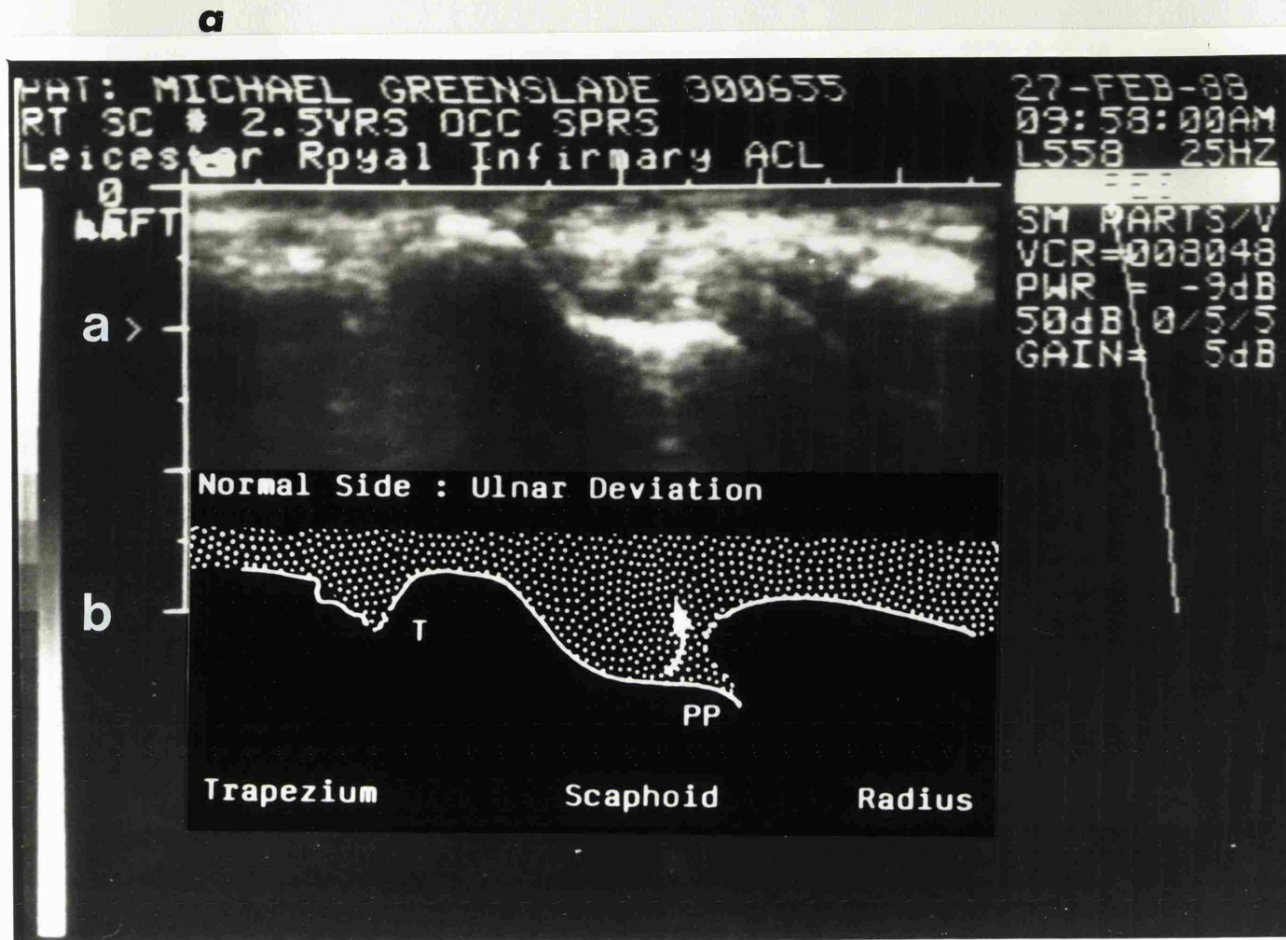
A method of assessing movement at the fracture site in scaphoid waist fractures using real time linear ultrasonography which is non invasive and repeatable has been established. Such assessment of scaphoid fractures, 6 to 12 weeks after injury with equivocal radiographs, could identify those fractures with gross movement which might benefit from early internal fixation. This would shorten the morbidity and time spent off work.

FIGURE 3.8-1



The exact location of the 5 MHz linear ultrasonography probe used to image the scaphoid volar surface is demonstrated on an articulated skeleton of the hand. This demonstrates the bones one would see in the ultrasound scan.

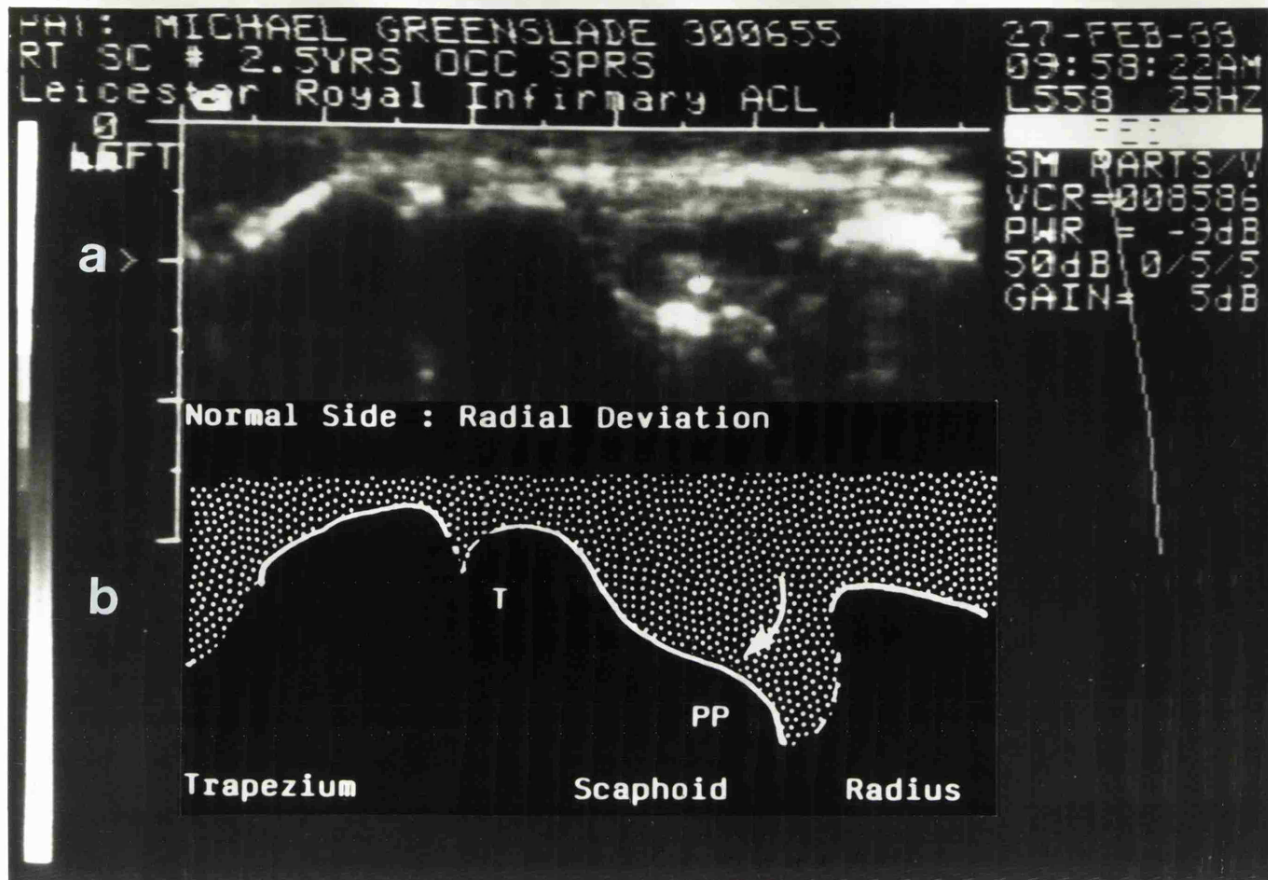
FIGURE 3.8-2.



This demonstrates an ultrasound image of a normal scaphoid (a) with an explanatory diagram (b). T=scaphoid tuberosity, PP= proximal pole.

The plane of the scaphoid (appreciated by a line joining the proximal and distal poles of the scaphoid) is almost in line with the plane of the hand (appreciated by a line joining the trapezium and radius). This scan was obtained with the hand in maximum ulnar deviation when the scaphoid lies in an extended position.

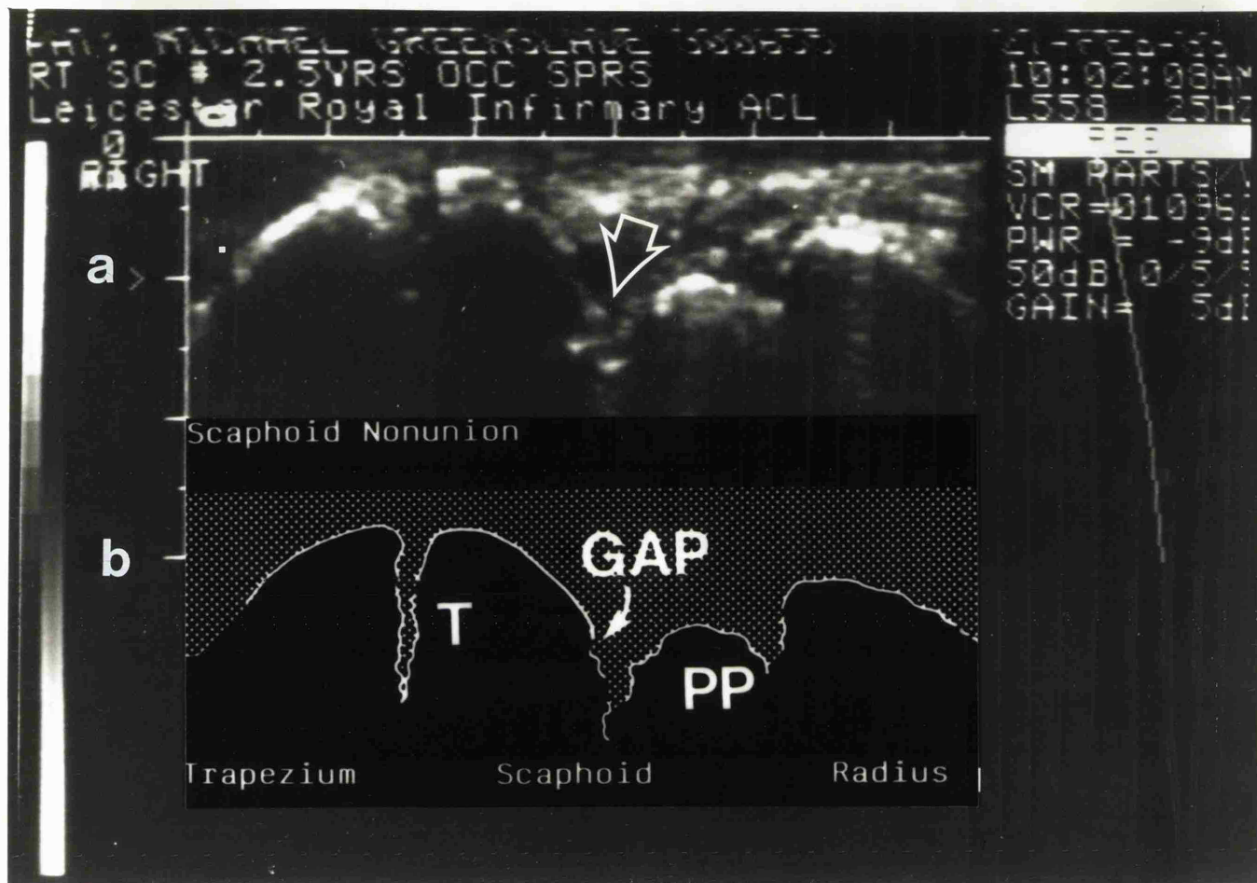
FIGURE 3.8-3.



This demonstrates an ultrasound image of a normal scaphoid (a) with an explanatory diagram (b). T=scaphoid tuberosity, PP= proximal pole.

The plane of the scaphoid (appreciated by a line joining the proximal and distal poles of the scaphoid) is now at an increased inclination to the plane of the hand (appreciated by a line joining the trapezium and radius). This scan was obtained with the hand in maximum radial deviation when the scaphoid lies in an flexed position.

FIGURE 3.8-4.



This demonstrates an ultrasound image of an ununited scaphoid fracture (a) with an explanatory diagram (b). T=scaphoid tuberosity, PP= proximal pole.

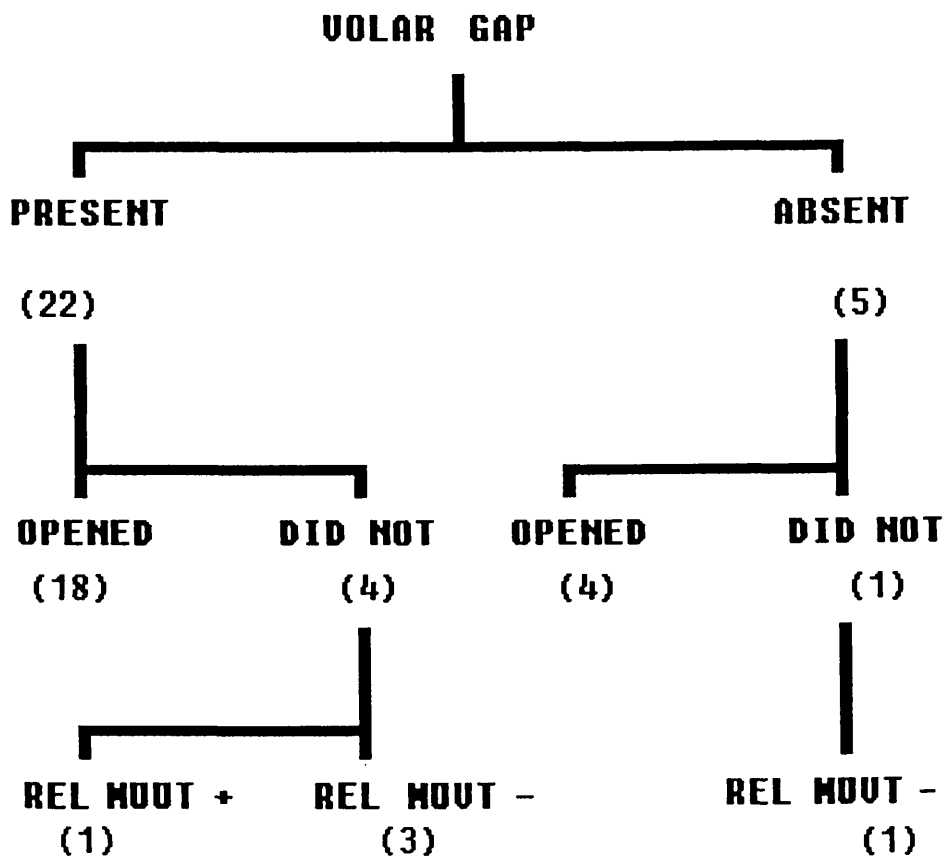
A distinct gap can be seen between the proximal and distal poles of the scaphoid. Real time scanning demonstrated opening and closing of this gap.

TABLE 3.8-I : PATIENT DETAILS

Sno	Age	Sex	Diag	POP	FU	ULTRASONOGRAPHY			SURGERY		
						GAP	OPEN	REL MOVT	GAP	OPEN	REL MOVT
1	24	M	TW	6	1.9	Yes	D	D	Yes	D	D
2	38	M	HW	16	1.7	No?	S	No	No	S	S
3	21	M	TW	0	1.7	Yes	S	No	Yes	S	S
4	25	M	HW	14	2.8	Yes	S	S	Yes	S	S
5	37	M	TW	6	1.6	Yes	D	D	Yes	D	D
6	21	M	PP	0	1.	No	N	N	No	No	No
7	18	M	HW	6	2.4	Yes	D	D	Yes	S	S
8	20	M	TW	9	2.2	Yes	D	D	Yes	D	D
9	71	M	HW	10	0.3	Yes	D	D	No	S	S
10	24	F	TW	12	1.4	Yes	D	D	Yes	D	D
11	20	M	TW	9	1.6	Yes	D	D	Yes	D	D
12	24	M	TW	20	1.8	Yes	No	No	Yes	No	No
13	23	M	TW	6	1.0	Yes	D	D	Yes	D	D
14	16	M	TW	0	3.8	Yes	D	D	Yes	D	D
15	29	M	TW	16	2.4	Yes	D	D	Yes	D	D
16	26	M	TW	12	1.5	Yes	D	D	Yes	D	D
17	23	M	TW	8	2.5	Yes	D	D	Yes	D	D
18	28	M	PP	0	1.1	No?	No	No	No	No	No
19	21	M	TW	0	5.9	Yes	No	S	No	No	S
20	22	M	HW	0	6.9	Yes	D	D	Yes	D	D
21	18	M	TW	14	6.4	Yes	D	D	Refused surgery		
22	47	F	TW	12	1.9	Yes	No	No	No Surgery		
23	18	F	HW	6	2.4	Yes	No	No	No Surgery		
24	32	M	TW	12	1.3	No	No	No	Yes	No	No
25	22	M	TW	2	1.5	Yes	D	D	Yes	D	D
26	38	M	TW	8	0.25	Yes	D	D	Yes	D	D
27	31	M	PP	10	0.25	No	No	No	No	No	No

TW : Transverse waist #, HW : horizontal waist #, PP: proximal pole #, D : definite-marked, S: present-moderate.

TABLE 3.8-II : ULTRASONOGRAPHIC ASSESSMENT OF SCAPHOID
NONUNION



Case number:

19

12,22,23

6,18,24,27

TABLE 3.8-III: ULTRASONOGRAPHY vs SURGICAL OBSERVATIONS

A: Volar Gap

	SURGERY : GAP	NO GAP
<hr/>		
ULTRASONOGRAPHY		
GAP	17	4
NO GAP	0	3
<hr/>		
$\chi^2 = 8.32$, DF = 2, p = 0.016		

B: Movement

	SURGERY : NONE	SLIGHT	MARKED
<hr/>			
ULTRASONOGRAPHY			
NONE	6	0	0
SLIGHT	0	3	0
MARKED	0	3	12
<hr/>			
$\chi^2 = 43.2$, p = 0.0000 (r = 0.95, p = 0.0000)			

SECTION 3.9

SCAPHOID FRACTURE NON-UNION AND AVASCULAR NECROSIS

The incidence of avascular necrosis of the proximal part of the scaphoid in an un-united fracture and its role in the development of non-union is a subject of much controversy. There is wide variation in the reported incidence of avascularity of the proximal part of the scaphoid after a fracture. Following recent fractures, it can vary from 1 % (Leslie & Dickson 1981) to 44 % (Bohler et al 1954). In scaphoid fracture non-union, too, the incidence of proximal avascularity varies widely, ranging from 9 % (Leslie & Dickson 1981) to 40 % (Mulder 1968). It has been suggested that avascularity is one of the factors in the pathogenesis of non-union (Cooney et al 1980) although it does not appear to preclude bony union (Stewart 1954, Bohler et al 1954).

The diagnosis of avascular necrosis of the proximal part of the scaphoid is usually based on radiographic appearance of increased density. These radiographic changes may be unreliable. The vascular status of the proximal and distal parts of 20 established scaphoid non-unions was studied to determine the incidence of avascularity and its relationship to radiographic appearances and clinical findings.

PATIENTS

Twenty consecutive patients with a non-union of a scaphoid fracture were included in the study. Their mean age was 26.7 years (SD 1.6 years, range 19 to 48). There were 19 males and one female. The mean interval since injury was 2.3 years (SD 1.6 years, range 1 to 6.9 years). The mean time in plaster cast was 7.1 weeks (SD 5.6 weeks, range 0 to 16 weeks). Non-union was defined as the presence, on a radiograph, of a clear gap at the fracture site over one year after injury (Maudsley & Chen 1972).

METHOD

A: RADIOGRAPHIC ASSESSMENT OF AVASCULARITY

Each patient had five radiographic views of the scaphoid : postero-anterior, lateral, semi supine, semi prone and the Ziter (1973) views. Similar radiographs of the opposite normal side were obtained for comparison. On each view the scaphoid was carefully scrutinised. The density of the proximal scaphoid was compared with (a) the distal pole and (b) the lunate and the capitate. Its appearance was then compared to that of the opposite scaphoid on a corresponding view (Figure 3.9-1). The proximal pole was considered not to be avascular if its' density matched that of the distal pole, the lunate and the capitate and its appearance matched that of the

contralateral scaphoid. It was considered to be definitely avascular (Figure 3.9-2) if its density was increased in comparison to the distal scaphoid and the lunate & capitate. In addition its' appearance had to be different when compared to the corresponding view of the contralateral scaphoid. Increased density had to be present in at least two views. Any appearance of increased density which did not meet the above arbitrary criteria was considered to represent probable avascularity (Figure 3.9-3).

B: HISTOLOGICAL ASSESSMENT OF AVASCULARITY

All twenty patients had surgery to bone graft and internally fix the scaphoid. Bone currettings were obtained from the proximal pole and the distal pole. In eight patients a sample of normal bone from the donor area (distal radius) was also obtained. This bone was decalcified, processed and stained with haematoxylin and eosin using a standard technique.

The specimens were all examined by a senior bone histopathologist (Dr A J Malcolm) with particular reference to the presence of : (1) Normal bone with populated lacunae, mature lamellar matrix and normal marrow, (2) Reactive bone (Figure 3.9-4) demonstrating reactive new woven bone lining normal

bone without any evidence of necrosis. The adjoining marrow spaces demonstrated hypercellularity, the cells being fibrocytes. (3) Revascularised bone (Figure 3.9-5) with a central core of avascular, acellular and mature bone surrounded by hypercellular immature woven bone and reactive cellularity in the marrow and (4) Necrotic bone (Figure 3.9-6) with empty lacunae, lamellar matrix without any evidence of new bone formation.

Each specimen was examined and a comment was made on these four patterns as follows : (a) not present, (b) present but not immediately obvious and (c) present and immediately obvious - is the predominant pattern.

In addition to the radiological and histological observations, symptoms (pain & stiffness) and findings on examination (tenderness, scaphoid stress test as described by Watson et al 1986, range of wrist movement and grip strength as described in section 3.4) were also documented.

The data was analysed using the Statistical package for social sciences (SPSS-X) at the University of Leicester.

RESULTS

Not surprisingly, the proximal part of the scaphoid had

a higher incidence of avascular changes (revascularised bone and necrotic bone) than the distal part (Figure 3.9-7). The proximal part of the scaphoid demonstrated necrotic bone as the predominant pattern in eight of the twenty patients.

A: RADIOGRAPHS vs HISTOLOGY

Radiographs did not appear to provide a reliable indication of proximal scaphoid avascularity even when precise criteria were used (Table 3.9-I). Of the fifteen patients with normal radiological appearance of the proximal scaphoid eight had distinct avascularity of the proximal scaphoid on histological examination.

B: HISTOLOGY

The proximal scaphoid was distinctly different from the distal scaphoid in eleven of the twenty patients. In one patient the distal part of the scaphoid also demonstrated some evidence of avascularity. In six patients no difference could be detected between the proximal and distal poles while in two the difference could only be established on careful review of the histology to pick out the occasional necrotic bit of bone.

The twenty patients can, therefore, be broken down into two groups as follows: (1) those in whom the proximal pole was avascular and (2) those in whom the proximal pole was either normal ($n = 7$) or could be differentiated from the distal scaphoid with difficulty

(n = 2). One patient did not have adequate sampling of the distal pole, the proximal pole was however sampled and the bone was found to be histologically normal. This patient was therefore included in the 'normal' group. The clinical parameters were then studied to see if these two groups of patients were distinct.

The two groups were comparable for age, interval since surgery (Table 3.9-II). Those in whom the proximal pole was not avascular appeared to have spent longer in a plaster cast but the differences were not significant on t-test. Symptoms of pain & stiffness were comparable in the two groups and so too was the range of wrist movement and grip strength. However, more patients with essentially normal proximal poles appeared to have local tenderness and significant discomfort on the scaphoid stress test (after Watson et al 1986).

DISCUSSION

A: RADIOGRAPHIC IMPRESSION OF AVASCULARITY

The incidence of radiographic evidence of avascular necrosis of the proximal part of the scaphoid in recent fractures varies from 1 to 44 % (Leslie & Dickson 1981, Bohler et al 1954, Russe 1960, Compere & Banks). It has been emphasised (Russe 1960) that increased density is not a sign of impending non-union and does not contraindicate continued conservative treatment

(Stewart 1954). The increased radiological density usually improves although it might persist for several years (Bohler et al 1959).

The effect of avascularity on bony union is not well understood. Cooney et al (1980) suggested that union of a scaphoid fracture depends on a number of factors including blood supply. Herbert stated that 50% of fractures of this bone which demonstrated delayed union showed signs of ischaemia. The reported incidence of radiographic evidence of avascular necrosis in patients with an established non-union of scaphoid waist fractures varies from 9% to 40 % (Leslie & Dickson 1981, Cooney et al 1980, Mulder 1969). Ruby et al (1985) in their study on long term results of scaphoid fracture non-union were surprised to note that only 2 of 55 patients had increased density of the proximal part of the scaphoid on radiographs.

In the present study of the 20 patients with a non-union only four patients were considered to demonstrate any evidence of proximal avascularity on radiographs.

B: PROXIMAL POLE AVASCULARITY

The nature of the blood supply of the scaphoid renders its proximal part liable to develop avascular necrosis. The major blood supply to the scaphoid is the radial artery (Gelberman & Menon 1980, Taliesnik & Kelly 1966). 70 % to 80 % of the scaphoid including the proximal

pole receives blood from vessels entering through the dorsal ridge. The tuberosity and the distal 20 % to 30 % of the bone is supplied by volar branches of the radial artery or its' superficial palmar branch. There are no significant intraosseous anastomoses between the dorsal and volar branches (Gelberman & Menon 1980). In a study of the nutrient foramina of 297 scaphoids, Oblatz & Halbstain (1938) demonstrated three patterns : in Type I (13%) no vascular foramina could be found proximal to the scaphoid waist, in Type II (20%) a single small foramen was seen at or proximal to the waist while in Type III (67%) two or more foramina were seen proximal to the waist of the scaphoid. They suggested that in the first and second type the blood supply to the proximal pole was precarious. It is perhaps fractures in such scaphoids that vascularity is compromised. This might make them susceptible to non-union.

Although only 4 of the twenty scaphoid non-unions demonstrated radiological changes suggesting proximal avascularity, the histological study of bone taken from each of the two parts of the scaphoid demonstrated that in around half the patients studied the proximal pole was avascular in comparison to the distal scaphoid. In these patients it would appear that avascularity might have been an important factor in the aetiology of the non-union.

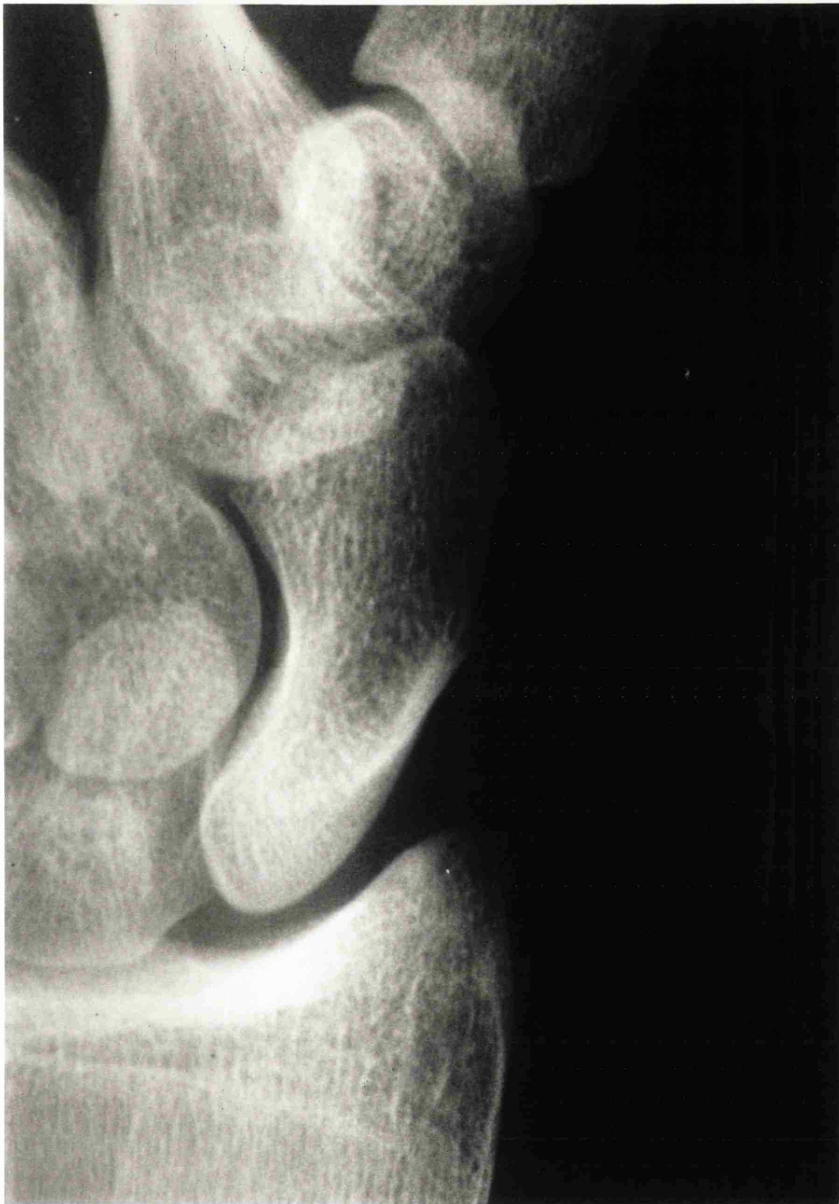In the remaining 9 patients the pattern of blood supply

must have been of type II or type III (Obletz & Halbstern 1938) as there was evidence of revascularisation of the bone proximal to the fracture. In these patients increased mobility at the fracture site was, perhaps, a major factor in determining the onset of non-union. This was reflected by more patients in this group having a positive scaphoid stress test which might suggest increased movement at the fracture site.

CONCLUSION

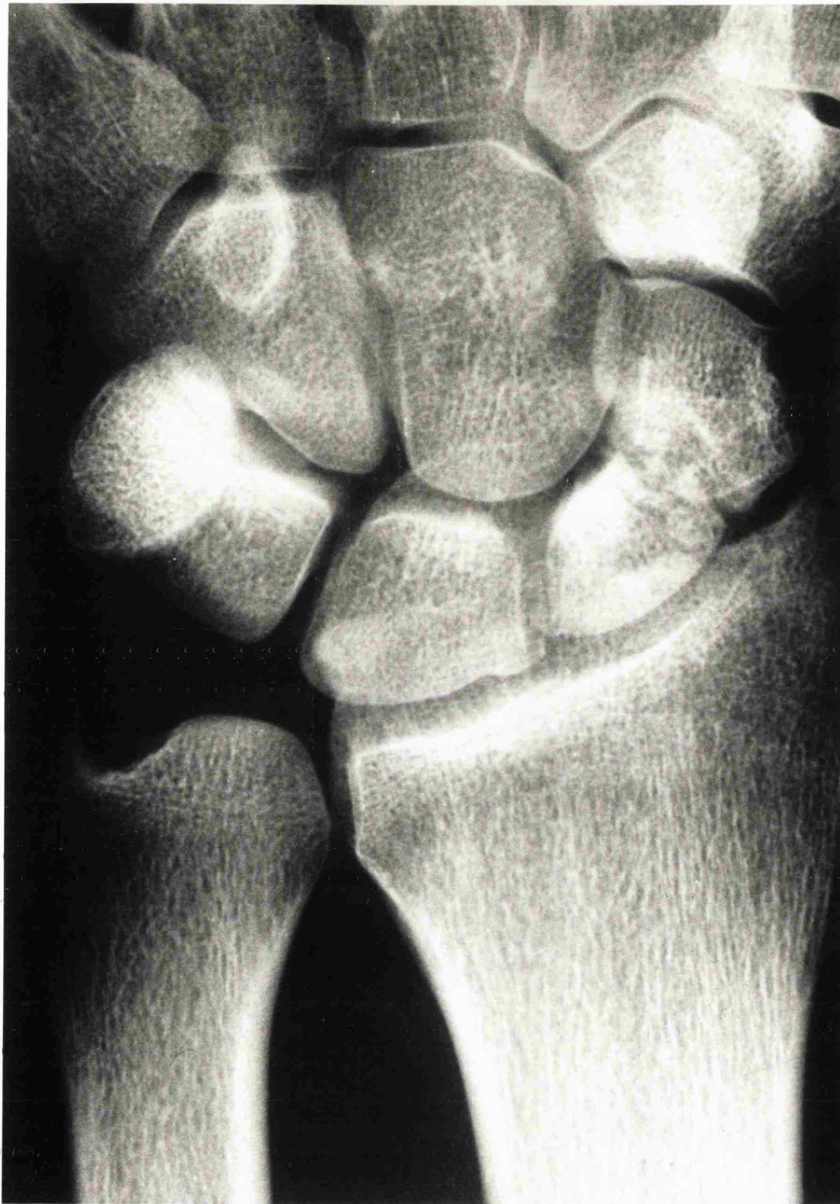The actual incidence of avascular necrosis of the proximal part of the scaphoid was much higher than that suggested by radiological changes within this part of the scaphoid. Histological examination suggested avascularity in over 50 % of non-unions of scaphoid fractures. It is possible that in the remainder mobility at the fracture site is a major factor in the pathogenesis of non-union.

FIGURE 3.9-1



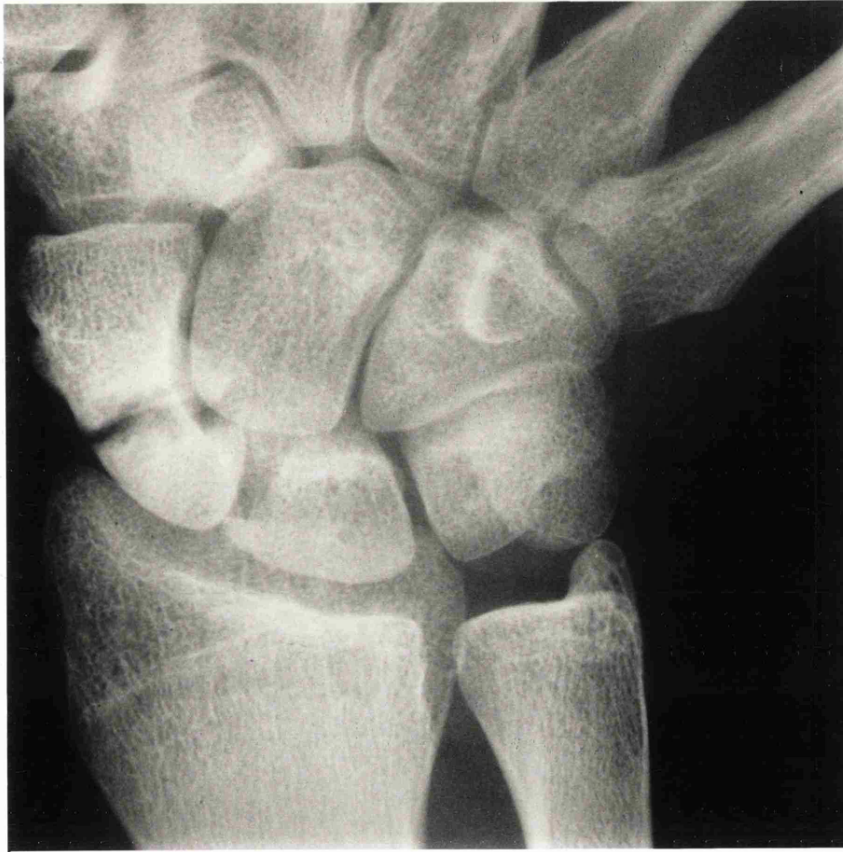A Ziter (1973) view of a normal scaphoid demonstrating that the proximal part of the scaphoid can appear radiologically denser.

FIGURE 3.9-2



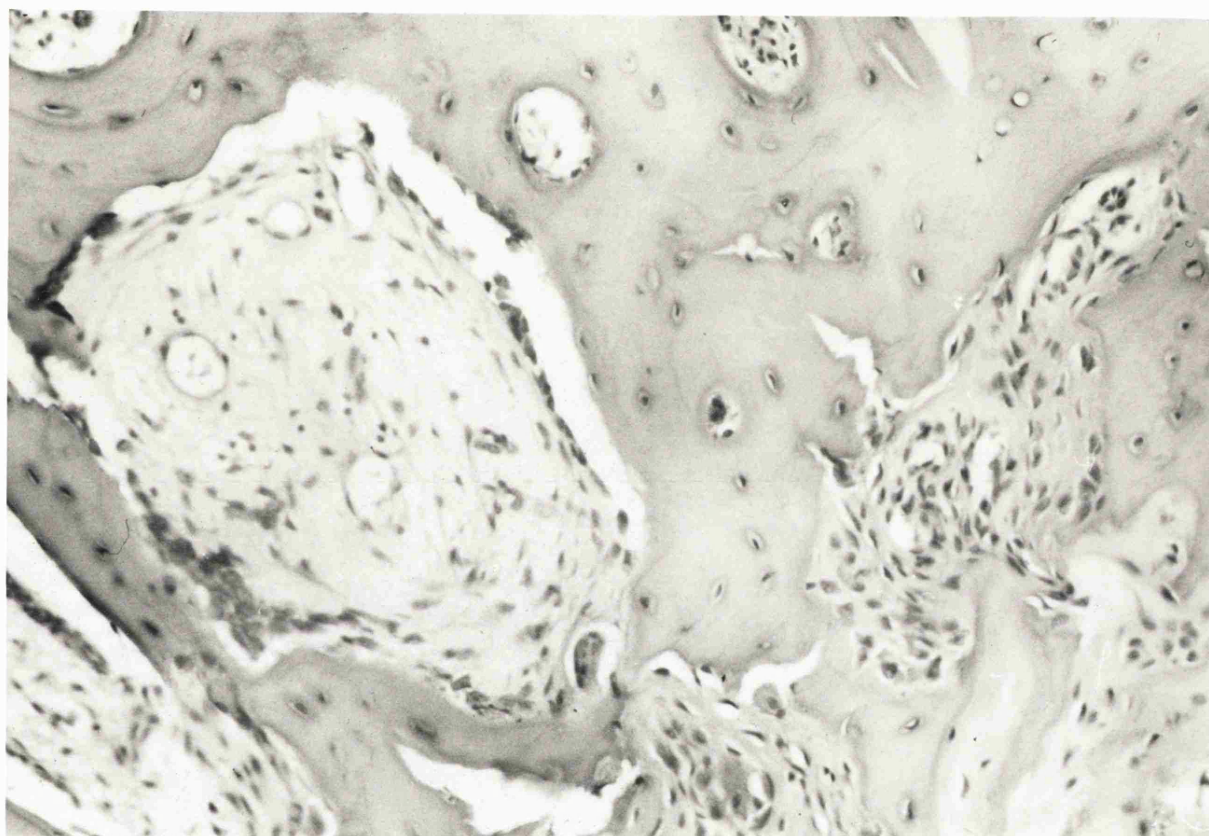
Radiograph of a scaphoid non-union demonstrating definite increased density of the proximal scaphoid.

FIGURE 3.9-3



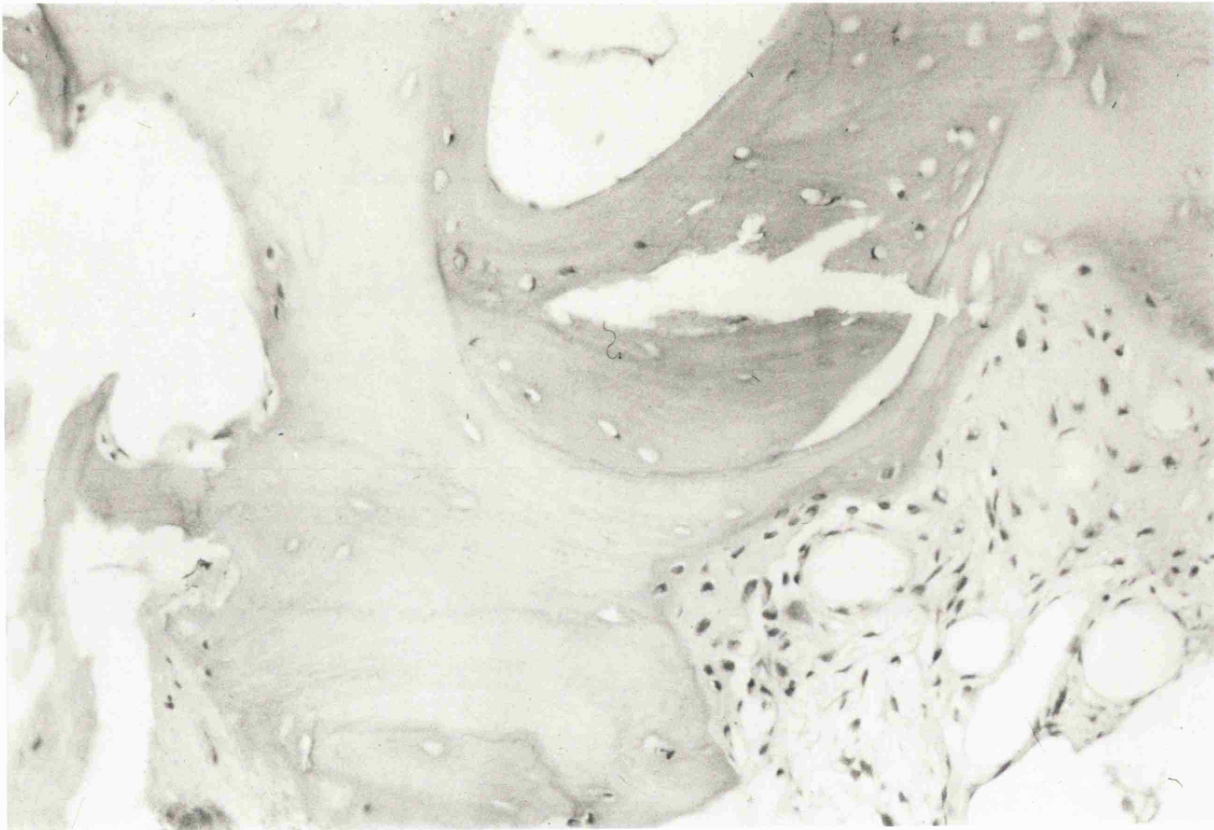
Radiograph of another scaphoid non-union demonstrating possible increased density of the proximal scaphoid.

FIGURE 3.9-4



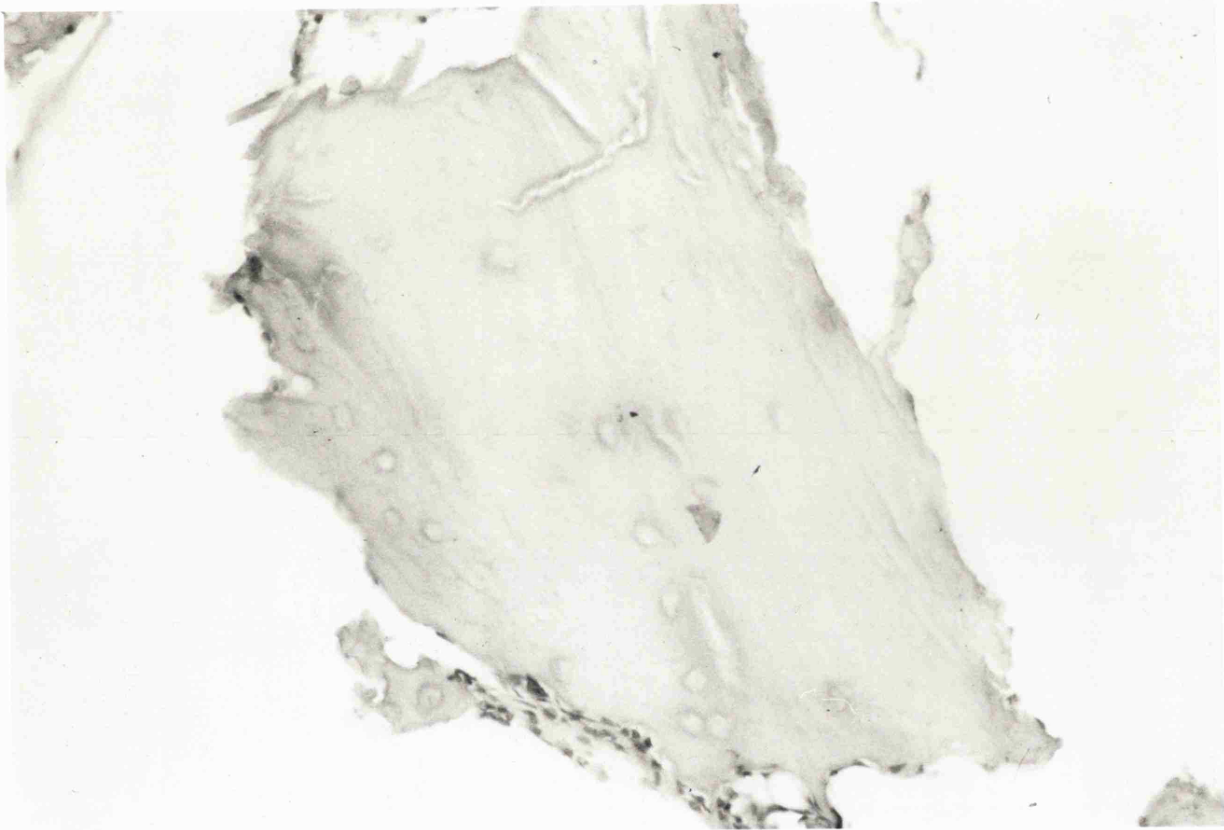
Histological slide of reactive bone demonstrating woven bone, increased number of populated lacunae and cellular marrow spaces.

FIGURE 3.9-5



Histological slide of revascularised bone demonstrating a core of necrotic bone which is layered by woven bone with populated lacunae and shows cellular marrow spaces.

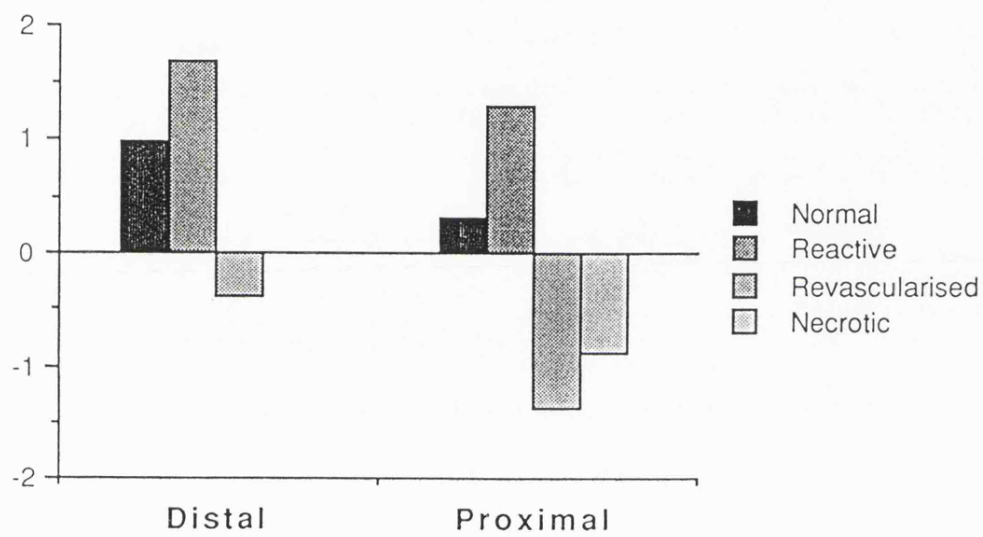
FIGURE 3.9-6



Necrotic bone demonstrated by mature lamellar bone with empty lacunae and no reaction within the marrow spaces.

FIGURE 3.9-7

Scaphoid non-union & avascularity



Histogram of the histological patterns observed in the proximal and distal parts of 20 scaphoid non-unions.

Table 3.9-I : Radiographic vs histological findings

HISTOLOGY				
	Normal	? Avascular	Avascular	TOTAL
<hr/>				
RADIOLOGY				
Normal	6	1	8	15 (78.9%)
? Avascular	0	1	3	4 (21.1%)
Avascular	0	0	0	
<hr/>				
TOTAL	6	2	11	
	(31.6%)	(10.5%)	(57.9%)	

$$\chi^2 = 2.8643, \quad DF = 2, \quad p = 0.2388$$

Table 3.9-II : Clinical findings

	Normal n = 9	Avascular n = 11	p =
Age (yrs)	26.6 (7.1)	26.9 (15.0)	0.960
Follow up (yrs)	2.0 (0.5)	2.5 (2.1)	0.455
Time in cast (wks)	8.7 (6.2)	5.8 (5.0)	0.285
SYMPTOMS			
Sig Pain	3	6	
Stiffness	3	6	
SIGNS			
Tenderness	6	5	
Stress test	7	4	
Weakness	2	4	
Wrist movement	77.7% (10.5)	77.6% (22.2)	0.988
Span difference	3.9mms (6.0)	3.6mms (9.5)	0.943

(Standard deviation) Figures refer to the number of patients with abnormal symptoms or signs unless otherwise stated

SECTION 10

CARPAL INSTABILITY AND SCAPHOID NON-UNION

It has been suggested (Fisk 1970) that if a scaphoid fracture is associated with perilunate ligament damage it is unlikely to unite. This observation has been supported by Monsivais et al (1986) who found that scaphoid fracture non-union was associated with carpal instability. They suggested that those fractures with damaged ligaments were more likely to displace during treatment. Others (Mack et al 1984, Cooney et al 1980) however, noted that a dorsal intercalated segment instability pattern (with the lunate facing backwards) developed with time. The longer the duration of the scaphoid non-union the higher the incidence of carpal malalignment. This has been confirmed recently by Vender et al (1987). All these studies based their conclusions on an increase in the scapho-lunate angle and a change in the capito-lunate and radio-lunate angles measured on a lateral radiograph of the wrist.

The presence of carpal instability was investigated in a consecutive series of patients with scaphoid non-union using clinical assessment, radiographic measurement and assessing the volar scapho-lunate ligament at surgery. In addition the use of real time ultrasonography in assessing scaphoid movement and the movement between the

capitate and lunate and the lunate and radius was studied.

PATIENTS

27 consecutive patients with a scaphoid non-union being considered for surgery were included in the study. Their mean age was 27.4 years (range 16 to 71). twenty four were male and 3 were female. The mean duration since injury was 2.2 years.

METHODS

A: CLINICAL ASSESSMENT

At review the scaphoid was stressed clinically (Watson et al 1986) and the presence of a click and increase in pain and discomfort was noted as mild, moderate or severe. The range of wrist movement (dorsiflexion, palmarflexion, radial and ulnar deviation) was measured using a goniometer. Similar measurements were made on the opposite side.

B: RADIOGRAPHIC ASSESSMENT

In addition to the scaphoid views, a postero-anterior and lateral radiographs of both wrists were obtained ensuring that the wrist was in a neutral position. The carpal alignment was assessed (Linscheid et al 1972) by measuring the capito-lunate, radio-lunate and scapho-lunate angles (Figure 3.10-1). On the postero-anterior radiograph the length of the third metacarpal and the carpal height was measured and

expressed as a ratio of the metacarpal length to carpal height (Youm et al 1978). This assessed the degree of carpal collapse.

C: ULTRASONOGRAPHIC ASSESSMENT OF CARPAL MOVEMENT

Carpal movements were assessed using the 5MHz linear probe of the Acuson 128 ultrasound imaging system. The scaphoid was imaged as described in section 3.7. The wrist was moved from maximum ulnar deviation to maximum radial deviation. In ulnar deviation the scaphoid straightened out while in radial deviation it flexed forwards. Its inclination to the surface reference line was measured in degrees. The difference between the angle of the scaphoid in maximum ulnar deviation and maximum radial deviation gave the range of scaphoid movement.

The capitate, lunate and radius were then imaged. With the forearm supine and the wrist in neutral the hand was placed on the examination table. The probe was placed perpendicular to the wrist and in the long axis of the forearm (Figure 3.10-2). The volar surfaces of the capitate, lunate and radius were thus visualised (Figure 3.10-3). An assistant then stressed the wrist in the antero-posterior direction keeping the wrist and hand parallel to the forearm. The distance of the proximal capitate, most superficial point of the lunate and the distal rim of the radius from the superficial reference line was measured with the wrist stressed in a dorsal

direction and then in the volar direction (Figure 3.10-4). The translation between the radius and the capitate was thus measured. This capito-radius translation was expressed as the difference in millimeters between the injured side and the opposite side.

D: PER-OPERATIVE ASSESSMENT

Two patients refused surgery. Of the remaining 25 the volar scapho-lunate ligament was examined at the time of surgery in 24. The proximal pole of the scaphoid was then stressed dorsally with the flat end of a small punch and the relative movement between the proximal pole of the scaphoid and the lunate was noted as normal or abnormal (greater than approximately 2 millimeters translation).

E: CONTROLS

Finally 31 volunteers (18 men and 13 women, mean age 26.8, range 19 to 41), with no symptoms in the wrist or hand had ultrasonographic assessment of the capitate-lunate radius axis. These 62 wrists formed the controls.

The data was analysed using the SPSS-X program, University of Leicester.

RESULTS

Fourteen of the 27 patients in whom the stress test was

conducted had significant (moderate or severe) pain associated with the test.

A: INJURED WRIST vs OPPOSITE WRIST

Table 3.10-1 demonstrates the comparison between the injured and opposite sides. The range of wrist movement was significantly ($p < 0.001$) less than the opposite side. The scapho-lunate angle had increased from a mean of 48.6 degrees to 55.0 degrees. This change was significant ($p < 0.05$). However, the capito-lunate angle, the radio-lunate angle and the ratio of the metacarpal height to carpal height was similar demonstrating that no carpal collapse had occurred. On ultrasonography, the range of scaphoid movement was significantly less than the opposite scaphoid ($p = 0.05$) but the degree of carpal translation was similar. At surgery, none were found to have disruption of the volar scapho-lunate ligament and in only two patients could the proximal pole be moved more than 2 millimeters in relationship to lunate. Both these patients also had radiological changes suggesting carpal instability with marked increase in both the scapho-lunate angle and radio-lunate angle.

B: ABNORMAL vs NORMAL SCAPHO-LUNATE ANGLE

In order to establish whether patients with an abnormal scapho-lunate angle were different from those without abnormality they were divided into two groups : (1)

those with an increase greater than 10 degrees and (2) those with an increase of less than 10 degrees. Table 3.10-II demonstrates the comparison between these two groups. There was no difference between the two groups for age, range of wrist movement, span and metacarpal to carpal ratio. The capito-lunate angle was significantly increased and the scaphoid movement on ultrasonography was greater in patients with an abnormal scapho-lunate angle. However, the carpal shift and the radio-lunate angle were similar. The change in scapho-lunate angle was matched by a similar change in the capito-lunate angle ($r = 0.78$, $p = 0.000$) and radio-lunate angle ($r = -0.51$, $p = 0.005$). It was not correlated with any change in carpal height ratio ($r = 0.0363$, $p = 0.440$) or ultrasonographic assessment of carpal translation ($r = 0.1342$, $p = 0.292$) or ultrasonographic assessment of scaphoid movement ($r = -0.167$, $p = 0.247$) or the range of wrist movement ($r = -0.1454$, $p = 0.244$).

C: POSITIVE vs NEGATIVE SCAPHOID STRESS TEST

Fourteen of the 27 patients had significant pain on stressing the scaphoid. These patients were compared to those who had no significant discomfort on stressing the scaphoid (Table 3.10-III). While those with a positive test had significant reduction in the range of movement and span, there was no difference in radiological or ultrasonographic carpal parameters. A painful stress test did not appear to be related to carpal instability.

D: PATIENTS vs CONTROLS

In order to assess whether patients with a scaphoid non-union had pre-existing carpal ligament laxity the ultrasonographic assessment of the intercalated segment in these patients was compared with that of the control population. In addition the dominant and non-dominant wrists in the control population were also compared (Table 3.10-IV). The carpal translation on the non-dominant side was comparable to that on the dominant side. Table 3.10-IV also demonstrates that around 75% of carpal translation occurred at the capito-lunate joint. On the dominant side the radio-lunate movement was significantly better than on the non-dominant side. There was no difference in carpal translation in either the injured or contralateral wrist in patients with non-union when compared to the 62 control wrists.

DISCUSSION

Fisk (1970) stated that a co-existing perilunate ligament rupture predisposed the fracture of the waist of the scaphoid to non-union. The scaphoid plays an important role in maintaining the relationship between carpal bones during wrist movement as it bridges the proximal and distal carpal rows. When fractured it ceases to perform this function and carpal malalignment can occur. He suggested that any ligament damage would result in less support for the broken scaphoid and result in failure of union. Monsivais et al (1986) found that patients with non-union had abnormal

antero-posterior mobility of the wrist. They were able to demonstrate a significant increase in the scapho-lunate angle and in the radio-lunate angle as measured on the lateral radiograph. The present study, too, demonstrated a significant overall increase in the scapho-lunate angle (> 10 degrees in 10 patients) when compared to the uninjured wrist and 14 of 27 patients had pain on the scaphoid stress test.

However, this study was unable to confirm significant change in the capito-lunate-radius axis. The carpal height was maintained and the capito-lunate and radio-lunate angles were not significantly different from the contralateral side. Apart from the increase in the scapho-lunate angle we were unable to demonstrate to demonstrate any significant ligamentous instability on radiographs or ultrasonography. The increase in the scapho-lunate angle could be a reflection of the flexion deformity at the non-union. The absence of carpal ligamentous instability was confirmed by the per-operative findings where only two of the 24 patients undergoing surgery had demonstrable movement between the proximal pole of the scaphoid and the lunate. Finally, comparing patients and controls, we could not demonstrate pre-existing carpal laxity in patients who developed a symptomatic non-union of the scaphoid.

The ultrasonographic assessment of scaphoid movement and

carpal translation demonstrated a slight decrease when compared to the contralateral side. This decrease in carpal movements was mirrored by the decrease in the range of wrist movement and span. This was probably the result of the stiffness following the fracture or the consequence of the flexion deformity at the site of the non-union (Burgess 1987).

Patients with a scaphoid fracture non-union reviewed at a mean of 2.2 years after the injury do not appear to have demonstrable ligament laxity. It has been noted (Mack et al 1984, Cooney et al 1980) that carpal instability pattern develops gradually, with the lunate tilting progressively to assume the dorsal intercalated segment instability (DISI) alignment. The present study lends support to this observation. We suggest that there is progressive volar collapse at the fracture site leading to flexion of the distal pole on the proximal pole of the scaphoid. This promotes a progressive carpal collapse. Indeed, Vender et al (1987) found that the pattern of degenerative arthritis in symptomatic non-union was similar to that seen in a scapho-lunate advanced collapse (SLAC) wrist.

CONCLUSION

Although the carpal alignment had changed in a third of the patients this study was unable to demonstrate ligament laxity in association with a scaphoid non-union. In addition, a non-invasive method of

assessing carpal movement using ultrasonography has been described.

**Table 3.10-I : Carpal instability & scaphoid fracture
non-union : Injured vs opposite side**

	Non-union	Opposite	p =
<hr/>			
Range of movement :			
Dorsiflexion	45.9 (15.0)	64.0 (11.2)	0.000
Palmarflexion	55.3 (12.0)	67.7 (9.1)	0.000
Radial deviation	17.5 (6.2)	26.2 (8.7)	0.000
Ulnar deviation	26.8 (6.1)	33.8 (8.1)	0.001
<hr/>			
Radiographic assessment			
Scapho-lunate angle	55.0 (10.7)	48.6 (7.6)	0.041
Capito-lunate angle	-2.3 (7.8)	-5.1 (8.8)	0.604
Radio-lunate angle	-15.6 (14.9)	-14.1 (10.7)	0.713
MC / C ratio	0.50 (0.03)	0.51 (0.03)	0.379
<hr/>			
Ultrasonographic assessment			
Scaphoid movement	9.3 (4.9)	12.4 (4.9)	0.050
Carpal translation	3.7 (2.5)	4.6 (7.6)	0.188
<hr/>			

Table 3.10-II : Abnormal scapho-lunate angle vs normal scapho-lunate angle

	Abnormal SL	Normal SL	p =
Age	27.8 (8.8)	27.2 (13.8)	0.886
Range of movement	76.4 (13.4)	79.7 (20.1)	0.631
Span	3.0 (5.4)	5.0 (8.7)	0.484
Radiographic assessment			
Scapho-lunate angle	17.6 (6.0)	0.6 (9.0)	0.000
Capito-lunate angle	-15.1 (14.7)	4.5 (17.0)	0.006
Radio-lunate angle	4.8 (17.2)	-0.7 (14.6)	0.425
MC / C ratio	0.51 (0.03)	0.50 (0.03)	0.699
Ultrasonographic assessment			
Scaphoid movement	5.6 (3.0)	1.8 (5.0)	0.050
Carpal translation	1.1 (3.0)	1.1 (3.0)	0.994

Table 3.10-III : Abnormal stress test vs normal stress test

	Abnormal	Normal	p =
Age	28.0 (14.0)	26.8 (8.5)	0.802
Range of movement	70.6 (13.0)	85.6 (17.8)	0.021
Span	7.1 (5.1)	1.2 (8.2)	0.035
Radiographic assessment			
Scapho-lunate angle	8.2 (13.6)	5.1 (10.3)	0.527
Capito-lunate angle	5.8 (22.3)	-0.6 (14.1)	0.496
Radio-lunate angle	2.4 (19.4)	-0.5 (10.8)	0.768
MC / C ratio	0.50 (0.04)	0.50 (0.02)	0.819
Ultrasonographic assessment			
Scaphoid movement	2.8 (5.1)	3.3 (4.2)	0.814
Carpal translation	0.9 (2.8)	1.0 (2.5)	0.938

Table 3.10-IV : Controls (n=62) :

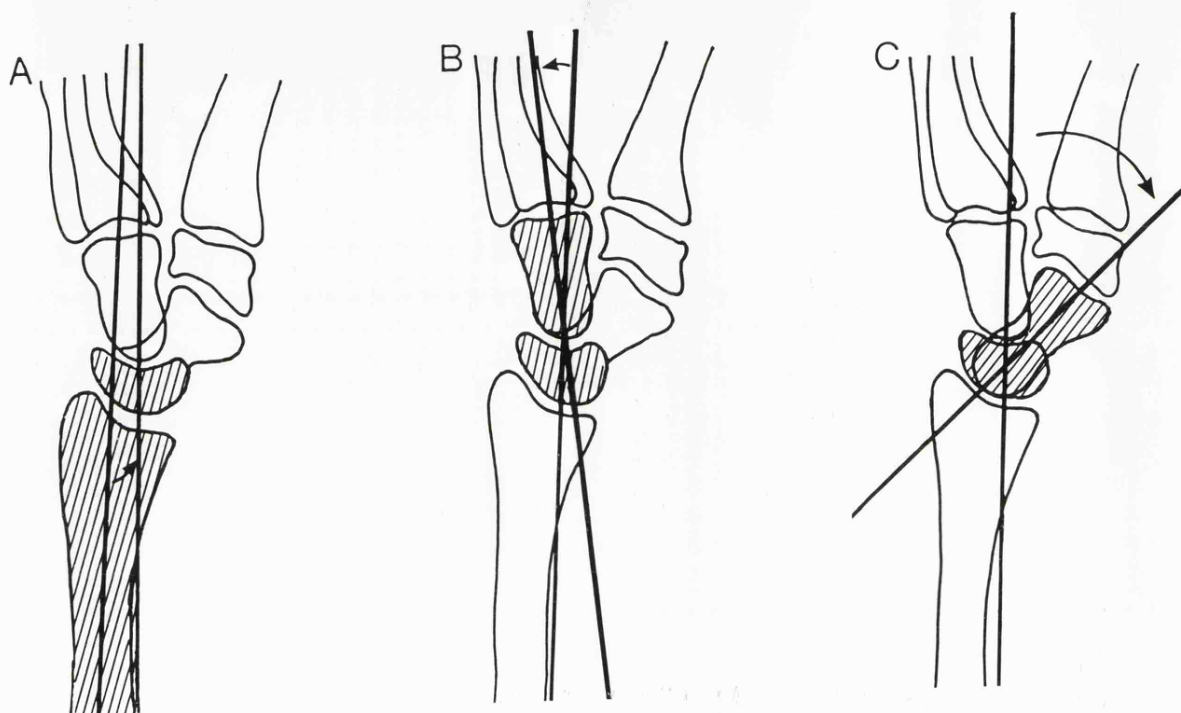
A: Dominant vs non-dominant sides

	Dominant	Non-dominant	p =
Carpal translation	4.2 (2.1)	3.4 (2.3)	0.203
R-L translation	1.1 (1.2)	0.1 (1.2)	0.002
C-L translation	3.1 (2.1)	3.4 (1.9)	0.574

B: Patients vs controls

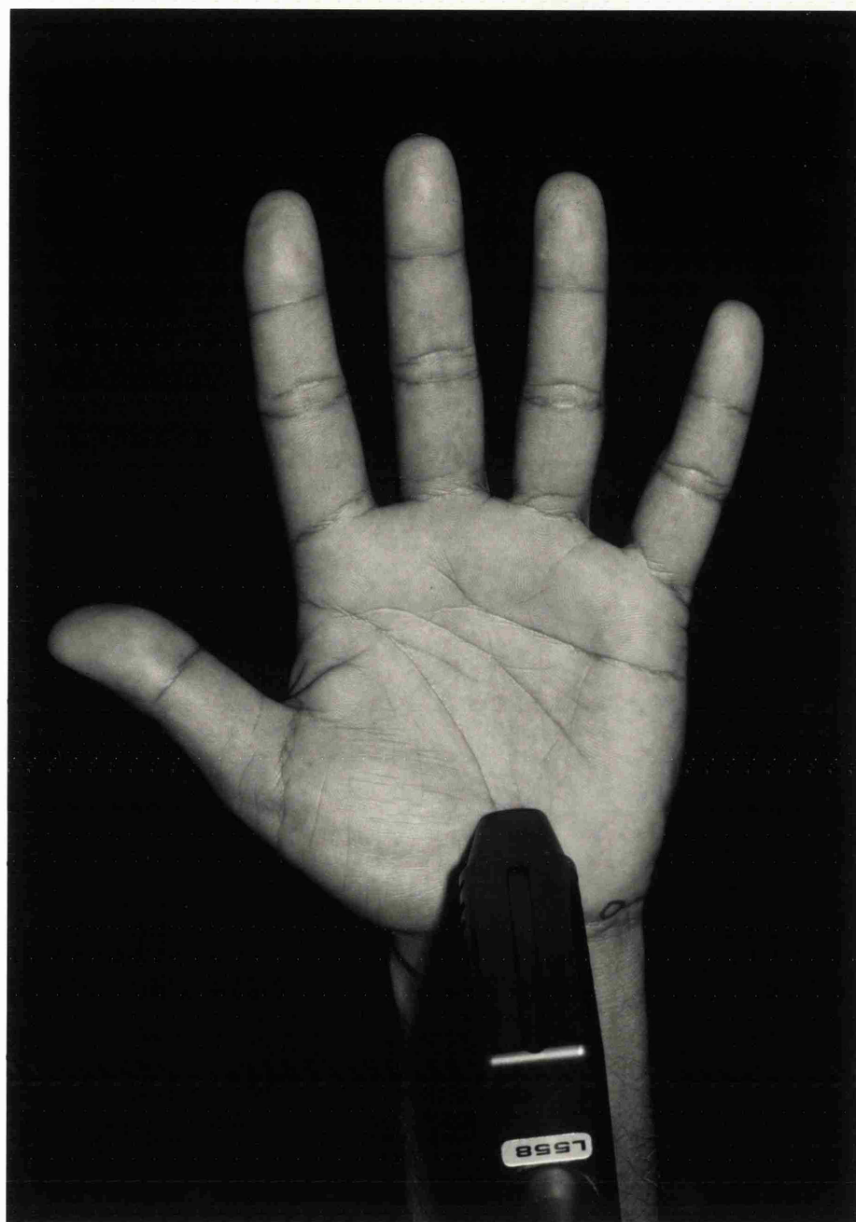
Carpal translation :	Patients	Controls	p =
Opposite side	4.6 (2.1)	3.8 (2.2)	0.136
Non-union side	3.7 (2.5)	3.8 (2.2)	0.851

FIGURE 3.10-1 : Radiographic measurement of carpal instability



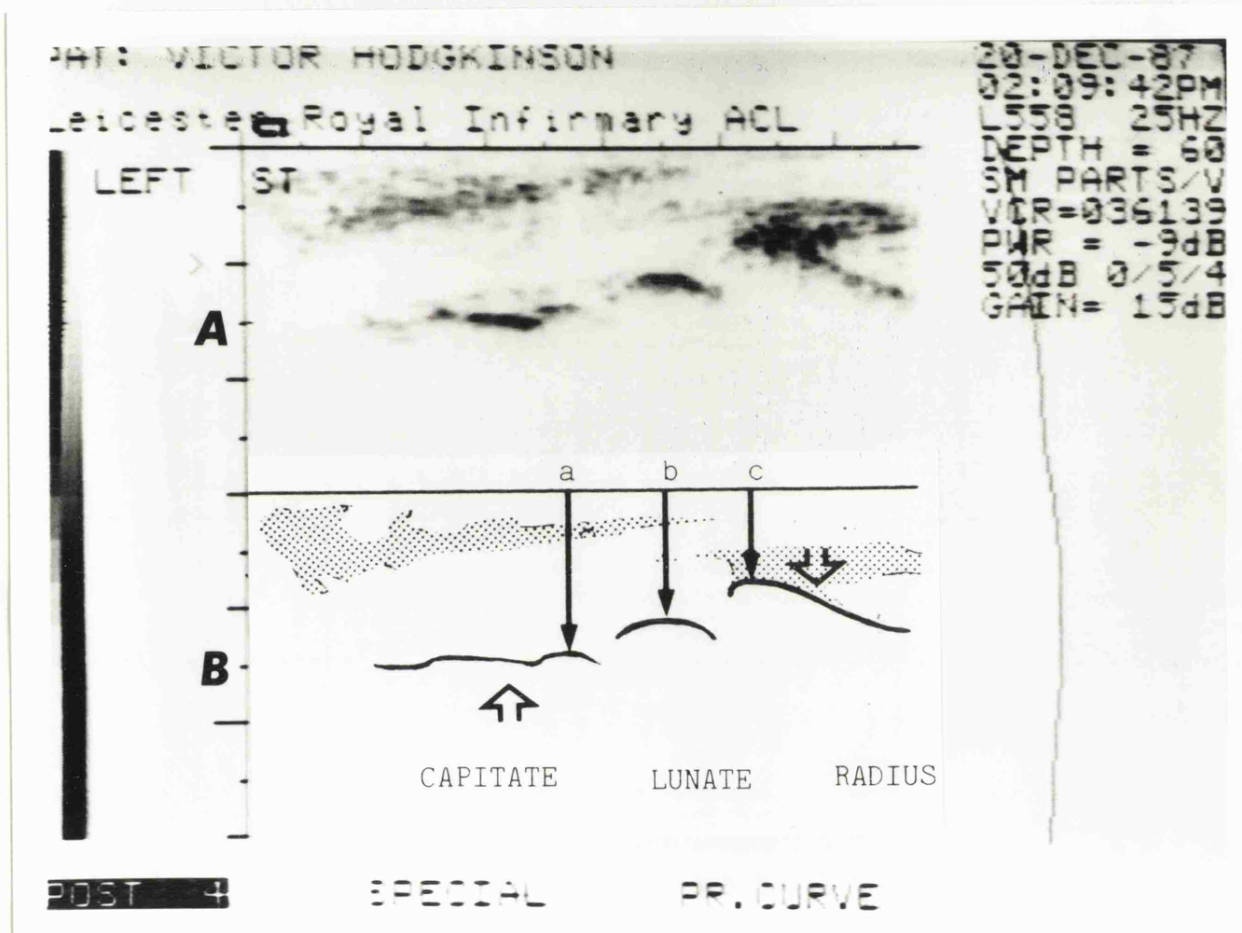
The diagram illustrates the measurement of (A) the radio-lunate angle, (B) the capito-lunate angle and (C) the scapholunate angle. After Linscheid et al 1980.

FIGURE 3.10-2 : The position of the probe



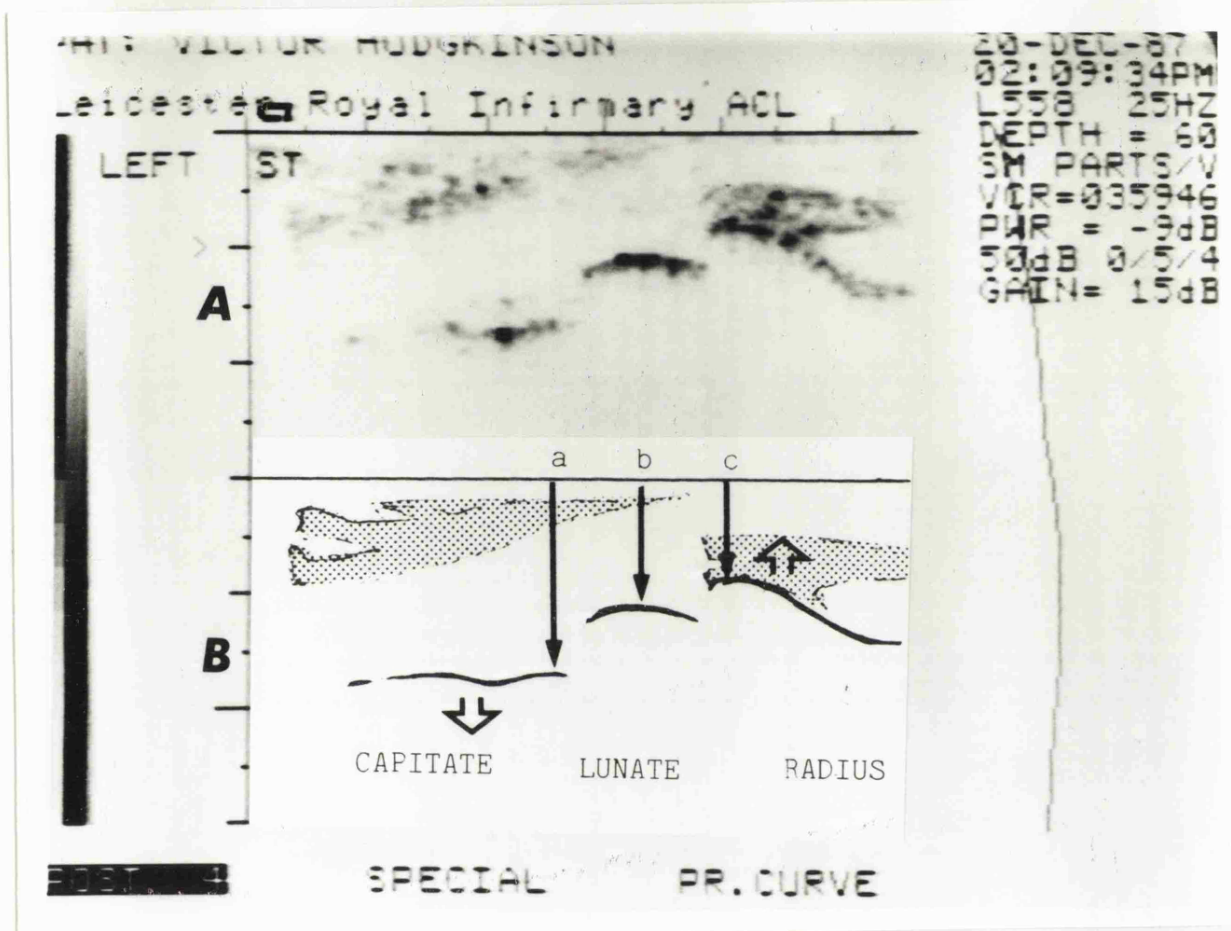
The 5MHz linear probe is shown placed across the wrist and lying parallel to the forearm.

FIGURE 3.10-3 : Ultrasonographic assessment of the central column with the wrist stressed in a volar direction.



The Ultrasonographic appearance of the central column (A) with the explanatory diagram (B). The open arrows indicate the direction of displacement. The three arrows (a,b,c) represent the position of each bone from the surface reference line. In volar displacement the three bones lie a comparable distance from the surface.

FIGURE 3.10-4 : Ultrasonographic assessment of the central column with the wrist stressed in a dorsal direction.



The Ultrasonographic appearance of the central column (A) with the explanatory diagram (B). The open arrows indicate the direction of displacement. The three arrows (a,b,c) represent the position of each bone from the surface reference line. In dorsal displacement the capitate is shifted further back from the surface.

Section 4

Discussion

SECTION 4.1

DISCUSSION

The management of fractures of the waist of the scaphoid has been beset with controversy. The primary reason for this is that inadequate treatment may result in non-union of the fracture.

A: EARLY DIAGNOSIS

Previous studies (Bohler et al 1954) established that scaphoid fractures which were not immobilised were more likely to develop a non-union. This, coupled with the medico-legal implications, has led to great effort being spent on demonstrating the fracture in an injured wrist. The assumption has been made that radiographs provide objective assessment of the injured scaphoid by demonstrating the fracture in at least one of the four usual views and that the absence of soft tissue signs could confidently exclude a fracture.

It has been demonstrated that soft tissue swelling was not invariably associated with a fracture and conversely, if the imaging technique was inappropriate or if the injured wrist was radiographed before swelling has occurred, no abnormality might be seen even if a fracture was present. False negative results occurred in

approximately one in four patients while approximately a third of patients with abnormal soft tissue signs did not have any bony injury. One could not, therefore, rely on soft tissue signs to establish the diagnosis of a scaphoid fracture or, indeed, to exclude it.

In patients in whom the fracture was not immediately obvious the recommendation has been to immobilise the wrist and obtain radiographs after an interval of around two weeks. However, it has been demonstrated that the interpretation of radiographs obtained immediately after injury and at two weeks after injury was observer dependant and that this observation was not uniformly reproducible. The accuracy of interpretation of these radiographs was independent of the experience or seniority of the observer. Moreover, lines in the normal scaphoid could be mis-interpreted as fractures. These observations seriously questioned the value of repeat radiographs in conclusively demonstrating whether or not the scaphoid was fractured.

Most fractures were seen easily on the Ziter (1973) view as well as the standard postero-anterior view. The need for multiple radiographic views in the initial assessment of an injured scaphoid was questioned in section 3.2.

It therefore appeared that radiography of the acute scaphoid injury did not, as hitherto believed, provide

objective assessment and should not influence early management. Management decisions should be based on a careful clinical assessment of the injured wrist. Todd (1921) described the clinical findings when the scaphoid was fractured. These included :

1. Swelling in the anatomical snuff box and in the dorsum of the wrist.
2. Marked tenderness in the anatomical snuff box.
3. Pain in this region on pressure applied over the scaphoid tuberosity.
4. Pain in this region produced by clenching the fist or putting axial pressure along the second metacarpal.

It is suggested that the protocol demonstrated in figure 4.1-1 would provide adequate management of the acute injury. This protocol is based on the assumption that early immobilisation favourably influences the outcome with regard to bony union.

B: IMMOBILISATION

Once the diagnosis of a scaphoid fracture has been established the wrist needs to be immobilised. It has been demonstrated that scaphoid fractures heal equally well in a below elbow cast which did not include the thumb as not only does thumb immobilisation not appear to influence the outcome with regard to fracture union but it could be a positive disadvantage in that it could

make the cast more difficult to apply and slightly more expensive.

Using a cast with the wrist in slight dorsiflexion and the thumb free enabled the patient to use the hand in everyday activities. It was noticed in the prospective study on scaphoid cast versus Colles' cast that patients with unsatisfactory casts were more likely to develop a non-union. The use of modern resin impregnated casts which are very strong should ensure that the cast does not deteriorate with use. Heavy use such as that of a heavy manual labourer should, however, be discouraged.

C: DIAGNOSIS OF UNION

The incidence of non union reported in literature varies from 5% to as high as 25%. Herbert & Fisher (1984) suggest that it may be even higher (approaching 50%). Most of these studies based the diagnosis of union on radiographs obtained at or before 12 weeks following injury.

Radiographs taken at this interval were not found to be reliable. There was considerable disagreement between eight consultant observers as to whether 20 fractures of the waist of the scaphoid had united based on the presence of trabeculae crossing the fracture line or sclerosis at the fracture line on at least four views of the scaphoid. In addition, two months later, these observers were unable to consistently reproduce their

own initial observations as to whether or not the fracture had united.

Is there any other method of assessing scaphoid union ?. As the only reliable assessment would involve demonstrating movement at the fracture site the use of real time ultrasound scanning in 27 patients listed for Russe grafting of a scaphoid nonunion was investigated. Using a 5MHz linear probe of the Acuson 128 ultrasound machine unequivocal movement at the fracture site was demonstrated in 19 patients which was confirmed at surgery. In six patients no movement could be demonstrated at the fracture site; two of these had partial dorsal union while three had a proximal pole fracture which is difficult to demonstrate on ultrasonography. It would appear that the so called 'strong fibrous union' is an uncommon occurrence following scaphoid waist fractures. The use of this technique to establish whether there is movement at the fracture site after a period of immobilisation is strongly recommended.

If there is any doubt regarding the state of union of the scaphoid fracture after a period in a plaster cast (either marked tenderness in the anatomical snuff box or dubious radiographic appearances) the scaphoid should be assessed using ultrasonography. Surgery to internally fix and bone graft a 'delayed' union can be confidently

recommended if unequivocal movement can be demonstrated at the fracture site. If such movement cannot be demonstrated it is probably wiser to immobilise the wrist in a splint for a further period of around 4 weeks. This protocol is outlined in figure 4.1-2.

C: PATTERNS OF UNION

The unreliability of radiographic evidence of union described in section 3.5 questioned the commonly accepted 5% incidence of non-union following this injury. The incidence of non-union of fractures of the waist of the scaphoid, defined as the presence of a clear gap at the fracture site one year after injury (Maudsley & Chen 1972) was unknown.

Of 82 patients who had sustained a fresh fracture of the waist of the scaphoid in 1985 who were reviewed over one year after injury, 10 patients (12.3%) had a nonunion. Almost all were symptomatic at review but only half had significant local tenderness or restriction of wrist movement. These patients were in their twenties with a marked male preponderance (M:F 9:1). In addition to the 10 patients with a non union and the 52 in whom the fracture had united, a third clinically distinct group (25% of the patients) was demonstrated. In these patients the site of the fracture could be easily identified at review although a definite non union could

not be demonstrated on five radiographic views. These patients were a decade older (mean age 39 years vs 26 years for the united and ununited groups) and there were proportionately more females (M:F 2:1). In spite of the fracture having probably united 75% had wrist pain on activity and a third had appreciable weakness of grip strength with recognisable degenerative changes in the radio-scaphoid joint. There was, however, no significant wrist stiffness. These patterns of union were confirmed by the results of the prospective study.

These studies established that the injured wrist could be symptomatic even if the fracture had probably united. In a small number this was related to some displacement at the fracture site. In others it probably represented injury to the articular lining and surrounding soft tissues at the time of injury.

D: AVASCULARITY & INSTABILITY AND SCAPHOID NON-UNION

Finally, two factors previously implicated in the occurrence of non-union following scaphoid waist fractures were investigated : (1) carpal instability and (2) proximal pole avascularity.

Carpal instability was assessed on (1) lateral radiographs, (2) real time ultrasound scans and (3) at surgery the condition of the volar scapho-lunate ligament was noted. A consistent pattern of increased

laxity between the scaphoid and the lunate in comparison to the contralateral uninjured wrist and in comparison to controls could not be established.

Avascular necrosis was assessed on (1) radiographs and (2) histological examination of bone curretted from the (a) proximal pole of the scaphoid, (b) distal pole and (c) distal radius cancellous bone donor site. Although only 4 of the 20 patients had some radiographic evidence of avascular necrosis a large proportion (68.4%) had histological evidence of osteonecrosis of the proximal pole. However, most of these also had evidence of new bone laid down on dead bone. This suggested some revascularisation of the proximal pole even when a non-union was present.

FIGURE 4.1-1 : Management of the acute scaphoid injury

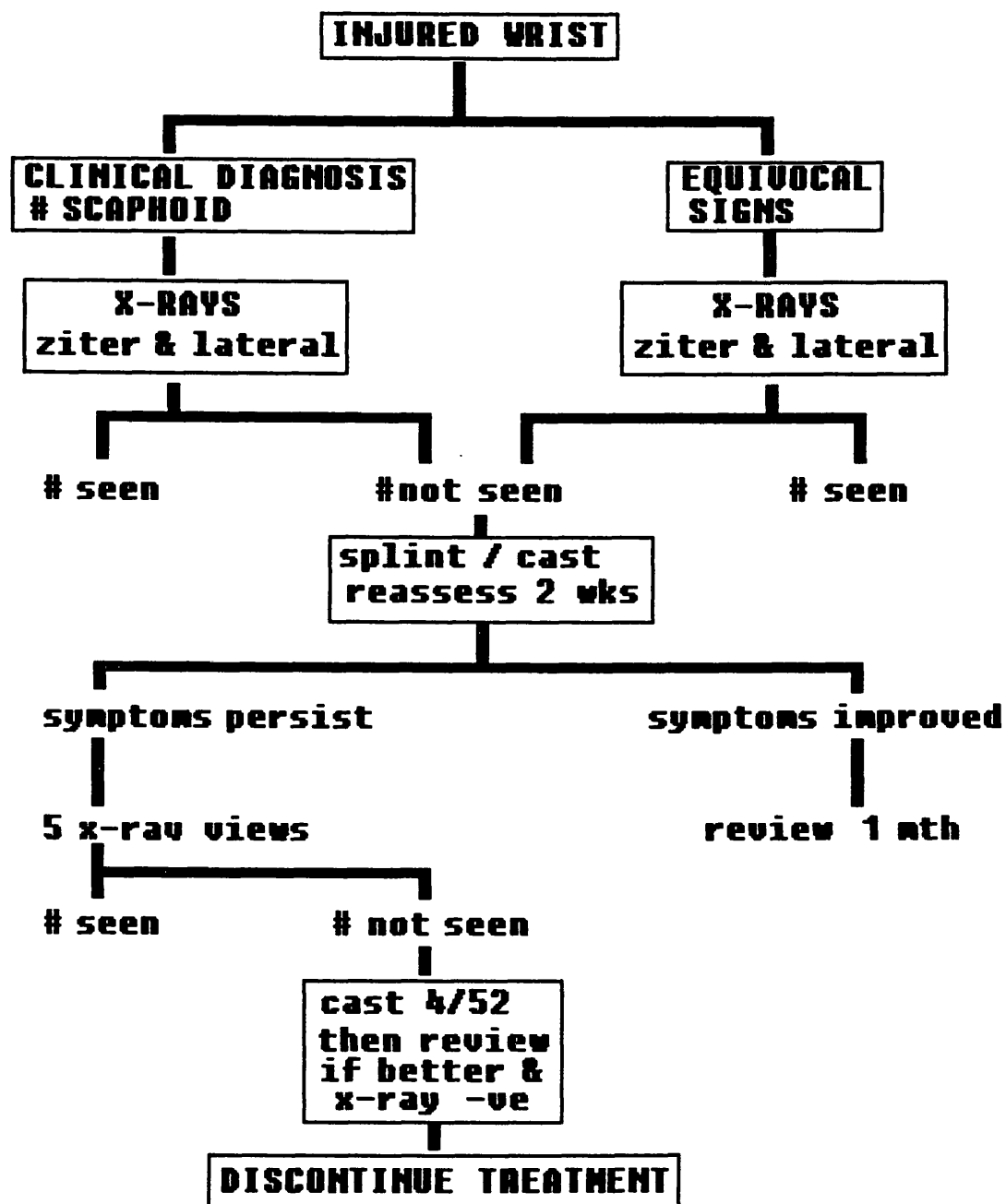
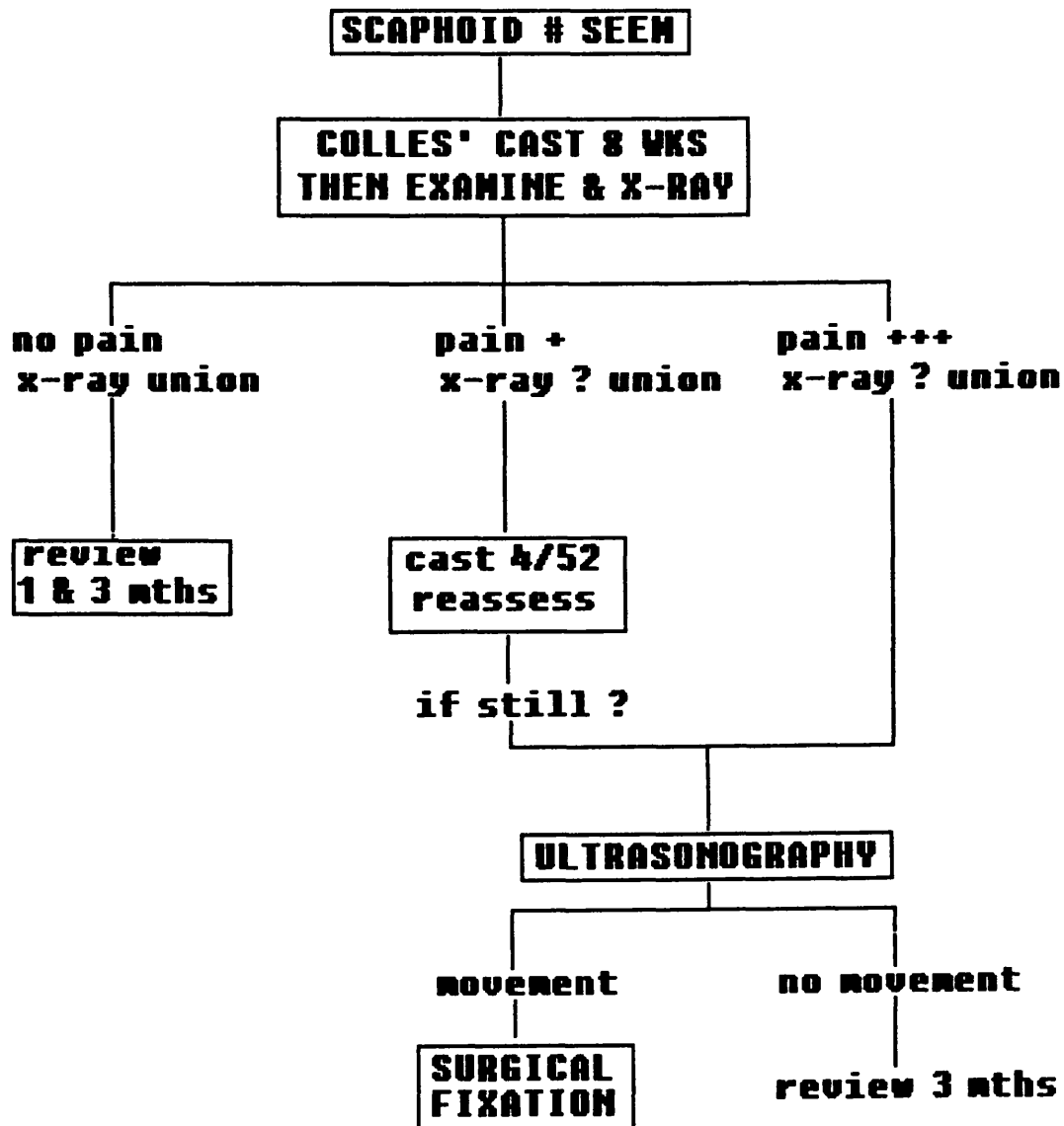


FIGURE 4.1-2 : Management of the fractured scaphoid



SECTION 4.2

CONCLUSIONS

1. Normal soft tissue signs did not exclude the possibility of a scaphoid fracture. Abnormal signs did not always indicate a scaphoid fracture.

2. Initial and 2-3 week radiographs of a clinical scaphoid injury did not provide reliable or reproducible evidence of a scaphoid fracture and could not be relied on either to detect or to rule out a scaphoid fracture. Normal radiographs could be mistakenly interpreted as representing a fracture.

3. The Ziter view and the lateral view of the injured scaphoid provided adequate initial radiographic assessment of a clinically suspected scaphoid fracture.

4. Scaphoid fractures healed equally well in a cast that did not include the thumb. The level of activity while in the cast and the condition of the cast could both adversely influence the outcome.

5. Radiographs obtained 12 weeks after injury could not be used reliably and reproducibly to assess union of a

fractured scaphoid.

6. The incidence of non-union was 12.3% and most of these patients were symptomatic and had restriction of wrist movement. A further 25% of patients, in whom the fracture site could be easily identified over one year after injury, continued to have symptoms and weakness but did not have restriction of wrist movement.

7. A method of assessing movement at the fracture site in scaphoid waist fractures using real time linear ultrasonography which is non invasive and repeatable was established.

8. The actual incidence of avascular necrosis of the proximal part of the scaphoid was much higher than that suggested by radiological changes within this part of the scaphoid.

Based on these observations a rational approach to the management of the injured scaphoid (figure 4.1-1 & figure 4.1-2) is suggested.

Section 5

References

SECTION 5.1

REFERENCES

Adams J D, Leonard R D. Fracture of the carpal scaphoid. A new method of treatment with a report of one case. N Eng J Med 1928; 198:401-404.

Agerholm J C, Lee M L H. The acrylic scaphoid prosthesis in the treatment of the ununited carpal scaphoid fracture. Acta Orthop Scand 1966; 37:67-76.

Aghasi M, Rzetelni V, Axer A. Osteochondritis dissecans of the carpal scaphoid. J Hand Surg 1981; 6:351-352.

Alho A, Kankaanpaa J. Management of fractured scaphoid bone. A prospective study of 100 cases. Acta Orthop Scand 1975; 46:737-743.

Barber H M. Acrylic scaphoid prostheses: A long term follow up. Proc Roy Soc Med 1974; 67:1075-1080.

Barnard L, Stubbins S G. Styloidectomy of the radius in the surgical treatment of non-union of the carpal navicular. J Bone Joint Surg 1948; 30A: 98-102.

Barr J S, Elliston W A, Musnick H, Delorme T L, Hanelin

J, Thibodeau A A. Fracture of the carpal navicular (scaphoid) bone. An end-result study in military personnel. J Bone Joint Surg 1953; 35A: 609-625.

Bedford A F, Glasgow M M, Wilson J N. Ultrasonic assessment of fractures and its use in the diagnosis of the suspected scaphoid fracture. Injury 1982; 14 : 180-182.

Bentzon P G K, Madsen A R. Operativ behandling af invetererede frakturer af os naviculare carpi. Nord Med 1944; 21:524-527.

Bentzon P G K, Madsen A. On fracture of the carpal scaphoid: A method for operative treatment of inveterate fractures. Acta Orthop Scand 1945; 16:30-39.

Berger R A, Blair W F, Crowninshield R D, Flatt A E. The scapholunate ligament. J Hand Surg 1982; 7 : 87-91.

Berlin D. Position in the treatment of fracture of the carpal scaphoid. New Eng J Med 1929; 201 : 574-579.

Birmingham Revision of the Basle Nomina Anatomica (Anatomical society of Great Britain and Ireland) University press, Glasgow, 1933.

Bogart F B. Variations of the bones of the wrist. Am J Roentgenol 1932; 28: 638-646.

Bohler L, Trojan E, Jahna H. Behandlungsergebnisse von 734 frischen einfachen Bruchten des Kahnbeinkorpers der Hand. Reconstr Surg Traumatol. 1954; 2 : 86-111.

Bora F W, Osterman A L, Brighton C T. The electrical treatment of scaphoid nonunion. Clin Orthop 1981; 161:33-38.

Brash J C, Jamieson E B. Cunningham's text book of anatomy. 8th ed. Oxford University Press. New York, 1943.

Broome A, Cedell C A, Colleen S. High plaster immobilisation for fracture of the carpal scaphoid bone. Acta Chir Scand 1964; 128:42-44

Brown P E, Dameron T B. Surgical treatment for nonunion of the scaphoid. Southern Med J 1975; 68 : 415-421.

Bryce T H. On certain points in the anatomy and mechanism of the wrist joint reviewed in the light of a series of roentgen ray photographs of the living hand. J Anat 1896; 31:59-79.

Burgess R C. The effect of rotatory subluxation of the scaphoid on radioscapoid contact. J Hand Surg 1987; 12A:771-774.

Burgess R C. The effect of a simulated scaphoid malunion on wrist motion. J Hand Surg 1987; 12A:774-776.

Burnett J H. Fracture of the (navicular) carpal scaphoid. N Engl J Med 1934; 211:56-60.

Burnett J H. Further observations on treatment of fracture of the carpal scaphoid (navicular). J Bone Joint Surg 1937; 19:1099-1109.

Callander. Fracture of the carpal end of the radius, and of the scaphoid bone. Trans Path Soc London 1866; 17 : 221-222.

Carver R A, Barrington N A. Soft tissue changes accompanying recent scaphoid injuries. Clin Radiol 1985; 36 : 423-425.

Cave E F. The carpus, with reference to the fractured navicular bone. Arch Surg 1940; 40:54-76.

Cetti R, Christensen S E. The diagnostic value of displacement of the fat stripe in fracture of the scaphoid bone. The Hand 1982; 14 : 75-79.

Childress H M. Fracture of a bipartite carpal navicular. Report of a case. J Bone Joint Surg 1943; 25:446-447.

Cleveland M. Fractures of the carpal scaphoid. Surg

Gynecol Obstet 1947; 84 : 769.

Cobey M C, White R K. An operation for non-union of fractures of the carpal navicular. J Bone Joint Surg 1946; 28: 757-764.

Codman E A, Chase H M. The diagnosis and treatment of fracture of the carpal scaphoid and dislocation of the semilunar bone. Ann Surg 1905; 41:321-362.

Cooney W P, Dobyns J H, Linscheid R L. Fractures of the scaphoid : a rational approach to management. Clin Orthop 1980; 149:90-97.

Cooney W P, Dobyns J H, Linscheid R L. Nonunion of the scaphoid : Analysis of the results from bone grafting. J Hand Surg. 1980; 5A : 343-353.

Cohen J. Weighted Kappa : Nominal scale agreement with provision for scaled disagreement or partial credit. Psychol Bull. 1968; 70 : 213-220.

Corson E R. An x-ray study of the normal movements of the carpal bones and wrist. Proc Assoc Am Anat 1898; 11-17.

Cravener E K, McElroy D G. Fractures of the carpal (navicular) scaphoid. Am J Surg 1939; 44 : 100-107.

Curtis D J, Downey E F, Brower A C, Cruess D F, Herrington W T, Ghaed N. Importance of soft-tissue evaluation in hand and wrist trauma : statistical evaluation. Am J Roentgenol 1984; 142: 781-788.

DaCruz D J, Bodiwala G G, Finlay D B L. The suspected fracture of the scaphoid : a rational approach to diagnosis. Injury 1988; 19 : 149-152.

DaCruz D J, Harris A, Jones J M. Haemorrhagic Traumatic Tenosynovitis - a new pathology. J Hand Surg. 1986; 11 : 223-224.

Decoulx P, Razemon J P, Lemerle P. Les fractures et pseudarthroses du scaphoide carpien. A propos de 56 cas. Lille Chir 1959; 14:113-133.

Dehne E, Deffer P A, Feighney R E. Patho mechanics of the fracture of the carpal navicular. J Trauma 1964; 4: 96-114.

Destot E. The classic : Injuries of the wrist : A radiological study. Clin Orth. 1986; 202 : 3-11.

Dias J J, Brenkel I J, Finlay D B L. Patterns of union in fractures of the waist of the scaphoid. J Bone Joint Surg 1989; 71 b: 307-310.

Dias J J, Finlay D B L, Brenkel I J, Gregg P J.

Radiographic assessment of soft tissue signs in clinically suspected scaphoid fractures : the incidence of false negative and false positive results. J Orthop Trauma. 1987; 1 (3) : 205-208.

Dias J J, Taylor M, Thompson J, Brenkel I J, Gregg P J. The radiological signs of scaphoid fracture union : An analysis of inter-observer agreement and reproducibility. J Bone Joint Surg 1988; 70B : 299-301.

Dias J J, Wray C C, Jones J M, Gregg P J. The value of early mobilisation in the treatment of Colles' fractures. J Bone Joint Surg 1987; 69B : 463-467.

Dickison J C, Shannon J G. Fractures of the carpal scaphoid in the Canadian army. Surg Gynecol Obstet 1944; 79: 225-239.

Dobyns J H, Linscheid R L. Fractures and dislocations of the wrist. p 454-466. In Rockwood C A Jr, Green D P (Eds) : Fractures in adults. Vol 2. J B Lippincott Co, Philadelphia, 1984.

Dooley B J. Inlay bone grafting for non-union of the scaphoid bone by the anterior approach. J Bone Joint Surg 1968; 50B: 102-109.

Duben W, Gelbke H. The conservative treatment of the pseudarthrosis of the os naviculare of the hand. Acta

Orthop Scand 1956; 26:25-32.

Duncan D S, Thurston A J. Clinical fracture of the carpal scaphoid - An illusionary diagnosis. J Hand Surg. 1985; 10-B (3) : 375-376.

Dunn A W. Fractures and dislocations of the carpus. Surg Clin North Am 1972; 52:1513-1538.

Dwyer F C. Excision of the carpal scaphoid for ununited fracture. J Bone Joint Surg 1949; 31B: 572-577.

Eddeland A, Eiken O, Hellgren E, Ohlsson N M. Fractures of the scaphoid. Scand J Plast Reconstr Surg 1975; 9:234-239.

Edelstein J M. Treatment of ununited fractures of the carpal navicular. J Bone Joint Surg 1939; 21: 902-908.

Farquharson E L. A splint for fracture of the carpal navicular. J Bone Joint Surg 1942; 24 : 922-924.

Fisk G R. Carpal instability and the fractured scaphoid. Ann Roy Coll Surg Eng 1970; 46 : 63-76.

Fisk G R. Injuries of the wrist. p 716-726. In Watson Jones Fractures and Joint Injuries. J N Wilson (Editor). 6th Edition; Vol 2. Churchill Livingstone, Edinburgh,

1982.

Freedman A M, Kaplan H I, Sadock B J (Editors).
Comprehensive Textbook of Psychiatry. 2nd edition.
Williams & Wilkins, Baltimore, 1975.

Ganel A, Engel J, Oster Z, Farine I. Bone scanning in
the assessment of fractures of the scaphoid. J Hand Surg
1979; 4: 541-543.

Gasser H. Delayed union and pseudarthrosis of the carpal
navicular. Treatment by compression-screw
osteosynthesis. A preliminary report on 20 fractures. J
Bone Joint Surg 1965; 47A : 249-266.

Gelberman R H, Menon J. The vascularity of the scaphoid
bone. J Hand Surg 1980; 5: 508-513.

Gelberman R H, Panagis J S, Taleisnik J, Baumgaertner M.
The arterial anatomy of the human carpus. Part I: The
extraosseous vascularity. J Hand Surg 1983; 8:367-374.

Ghigi C. Contributo allo studio della articolazione
della mano. Chir Organi Mov 1939; 24:344-372.

Gilford W W, Bolton R H, Lambrinudi C. The mechanism of
the wrist joint, with special reference to fractures of
the scaphoid. Guys Hosp Rep 1943; 92:52-59.

Goeringer C F. Follow-up results of surgical treatment for nonunion of the carpal scaphoid bone. Report of nineteen cases. Arch Surg 1949; 58:291-307.

Goldman S, Lipscomb P R, Taylor W F. Immobilisation for acute carpal scaphoid fractures. Surg Gyn Obstet 1969; 129: 281-284.

Gollasch W. Congenital bipartite carpal scaphoid bones. Arch Orthop Unfallchir 1939; 40 : 269.

Gordon L H, King D. Partial wrist arthrodesis for old ununited fractures of the carpal navicular. Am J Surg 1961; 102:460-464.

Graziani A. L'esame radiologico del carpo. Radiol Med. 1940; 27 : 382-392.

Grettve S. Arterial anatomy of the carpal bones. Acta Anat 1955; 25:331-345.

Haverling M, Sylven M. Soft tissue abnormalities at fracture of the scaphoid. Acta Radiol (Diagn)(Stockh) 1978; 19 : 497-501.

Helfet A J. A new operation for ununited fracture of the scaphoid (Abstract). J Bone Joint Surg 1952 34B: 329.

Henry M G. Fractures of the carpal scaphoid bone in industry and in the military service. Arch Surg 1944; 48:278-283.

Herbert T J, Fisher W E. Management of the fractured scaphoid using a new bone screw. J Bone Joint Surg. 1984; 66B : 114-123.

Herness D, Posner M A. Some aspects of bone grafting for non-union of the carpal navicular. Analysis of 41 cases. Acta Orthop Scand 1977; 48:373-378.

Hill N A. Fractures and dislocations of the carpus. Orthop Clin North Am 1970; 1:275-284.

Hopkins F S. Fractures of the scaphoid in atheletes. N Engl J Med 1933; 209: 687-690.

Inglis A E, Jones E C. Proximal-row carpectomy for diseases of the proximal row. J Bone Joint Surg 1977; 59A : 460-463.

Jaekle R F, Clark A G. Acute fractures of the carpal scaphoid. Surg Gynecol Obstet 1939; 68:820-823.

Jahna H. Behandlung und Behandlungsergebnisse von 734 frischen einfachen bruch des kahnbeinkorpers der hand. Wien Med Wochenschr 1954; 104 : 1023-1024.

Jeanne L A, Mouchet A. Les lesions traumatique fermees du poignet. 28th Congres Francais De Chirurgie, 1919.

Johnson R W Jr. A study of the healing processes in injuries to the carpal scaphoid. J Bone Joint Surg 1927; 9:482-497.

Johnston H M. Varying positions of the carpal bones in the different movements at the wrist Part I. Extension, ulnar and radial flexion. J Anat 1907; 41:109-122.

Johnston H M. Varying positions of the carpal bones in the different movements at the wrist. Part II. (a) palmar and dorsal flexion, (b) radial and ulnar flexion with palmar and dorsal flexion. J Anat 1907; 41:280.

Johnston T B, Whillis J. Gray's Anatomy : Descriptive and applied. 30th edition, Longmans Green, New York 1949.

Jones F W. The principles of anatomy as seen in the hand. 2nd ed. Bailliere Tindall and Cox, London 1949.

Jorgensen E C. Proximal-row carpectomy: An end-result study of twenty-two cases. J Bone Joint Surg 1969; 51A: 1104-1111.

Jorgensen T M, Andresen J H, Thommesen P, Hansen H H. Scanning and radiology of the carpal scaphoid bone. Acta

Orthop Scand 1979; 50:663-665.

Kauer J M G. The interdependence of carpal articulation chains. Acta Anat 1974; 88:481-501.

Kauer J M G. The collateral ligament function in the wrist joint. Acta Morphol Neerl Scand 1979; 17: 252-253.

Kauer J M G. Functional anatomy of the wrist. Clin Orthop 1980; 149:9-20.

Kessler I, Heller J, Silberman Z, Pupko L. Some aspects in nonunion of fracture of the carpal scaphoid. J Trauma 1963; 3:442-452.

Kim W C, Shaffer J W, Idzikowski C. Failure of treatment of ununited fractures of the carpal scaphoid. J Bone Joint Surg 1983; 65 A : 985-991.

King R J, Mackenney R P, Elnur S. Suggested method for closed treatment of fractures of the carpal scaphoid J Roy Soc Med 1982; 75: 860-867.

Kondoyannis P N. A clinical sign in suspected fractures of the carpal scaphoid. J Bone Joint Surg 1982; 64A: 784.

Kuhlmann J N, Boabighi A, Kirsch J M, Mimoun M, Baux S.

An experimental study of plaster immobilisation for fractures of the carpal scaphoid : A clinical investigation. The French J Orthop Surg 1987; 1 : 43-50.

Landis J R, Koch G G. The measurement of observer agreement for categorical data. Biometrics. 1977; 33 : 159-174.

Landsmeer J M F. Studies in the anatomy of articulation. I. The equilibrium of the 'intercalated' bone. Acta Morphol Neerl Scand 1961; 3:287-303.

Larsen C F, Ipsen T, Merrild U, Elle B. Roentgenundersogelse ved fraktur af os scaphoideum. Ugeskr Laeger 1983; 145 : 3992-3995.

Larsen B, Light T R, Ogden J A. Fracture and ischemic necrosis of the immature scaphoid. J Hand Surg 1987; 12 A: 122-127.

Leslie I J, Dickson R A. The fractured carpal scaphoid. Natural history and factors influencing outcome. J Bone Joint Surg. 1981; 63B : 225-230.

Lewis D S, Calhoun T P, Garn S M, Carroll R E, Burdi A R. Congenital bipartite scaphoid : Fact or fiction. J Bone Joint Surg 1976; 58 A : 1108-1112.

Lewis O J, Hamshire R J, Bucknill T M. The anatomy of the wrist joint. J Anat. 1970; 106:539-552.

Lichtman D M, Alexander C E. Decision making in scaphoid non-union. Orthop Rev 1982; 11 : 55.

Lindgren E. Some radiological aspects on the carpal scaphoid and its fractures. Acta Chir Scand. 1949; 98 : 538-548.

Linscheid R L, Dobyns J H, Beabout J W, Bryan R S. Traumatic instability of the wrist : diagnosis, classification and pathomechanics. J Bone Joint Surg. 1972; 54 A : 1612-1632.

London P S. The broken scaphoid bone. The case against pessimism. J Bone Joint Surg 1961; 43B: 237-244.

MacConaill M A. The mechanical anatomy of the carpus and its bearing on some surgical problems. J Anat 1941; 75:166-175.

Mack G R, Bosse M J, Gelberman R H, Yu E. The natural history of scaphoid non-union. J Bone Joint Surg 1984; 66A : 504-509.

MacLennan A. The treatment of fracture of the carpal scaphoid and the indications for operation. Br Med J. 1911; 2:1089-1090.

Margo M K, Seely J A. A statistical review of 100 cases of fracture of the carpal navicular bone. Clin Orthop 1963; 31:102-105.

Matti H. Über die behandlung der navicularefraktur und der refractura patellae durch plombierung mit spongiosa. Zentralbl Chir 1937; 64: 2353-2359.

Maudsley R H, Chen S C. Screw fixation in the management of the fractured carpal scaphoid. J Bone Joint Surg 1972; 54B : 432-441.

Mayfield J K, Williams W J, Erdman A C , Dahlof W J, Wallrich M A, Kleinhenz W A, Moody N R. Biomechanical properties of human carpal ligaments Orthop Trans 1979; 3:143-144.

Mazet R, Hohl M. Radial styloidectomy and styloidectomy plus bone graft in the treatment of old ununited carpal scaphoid fractures. Ann Surg 1960; 152: 296-302.

Mazet R, Hohl M. Conservative treatment of old fractures of the carpal scaphoid J Trauma 1961; 1:115-127.

Mazet R, Hohl M. Fractures of the carpal navicular. Analysis of ninety-one cases and review of the literature. J Bone Joint Surg 1963; 45A: 82-112.

McCormack L J, Cauldwell E W, Anson B J. Brachial and antebrachial arterial patterns. A study of 750 extremities. Surg Gynecol Obstet 1953; 96:43-54.

McLaughlin H L, Parkes J C. Fracture of the carpal navicular (scaphoid) bone : Gradations in therapy based upon pathology. J Trauma. 1969; 9 : 311-319.

Melone C P. Scaphoid fractures. Concepts of management. Clin Plast Surg 1981; 8:83-94.

Minne J, Depreux R, Mestdagh H, Lecluse P. Les pedicules arteriels du massif carpien. Lille Med 1973; 18: 1174.

Monsivais J J, Nitz P A, Scully T J. The role of carpal instability in scaphoid nonunion : casual or causal ? J Hand Surg 1986; 11B : 201-206.

Moore A E. Treatment of delayed union of the carpal scaphoid. Br Med J 1938; 2:990.

Morgan D A F, Walters J W. A prospective study of 100 consecutive carpal scaphoid fractures. Aust N Z J Surg 1984; 54:233-241.

Mulder J E. Pseudarthrosis of the scaphoid bone (Abstract) J Bone Joint Surg 1963; 45B: 621.

Mulder J D. The results of 100 cases of pseudarthrosis

in the scaphoid bone treated by the Matti-Russe operation. J Bone Joint Surg 1968; 50B : 110-115.

Murray G. Bone-graft for non-union of the carpal scaphoid. Br J Surg 1934; 22:63-68.

Murray G. End results for bone-grafting for non-union of the carpal navicular. J Bone Joint Surg 1946; 28: 749-756.

Napier J. Hands. Pantheon, New York; 1980

Navarro A. Luxaciones del carpo. An Fac Med (Montevideo) 1921; 6:113-141.

Navarro A. Anatomia y fisiologia del carpo. An Inst Clin Quir Cir Exp. Montevideo, 1935.

Obletz B E, Halbstein B M. Non-union of fractures of the carpal navicular. J Bone Joint Surg 1938; 20:424-428.

O'Rahilly R. A survey of carpal and tarsal anomalies. J Bone Joint Surg 1953; 35A: 626-642.

Palmer I, Widen A. Treatment of fractures and pseudarthrosis of the scaphoid with central grafting (autogenous bone-peg) Acta Chir Scand 1955; 110: 206-212.

Pauwels F. Der schenkenholsbruck, ein mechanisches problem. Grundlagen des heilungsvorganges. Prognose und kausale therapie. Beilageheft zur zeitschrift fur Orthopaedische Chirurgie. Ferdinand Enke, Stuttgart, 1935.

Perey O. A re-examination of cases of pseudarthrosis of the navicular bone operated on according to Bentzon's technique. Acta Orthop Scand 1954; 23:26-33.

Perkins G. Fracture of the carpal scaphoid. Br Med J 1950; 1:536-538.

Peterson H A, Lipscomb P R. Intercarpal arthrodesis. Arch Surg 1967; 95:127-134.

Preiser G. Eine typische posttraumatische und zur spontannfraktur fuhrende Ostitis des naviculare carpi. Fortschr Geb Roentgenstr Nuklearmed 1910; 15:189.

Preiser G. Zur Frage der typischen traumatischen Ernährungsstorungen der kurzen hand und fusswurzelknochen. Fortschr Geb Roentgenstr Nuklearmed 1910; 15:189.

Robertson J M, Wilkins R D. Fracture of the carpal scaphoid. Br Med J 1944; 1:685-687.

Rothberg A S. Fractures of the carpal navicular.

Importance of special roengenography. J Bone Joint Surg 1939; 21: 1020-1022.

Ruby L K, An K N, Linscheid R L, Cooney W P, Chao E Y S. The effect of scapholunate ligament section on scapholunate motion. J Hand Surg 1987; 12A:767-771.

Ruby L K, Stinson J, Belsky M K. The natural history of scaphoid non-union : a review of fifty-five cases. J Bone Joint Surg 1985; 67A : 428-432.

Russe O. Fracture of the carpal navicular. Diagnosis, non-operative treatment and operative treatment. J Bone Joint Surg. 1960; 42A : 759-768.

SAS User's Guide : Statistics, Version 5 edition, SAS Institute Inc., Cary, North Carolina, 1985.

Sashin D. Treatment of fractures of the carpal scaphoid. A report of sixty-four cases. Arch Surg 1946; 52: 445-465.

Schernberg F, Elzein F, Gerard Y. Etude anatomo - radiologique des fractures du scaphoide carpien problems des cals vicieux. Rev Chir Orthop 1984; 70 (Supplementum 11) : 55-63.

Scott J H S. Assessment of ununited fractures of the carpal scaphoid. Proc Roy Soc Med 1956; 49: 961-962.

Smith L, Friedman B. Treatment of ununited fracture of the carpal navicular by styloidectomy of the radius. J Bone Joint Surg 1956; 38A: 368-376.

Soto-Hall R, Haldeman K O. Treatment of fractures of the carpal scaphoid. J Bone Joint Surg 1934; 16:822-828.

Soto-Hall R, Haldeman K O. The conservative and operative treatment of fractures of the carpal scaphoid (navicular). J Bone Joint Surg 1941; 23:841-850.

Speed K. Fractures of the carpal navicular bone. J Bone Joint Surg 1925; 7: 682.

Speed K. Injuries of the carpal bones. Surg Clin North Am 1945; 25:1.

Sprague B, Justis E J. Nonunion of the carpal navicular. Modes of treatment. Arch Surg 1974; 108:692-697.

Squire M. J Bone Joint Surg (letter) 1959; 41B: 210.

Stack J K. End results of excision of the carpal bones. Arch Surg 1948; 57: 245-252.

Stark A, Brostrom L A, Svartengren G. Scaphoid nonunion treated with the Matti-Russe technique : long term results. Clin Orthop 1987; 214: 175-180.

Stark H H, Rickard T A, Zemel N P, Ashworth C R.
Treatment of ununited fractures of the scaphoid by iliac
bone grafts and Kirschner-wire fixation. J Bone Joint
Surg 1988; 70A: 982-991.

Stecher W R. Roentgenography of the carpal navicular
bone. Am J Roentgenol 1937; 37: 704-705.

Steindler A. Post-graduate lectures on orthopaedics:
Diagnosis and indications. p 31-34, Vol 1. Charles C
Thomas (editor), Springfield, IL, 1950.

Stewart M J. Fractures of the carpal navicular
(scaphoid). A report of 436 cases. J Bone Joint Surg
1954; 36A: 998-1006.

Stimson L A. Fracture of the carpal scaphoid with
dislocation forward of the central fragment. Ann Surg
1902; 35: 574.

Sutro C J. Treatment of nonunion of the carpal navicular
bone. Surgery 1946; 20: 536-540.

Swanson A B. Silicone rubber implants for the
replacement of the carpal scaphoid and lunate bones.
Orthop Clin North Am 1970; 1:299-309.

Taleisnik J. Fractures of the scaphoid. p 105-148. In

The Wrist. Churchill Livingstone, New York, 1985.

Taleisnik J. The ligaments of the wrist J Hand Surg
1976; 1:110.

Taleisnik J, Kelly P J. The extraosseous and
intraosseous blood supply of the scaphoid bone. J Bone
Joint Surg 1966; 48A:1125-1137.

Terry D W, Ramin J E. The navicular fat stripe : a
useful roentgen feature for evaluating wrist trauma. Am
J Roentgenol 1975; 124: 25-28.

Testut L, Latarjet A. Tratado de anatomia humana. Vol 1,
9th edition, Salvat Editores, Buenos Aires, 1951.

Thomaidis V T. Elbow wrist thumb immobilisation in the
treatment of fractures of the carpal scaphoid Acta
Orthop Scand 1973; 44:679-689.

Thorndike A, Garrey W E. Fractures of the carpal
scaphoid. N Engl J Med 1940; 222:827-830.

Todd A H. Fractures of the carpal scaphoid. Br J Surg
1921; 9: 7-26.

Torngren S, Sandqvist S. Pseudarthrosis in the scaphoid
bone treated by grafting with autogenous bone-peg. A
follow up study. Acta Orthop Scand 1974; 45: 82-88.

Vahvanen V, Westerlund M. Fractures of the carpal scaphoid in children. A clinical and roentgenological study of 108 cases. Acta Orthop Scand 1980; 51:909-913.

Vender M I, Watson H K, Wiener B D, Black D M. Degenerative change in symptomatic scaphoid nonunion. J Hand Surg 1987; 12 A :514-519.

Verdan C. Le role du ligament anterieur radio-carpien dans les fractures du scaphoide: Deductions therapeutiques. Z Unfallmed Berufskr 1954; 54: 299-297.

Verdan C. Fractures of the scaphoid. Surg Clin North Am. 1960; 40:461-464.

Verdan C, Narakas A. Fractures and pseudarthrosis of the scaphoid. Surg Clin North Am 1968; 48: 1083-1095.

Vesalius A. De Humani Corporis Fabrica, Libri septem, Basilae, 1543. Ex Officiana I Oporini, Bruxelles, 1964.

Von Bonin G. A note on the kinematics of the wrist joint. J Anat 1929; 63 : 259.

Wagner C J. Fractures of the carpal navicular. J Bone Joint Surg 1952; 34A: 774-784.

Watson H K. Limited wrist arthrodesis. Clin Orthop 1980; 149: 126-136.

Watson H K, Goodman M L, Johnson T R. Limited arthrodesis. Part II: Intercarpal and radiocarpal combinations. J Hand Surg 1981; 6: 223-233.

Watson H K, Ryu J, Akelman E. Limited Triscaphoid intercarpal arthrodesis for rotatory subluxation of the scaphoid. J Bone Joint Surg. 1986; 68A : 345-349.

Watson-Jones R. Fractures and Joint Injuries. 4th Edition. Vol 2. Williams & Wilkins, Baltimore, 1960

Weber E R, Chao E Y. An experimental approach to the mechanism of scaphoid waist fractures. J Hand Surg 1978; 3:142.

Weber E R. Biomechanical implications of scaphoid waist fractures. Clin Orthop 1980; 149: 83-89.

Wilson J N: Watson-Jones fractures and joint injuries. 5th Ed. Vol 2. Churchill Livingstone, New York, 1976

Wilson-MacDonald J. Delayed union of the distal scaphoid in a child. J Hand Surg 1987; 12A: 520-522.

Wright R D. A detailed study of movement of the wrist joint J Anat 1935; 70:137-142.

Youm Y, McMurty R Y, Flatt A E, Gillespie T E.
Kinematics of the wrist. 1: An experimental study of
radio-ulnar deviation and flexion-extension. J Bone
Joint Surg 1978; 60A: 423-431.

Young M R A, Lowry J H, McLeod N W, Crone R S. Clinical
carpal scaphoid injuries. Br Med J. 1988; 296 : 825-826.

Ziter F M H. A modified view of the carpal navicular.
Radiology 1973; 108 : 106-107.

SECTION 5.2

Real time ultrasonography

A: Equipment : The Acuson Model 128 Ultrasound System

This is a free standing and self contained system capable of wide aperture rectilinear and sector scans providing real time and/or post-processing imageimg. Image enhancement modes can be selected to optimise each aspect of the image.

The transducer (Figure 5.2-1) emits the acoustic energy pulses that are transmitted into the body. The reflected energy represents acoustic density variations representative of the patient's acoustic properties. The transducer consists of 128 piezo-electric crystals, each of which has an individual transmit and receive channel. The Dynamic Computed Lens System (DCLS) drives combinations of these elements so that a focused beam sweeps the body area that is to be examined. The operator can select the enhancement of the transmitted pulse while the received signals are dynamically focused by the DCLS to ensure optimum image quality. After the reflected pulses are received, there are a number of ways that the received data can be pre- or post-processed for ease of viewing and image enhancement. Different processing is used for wide

aperture rectilinear scan and sector scan transducers. The system automatically recognises the type of transducer used. The image display and analysis computer (IDAC) receives the analogue scan lines from the DCLS. This data is digitised and processed by the IDAC in a manner that provides for efficient utilisation of memory. After the data is processed, it is converted to video and presented on the display monitor. The IDAC is also responsible for the pre and post processing functions of the system and the system graphics. The IDAC also provides the interface capabilities for the video recorder.

B: Gain control

Losses in signal strength caused by the ultrasound wave being attenuated as it passes through anatomical structures and travels deeper into the body can be compensated for using the slide controls. This permits eight zones of the image to be independently controlled.

C: Transmitter power and image depth

Transmitter power output can be adjusted in 3db steps from 0db to -21 db. The depth of the image can be adjusted from 80 to 240 mm in the linear mode.

D: Magnification

A rectangular area of the image can be selected and then

magnified to a variable extent so that the selected area fill the image area while the rest of the image disappears. In this mode the computer adds as many real ultrasound lines or interpolated lines as are necessary to ensure optimum image quality.

E: Image processing

The signal intensity and the image brightness of the raw analogue image can be modified by the computer in a number of different pre-set or user defined ways to enhance the presentation of the image on the screen and to improve viewing (Post-processing). In addition, three levels of edge enhancement (edges are accentuated, interior details are reduced) are also available (pre-processing). Finally the rate of image update can be changed and frame to frame averaging can be adjusted. A high rate of change is of use in imaging blood vessels where the pulsation is used to identify them.


F: The method of assessing the wrist using ultrasonography

The 5MHz rectilinear 128 probe is used to image the wrist from the volar surface. We usually use the following settings : pre-processing-2, persistence-5, post-processing-5. The magnification and gain are

adjusted as required for each individual patient.

The wrist to be examined is placed flat on the examination surface, with the palm facing upwards. Acoustic gel is then liberally applied to the volar surface of the wrist and the middle column and scaphoid imaged as described in the relevant sections in greater detail.

FIGURE 5.2-1 : The 5 MHz linear transducer.



Scaphoid Fracture Union

Joseph J Dias

Thesis submitted for the MD degree, University of Leicester, 1989.

Scaphoid fracture union depends upon early diagnosis and adequate management and is considered to be adversely influenced by proximal scaphoid avascularity and carpal instability. There is, however, controversy on various aspects in the diagnosis and management of this injury. Studies investigating some of these aspects are reported in this thesis.

With regard to the initial diagnosis of this fracture this thesis demonstrated that the fracture was usually visible on the 'Ziter' or the postero-anterior radiographic view while radiographic evaluation of soft tissue swelling was of less value than that suggested by current literature. Moreover, the second week radiograph did not provide reliable evidence of a fracture in those suspected on clinical examination alone. Normal lines in an intact scaphoid could be mis-interpreted as a fracture.

With regard to management, the fracture healed equally well in a Colles' cast : thumb immobilisation did not appear to be necessary. The incidence of non-union was around 12% and most were symptomatic. A further 25%, in whom the fracture site was easily identified but appeared to have healed, formed a distinct clinical group and many had symptoms.

The reliability and reproducibility of radiographic signs of union were poor. Therefore, a real time ultrasonographic method of demonstrating movement at the scaphoid fracture site was developed. Proximal avascularity was more common than that suggested by radiographic appearances alone while carpal instability was uncommon within two years of injury.

Based on these observations a rational approach to management of scaphoid fractures was proposed.