

**UPREGULATION OF CYTOKERATINS IN THE EXTRAVILLOUS  
TROPHOBLAST IN THE BASAL PLATE OF HEALTHY AND  
PRE-ECLAMPTIC PLACENTAE**

BY

JOHN AHENKORAH

(M. Phil., B.Sc. (Hons), Dip. Ed.)

Department of Infection, Immunity and Inflammation

A thesis submitted for the award of a Doctor of Philosophy degree at the  
University of Leicester, United Kingdom.

AUGUST, 2009

**AUTHOR: JOHN AHENKORAH**

**TITLE: UPREGULATION OF CYTOKERATINS IN THE EXTRAVILLOUS TROPHOBLAST IN THE BASAL PLATE OF HEALTHY AND PRE-ECLAMPTIC PLACENTAE**

## **ABSTRACT**

This research has determined which specific keratin molecular species are upregulated when comparing the chorionic villous trophoblast (CVT) to the extravillous trophoblast (EVT) in the basal plate tissues of placentae from healthy and pre-eclamptic mothers at term. Indirect immunofluorescence Confocal Laser Scanning Microscopy (CLSM) revealed that at least 5 keratin proteins are expressed in villous trophoblast and the same 5 in extravillous trophoblast. A further 15 keratin proteins tested were undetectable in these tissues. All the specific keratins identified (K5, 7, 8, 18 and 19) in trophoblast were upregulated by over 20-fold in the EVT “percentage of pixels with high intensity”, a reflection of increased specific immunofluorescence. The statistically significant difference ( $P < 0.0001$ ) of K5 for example, showed an increase from a median pixel value of 0.14% in CVT to 2.88% in the EVT whereas in the pre-eclamptic there was an increase from 0.06% in the CVT to 2.97% in the EVT. Similar patterns were obtained for K7, 8, 18, and 19. The reduction in the ratio of 4.8:1 of the percentage median pixel intensity from the healthy to pre-eclamptic CVT keratin related immunofluorescence expression was statistically significant in all 5 keratins ( $p < 0.0001$ ). There were no significant differences in immunofluorescence pixel intensity for the EVTs at the CLSM level. At the electron microscopy level, immunogold labelling technique using anti-**K7** and anti-**K18** antibodies which were representatives of the two major keratin families TYPE II and TYPE I respectively, were down regulated in the CVT and EVT in pre-eclamptic compared with the healthy. On the basis of the results of these investigations the villous trophoblast in pre-eclamptic placentae may be cytoskeletally weaker through deficiency of these keratin filaments. This could be a reason why, in pre-eclampsia, trophoblast is deported in greater quantity than in healthy placenta.

## ACKNOWLEDGEMENTS

I am indebted to the Government of Ghana for providing funds for this work under the Ghana Government scholarship scheme for staff development through the University of Ghana Medical School and the Department of Anatomy.

I wish to express my heart-felt thanks to my supervisor Prof. Colin Ockleford, under whose mentorship I am privileged to have learnt a lot, directing and constructively criticising my work all the way from the beginning till the end.

I also thank all the supervisory and thesis committee members, Dr. Caroline Beardsmore, a source of encouragement when all seemed difficult, Dr. Laura Mongan and Dr. Amir Gulamhusein for their support.

My special thanks to all the consultants, nurses and midwives of the Leicester Royal Infirmary delivery suites for their help in the collection of placental samples and all the mothers of the babies whose placentae I used.

I wish to express my profound gratitude to Prof. Francis Frankenne, University of Leige, Belgium, for allowing me to study the use of laser microdissection in his laboratory with the kind help from Benoit Brouwers, the laboratory assistant through the EMBIC laboratory exchange grant. My appreciation also goes to Dr. Peter March, Manchester University for making available his laser microscope for part of this work. I am also very grateful to Dr. Bernard Burke, Department of Infection, Immunity and Inflammation for his suggestions and constructive criticism of my PCR work.

This work was also supported by a generous grant from MediSearch (Leicester) when I needed help under a stressful condition. To all the trustees and donors I say a big thank you. I wish to acknowledge Simon Byrne who held my hands through some of the techniques and lastly a big thank you to my fellow PhD friends Bismarck Hottor and Kimberly Smith for their help and encouragement in and out of the laboratory.

## **Publications based on work presented in this thesis**

### **Full papers**

**Ahenkorah, J., Hottor, B., Byrne, S., Bosio, P. and Ockleford, C.D. (2009).**

Immunofluorescence confocal laser scanning microscopy and immuno-electron microscopic identification of keratins in human maternofetal interaction zone.

*J. Cell Mol Med.*, **13**(4): 735-748.

**Byrne, S., Ahenkorah, J., Hottor, B., Lockwood, C. and Ockleford, C.D. (2007).**

Immuno-electron microscopic localisation of caveolin 1 in human placenta. *Immunobiology*, **212**: 39-46.

### **Abstracts**

**Ahenkorah, J., Hottor, B.A., Byrne, S., Waugh, J., Bosio, P. and Ockleford, C.D. (2008).**

A confocal laser scanning microscopy analysis of differentially expressed cytokeratins in pre-eclamptic and healthy term placental basal plate tissue. *Journal of Anatomy*. **212**(1): 79.

**Ahenkorah, J., Hottor, B., Davis, N., Byrne, S., Waugh, J., Bosio, P. and Ockleford, C.D. (2007).** Differential expression of cytokeratins 7 & 18 in the villous and extravillous trophoblast cells: a confocal microscopy study. Proceedings of the joint meeting of the Anatomical Society of Great Britain and Ireland and the Spanish Anatomical Society. Universidad Complutense, Madrid 13<sup>th</sup>-15<sup>th</sup> September, 2006. *Journal of Anatomy* **210**(5):612, A24

**Hottor, B., Ahenkorah, J. and Ockleford, C.D. (2009).** The lining of the intervillous space of term human placenta is a mosaic monolayer derived from different individuals and different germ layers. **Proceedings of the 17<sup>th</sup> International Congress of the Federation of Associations of Anatomists. Cape Town-South Africa, 16-19th August, 2009.**

### **Proceedings**

**Ahenkorah, J., Hottor, B.A., Davis, N., Byrne, S., Waugh, J., Bosio, P. and Ockleford, C.D. (2006).** Immunocytochemical study of cytokeratins in placental basal plate tissue from healthy mothers using confocal laser scanning microscopy. Proceedings of the first EMBIC summer school "Embryo Implantation from basics to clinics" Ed D. Rukhavina and Gerard Chaouat. P47

**Ahenkorah, J., Hottor, B.A., Smith, K., Byrne, S. and Ockleford, C.D. (2007).** "New opportunities for reproductive biologist using advanced light microscopes" Proceedings of *second EMBIC Summer School Pecs Hungary* Ed Julia Szerkes Bartho, Gerard Chaouat and Patricia Joseph-Mathieu p26-27.

**Ahenkorah, J., Hottor, B. A., Smith, K. Byrne, S. Setalo, G., Halidi, N., Brouwers, B., Frankenne, F. and Ockleford, C.D. (2008).**

Morphological Methods. *2nd EMBIC Summer School Handbook “Molecular Methods of Implantation” Proceedings of the 2<sup>nd</sup> EMBIC Summer School* Ed Julia Szerkes Bartho, Gerard Chaouat and Patricia Joseph-Mathieu, pp813-860. Inserm Transfert Paris.

## **DEDICATION**

I wish to dedicate this thesis to my family, Angela my wife for her understanding and my children, **Christabel**, **Caleb** for their obedience and most importantly to **Cindy** for her brave fight against cancer and surviving it.

*“.....Some men who, whether they only imagine the fact might be true, or really found it to be so, would be very ready to assume all the merit of discovery to themselves.”*

John Hunter

# TABLE OF CONTENTS

Abstract	i
Acknowledgments	ii
Peer reviewed publication based on work submitted	iii
Dedication	v
Table of content	vi
Abbreviations	xiii
Index of Figures referred to in the text	xvii
Index of Tables referred to in the text	xx
<b>1.0    CHAPTER ONE: General Introduction</b>	<b>1</b>
1.1    Development of the human placenta	1
1.1.1    The trophoblast as an epithelium	1
1.1.2    Implantation	2
1.1.3    Formation of Villi	4
1.1.4    The full term human placenta	5
1.1.5    Chorionic villous trophoblast	7
1.1.6    Remodelling of spiral arterioles	9
1.1.7    The Extravillous Trophoblast (EVT)	10
1.1.7.1    Some functions of EVTs	13

1.1.8	Some functions of the human placenta	14
1.1.9	The basal plate tissue	15
1.1.9.1	Growth of the basal plate	15
<b>1.2</b>	<b>Hypertensive disorders in pregnancy</b>	<b>18</b>
1.2.1	Pre-eclampsia	19
1.2.2	Etiological theories	19
1.2.3	Endothelial dysfunction	20
1.2.4	Inappropriate remodelling of spiral arteries in pre-eclampsia	23
<b>1.2.5</b>	<b>Trophoblast deportation</b>	<b>24</b>
1.2.6	Immune maladaptation	30
1.2.7	Genetic and epigenetic considerations of pre-eclampsia	33
1.2.8	Management of pre-eclampsia	33
<b>1.3</b>	<b>Cytoskeleton</b>	<b>35</b>
1.3.1	General structure of intermediate filaments	36
1.3.2	Keratins (Ks)	38
1.3.3	Keratin and desmosomes	41
1.3.4	Keratin associated diseases	44
1.3.5	Other functions of keratins	44
1.3.6	Regulation of transcription of keratin genes	47



1.3.7	Keratins and the human placenta	48
<b>1.4</b>	<b>Confocal laser scanning microscopy (CLSM)</b>	<b>51</b>
1.4.1	Principle of confocal fluorescence microscope	52
<b>1.5</b>	<b>Laser Capture Microdissection (LCM)</b>	<b>54</b>
1.5.1	Advantages of LCM over conventional microdissection	55
1.5.2	Disadvantage of LCM	56
<b>1.6</b>	<b>Research aims and objectives</b>	<b>57</b>
<b>1.7</b>	<b>Summary</b>	<b>58</b>
<b>2.0</b>	<b>CHAPTER TWO: Materials and methods</b>	<b>59</b>
2.1	Patient Recruitment	59
2.2	Tissue sampling	60
2.3	Sectioning	61
2.4	Fixation	61
<b>2.5</b>	<b>Immunohistochemistry</b>	<b>62</b>
2.5.1	Primary (first- Step) Antibody Incubation	62
2.5.2	Secondary (second-step) fluorescent antibody incubation	62
2.5.3	Immunofluorescence	63
2.5.4	Confocal laser scanning microscopy (CLSM)	63
2.5.5	Measurements and statistical analysis	64

<b>2.6</b>	<b>Electron microscopy-immunogold labelling</b>	<b>65</b>
2.6.1	Methodology	65
2.6.2	Tissue processing	65
2.6.3	Sectioning	66
2.6.4	Immunogold labelling with primary antibody	66
2.6.5	Pre-treatment step	67
2.6.6	Staining	67
2.6.7	Electron microscopy: Imaging	68
2.6.8	Counting of gold particles	68
<b>2.7</b>	<b>Western blotting</b>	<b>69</b>
2.7.1	Fine manual microdissection	69
2.7.2	SDS PAGE	71
2.7.2.1	Preparation of glass plates	71
2.7.2.2	Casting of polyacrylamide gradient gel	71
2.7.2.3	Running the gel	72
2.7.2.4	Staining the gel with Coomassie brilliant blue	73
2.7.2.5	Semi-dry transfer of proteins from gel to membrane	73
2.7.2.6	Detection of antigens immobilised on the membrane	74
2.7.2.7	Chemiluminescent detection of keratins	75

<b>2.8</b>	<b>Methodology of laser catapulting microdissection (LCM)</b>	<b>76</b>
2.8.1	Tissue preparation and staining	76
2.8.2	Laser cutting of cells	77
2.8.3	RNA isolation and REAL-TIME RT-PCR	78
2.8.3.1	Total RNA extraction	78
2.8.3.2	Reverse transcription	79
2.8.3.3	Quantification of housekeeping gene (beta-2 microglobulin)	80
2.8.3.4	Amplification reaction	81
<b>2.9</b>	<b>Keratin 7 PCR</b>	<b>81</b>
2.9.1	Keratin 7 primer design	81
2.9.2	Nested PCR	82
2.9.3	Agarose gel electrophoresis	84
<b>3.0</b>	<b>CHAPTER THREE: RESULTS</b>	<b>86</b>
3.1	Overview of keratin expression	86
3.2	Immunofluorescence results	87
3.2.1	CLSM quantification	96
3.2.2	Distribution of extravillous trophoblast in basal plate tissue	107
3.2.3	Summary of indirect- immunofluorescence confocal laser scanning microscopy	109

<b>3.3</b>	<b>Immunogold electron microscopy results</b>	<b>110</b>
3.3.1	Immunogold labelling of keratins intermediate filament	112
<b>3.4</b>	<b>Verification of the reactivity of keratin antibodies by western blotting</b>	<b>117</b>
3.4.1	Dual labelling technique verification of keratin antibody	120
<b>3.5</b>	<b>Laser capture microdissection results</b>	<b>121</b>
3.5.1	Agarose gel of PCR products	125
<b>4.0</b>	<b>CHAPTER FOUR: General discussions</b>	<b>126</b>
4.1	Confocal Laser Scanning Microscopy	126
4.1.2	Pattern of keratin expression in human placental basal plate tissue at term	127
4.1.3	Banded pixel intensity of digital images	128
4.1.4	Cluster and linear organisation of EVT's in basal plate	130
4.1.5	Significance of differential keratin expression in CVTs	130
4.1.6	Oxidative stress, innate immunity and the signalling role of keratins	132
4.1.7	Functional significance of upregulation of keratins in EVT's	135
<b>4.2</b>	<b>Discussions of the immuno-electron microscopy study</b>	<b>137</b>
4.3	Specific keratins	138
4.4	Keratins and the extracellular matrix	139
4.5	Discussions on Immunoblots	141
4.6	Discussions of Laser microdissection experiments	142
4.7	Limitations of study	143
4.8	Future work	144

5.0	Conclusion	145
6.0	Appendices	146
7.0	Bibliography	173

## **ABBREVIATIONS**

ACOG = American College of Obstetricians and Gynecologists

AMV = Avian Myeloblastosis Virus

APS = Ammonium persulphate

AUTO LPC = Automatic laser pressure catapulting

B2M = Beta-2-microglobulin

BSA = Bovine serum albumen

BP = Basal plate

BPh = Healthy basal plate tissue sample

BPp = Pre-eclamptic basal plate tissue sample

BPmd = Basal plate tissue manually dissected sample

BM = Basement membrane

BMI = Body mass index

CAT = Catalase

cDNA = Complementary Deoxyribonucleic acid

CK = Cytokeratin

CLSM = Confocal Laser Scanning Microscope

CT = cytotrophoblast

CVTmd = Chorionic villous trophoblast manually dissected sample

CVT = Chorionic villous trophoblast

CVTh = Healthy chorionic villous trophoblast tissue sample

CVTp = Pre-eclamptic chorionic villous trophoblast tissue sample

DABCO = Diazabicyclo [2.2.2] octane

DEPC = Diethylpyrocarbonate

DNA = Deoxyribonucleic acid

DTT = Dithiothreitol

ECM = Extracellular matrix

EM = Electron microscopy

EMBIC = **E**mbryo **I**mplantation **C**ontrol

EVT = Extravillous trophoblast

EVTh =Healthy extravillous trophoblast tissue sample

EVTp = Pre-eclamptic extravillous trophoblast tissue sample

FCS = Fetal calf serum

FITC =Fluorescein Isothiocyanate

FFAs = free fatty acids

LDLs = low-density lipoproteins

GH = Growth hormone

IGF = insulin-like growth factor

GlcNAc = N-acetylglucosamine

GPX = Glutathione peroxidase

hACTH = human chorionic adrenocorticotrophin

Hb = Basic hair keratin

Ha = Acidic hair keratin

hCG = human chorionic gonadotrophin

hPL = human placental lactogen

HLA = Human Leukocyte Antigen

HUVEC = Human Umbilical Vein Endothelial Cell

ICAM = Intercellular adhesion molecule

IFs = Intermediate filaments

IMS = Industrial methylated spirit

ISSHP = International Society for the Study of Hypertension in Pregnancy

IUGR = intrauterine growth restriction

K = Keratin

KIR = Killer Immunoglobulin-like receptor

LCM = Laser capture microdissection

LCP = Lectin complementary pathway

LT Br = Lymphotoxin  $\beta$  receptor

MBL = Mannose-binding lectin

mmHg = Millimeters of mercury

mRNA = Messenger Ribonucleic Acid

NaCl = Sodium Chloride

OCT = Optimum cutting temperature

OFRs = Oxygen free radicals

PBS = Phosphate buffered saline

PBS-T = Phosphate buffered saline with Tween-20 solution

PBSGAT= Phosphate buffered saline with Goat serum, Bovine serum Albumen and Tween-20 solution

PCR = Polymerase chain reaction

PIGF = Placenta growth factor

PVC = Polyvinylchloride

PVDF = Polyvinylidene fluoride

QPCR = Quantitative Polymerase chain reaction

rcf = Relative centrifugal force

rpm = Revolutions per minute

RNA= Ribonucleic Acid

RT-PCR = Real time- Polymerase chain reaction

SB = Sample buffer

SDS PAGE = Sodium Dodecyl Sulphate Polyacrylamide Gel Electrophoresis

sEng = soluble endoglin

sFlt-1= soluble fms-like tyrosine kinase-1

SODs = Superoxide dismutase



SPINT1 = serine protease inhibitor TYPE 1

STB = Syncytiotrophoblast

STBM = syncytiotrophoblast microparticles

T<sub>3</sub> = Triiodothyronine

TAE = Tris-acetate-EthyleneDiamine Tetra acetic acid

TEM = Transmission electron microscope

TEMED = N,N,N',N'-tetramethylenediamine

TBS-T = Tris-buffered saline and Tween -20 solution

TGF = Transforming growth factor

Th1 = T helper cell 1

TNF = Tumour necrosis factor

TNFr2 = Tumour Necrosis Factor receptor 2

TNTr1 = Tumour Necrosis Factor receptor 1

TGM2 = tissue transglutaminase-2

v/v = volume by volume

VEGF = Vascular endothelial growth factor

w/v = weight by volume

WHO = World Health Organisation

## INDEX OF FIGURES REFERRED TO IN THE TEXT

1.1	Week 10 of pregnancy showing different types of decidua	3
1.2	Fetal surface of freshly delivered human placenta	5
1.3	Maternal surface of a freshly delivered human placenta	6
1.4	Spiral arteriole remodelling in two pregnancies	9
1.5	Formation of an intermediate filament	37
1.6	A cell to cell junction linked to keratin filaments	42
1.7	A schematic drawing of a confocal laser scanning microscope	53
3.1	Anti-keratin 5 immunofluorescence of term placental basal plate tissue	87
3.2A.	Keratin 7 immunofluorescence distribution of term placental basal plate tissue	88
3.2B.	Isotype control of mouse IgG <sub>1</sub> for keratin 7	88
3.3	Anti-keratin 8 immunofluorescence of term placental basal plate tissue	89
3.4A.	Anti-keratin 18 immunofluorescence of term placental basal plate tissue	90
3.4B.	Isotype control of mouse IgG <sub>1</sub> for keratin 18	90
3.4C.	A Nomarski differential interference contrast and anti-keratin 18 immunofluorescence micrographs of basal plate tissue	90
3.5A.	Anti-keratin 19 immunofluorescence micrograph of term placental basal plate	91
3.5B.	Isotype control of mouse IgG <sub>2a</sub> for keratin 19	91
3.6	Anti-keratin 13 immunofluorescence micrograph of amniochorion at term	92
3.7A.	Anti-keratin 14 immunofluorescence micrograph of term placental basal plate tissue	93
3.7B.	Anti-keratin 14 immunofluorescence micrograph of amniotic epithelium at term	93
3.7C.	Control micrograph of anti- keratin 14 antibody	93
3.8A.	Anti-keratin 17 immunofluorescence micrograph of term placental basal plate tissue	94
3.8B.	Anti-keratin 17 immunofluorescent distribution of amniochorion at high power	94
3.9	Anti-keratin 7 immunofluorescence of amniochorion at term	95

3.10A. A banded fluorescent intensity micrograph of anti-K18 antibody	97
3.10B. A graph of the percentage pixel intensity distribution of anti-K18 Immunofluorescence	97
3.11A. A banded fluorescent intensity micrograph of anti-K7 antibody	98
3.11B. A graph of the percentage pixel intensity distribution of anti-K7 Immunofluorescence	98
3.12 Box plot of anti-keratin 5 immunofluorescence data of tissue areas from healthy (h) and pre-eclamptic (p) placentae	102
3.13 Box plot of anti-keratin 7 immunofluorescence data of tissue areas from healthy (h) and pre-eclamptic (p) placentae	103
3.14 Box plot of anti-keratin 8 immunofluorescence data of tissue areas from healthy (h) and pre-eclamptic (p) placentae	104
3.15 Box plot of anti-keratin 18 immunofluorescence data of tissue areas from healthy (h) and pre-eclamptic (p) placentae	105
3.16 Box plot of anti-keratin 19 immunofluorescence data of tissue areas from healthy (h) and pre-eclamptic (p) placentae	106
3.17A. A cluster and linear stretch of EVT's in the basal plate at term	107
3.17B. A linear stretch of EVT's in the basal plate at term	108
3.18 EM micrograph of extravillous trophoblast cells in the basal plate	110
3.19 EM micrograph of chorionic villous trophoblast at term	111
3.20 EM micrograph of intermediate filament bundles associated with anti-keratin 18 coated gold particles	112
3.21 EM micrograph of CVT intermediate filaments associated with anti-keratin 18 gold Particles	113

3.22A.	EM micrograph of intermediate filament bundles associated with anti-keratin 7 coated gold particles	114
3.22B.	Control EM micrograph of intermediate filaments exposed to gold particles	114
3.23	Bar chart illustrating the relative immunogold labelling of anti-K18 antibody in healthy and pre-eclamptic tissues	115
3.24	Bar chart illustrating the relative immunogold labelling of anti-K7 antibody in healthy and pre-eclamptic tissues	116
3.25	An SDS-PAGE of crude basal plate lysate from healthy and pre-eclamptic placentae	117
3.26	Immunoblots of anti-keratin expression in CVT, basal plate and amnion	118
3.27	Immunoblots of CVT and basal plate lysates from healthy and pre-eclamptic placentae against anti-K18 antibody	119
3.28	Immunoblots of healthy and pre-eclamptic CVT lysates against anti-K19 antibody	119
3.29	Dual stained micrograph of trophoblast and endothelial cells	120
3.30	Immunostained term placental basal plate tissue with one step FITC-labelled anti-K18 antibody	121
3.31A&B.	Laser microdissection of extravillous trophoblast cells	122
3.32A.	Chorionic villous trophoblast cells immunostained for laser microdissection	123
3.32B.	Chorionic villous trophoblast cell marked out	123
3.32C.	Laser microdissected CVT area	123
3.33A&B.	Caps for collection of laser microdissected cells before and after	124
3.34	Agarose gel image of PCR products of laser captured and manually dissected placental tissues	125
<b>Diagram 1.1:</b>	A schematic drawing of human placental basal plate tissue	17
<b>Diagram 2.1</b>	Illustration of quadrants and positions on the maternal surface of the placenta from which samples were taken	60

## **INDEX OF TABLES REFERRED TO IN THE TEXT**

Table 1: List of keratin antibodies used in the study (Appendix 1)	146
Table 2: An overview of keratin expression	86
Table 3: Summary statistical results of keratin 5 immunofluorescent intensity data for healthy and pre-eclamptic placentae	99
Table 4: Summary statistical results of keratin 7 immunofluorescent intensity data for healthy and pre-eclamptic placentae	99
Table 5: Summary statistical results of keratin 8 immunofluorescent intensity data for healthy and pre-eclamptic placentae	100
Table 6: Summary statistical results of keratin 18 immunofluorescent intensity data for healthy and pre-eclamptic placentae	100
Table 7: Summary statistical results of keratin 19 immunofluorescent intensity data for healthy and pre-eclamptic placentae	101
Table 8: Descriptive statistics of K18 immunogold labelling experiment	115
Table 9: Descriptive statistics of K7 immunogold labelling experiment	116

## **1.0 CHAPTER ONE: GENERAL INTRODUCTION**

### **1.1 DEVELOPMENT OF THE HUMAN PLACENTA**

The term “placenta” commonly known as the “afterbirth” was reported to have been first used by Realdus Columbus in 1559, a Latin word for a circular cake (Boyd and Hamilton, 1970). It is an organ formed during pregnancy, from two separate individuals (the fetus and the mother) and hence generally referred to as a feto-maternal organ. The fetal part, the chorion frondosum (leafy chorion) originates from the trophoblast, as villi at the embryonic pole. The maternal part, the decidua basalis is formed from the uterine endometrium.

After fertilization, the zygote becomes a solid ball of many cells (blastomere) and this ball is known as a morula which once filled with fluid becomes known as the blastocyst. The first structure to differentiate in the blastocyst is the trophectoderm (Loke and King, 1995). The trophoectoderm cells are cells which form a layer that circles the blastocyst cavity. The trophoctoderm is the progenitor tissue of the entire outer epithelial component of the placenta called trophoblast which produces the functional bridge between the fetus and the mother (Roberts *et al.*, 2004). The inner cell mass then forms at the pole through blastomeres entering the cavity and differentiating into the embryo.

#### **1.1.1 THE TROPHOBLAST AS AN EPITHELIUM**

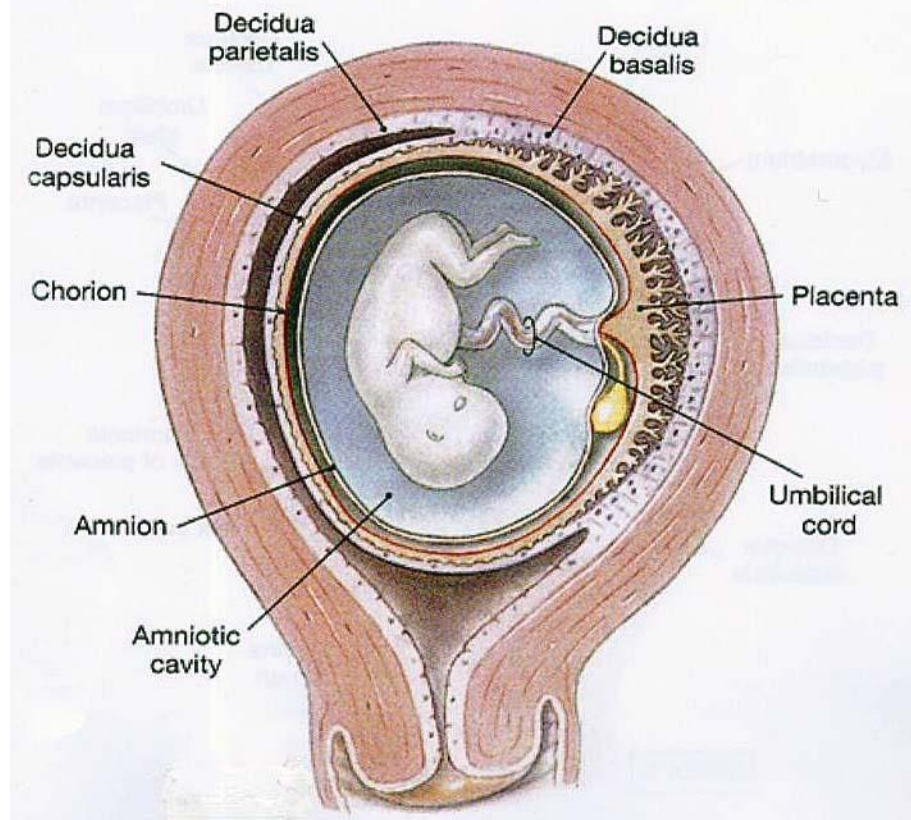
Trophoblast belongs to a family of ectodermal epithelial tissues that constitute the outer envelope of the conceptus (Boyd and Hamilton, 1970). It has been described as a “true epithelium” (Muhlhauser *et al.*, 1995) and the villous trophoblastic epithelium has also been previously described as a “simple epithelium” (Bosch *et al.*, 1988). The latter is not strictly accurate as the epithelium is initially bilaminar and interestingly does not fit neatly into the generally accepted classification of epithelia found in text books of histology. The trophoblastic epithelium unlike simple epithelia, consist of two

distinct cell layers (cytotrophoblast and syncytiotrophoblast) that are supported by a basal lamina in early development. These two cell types are morphologically different.

### **1.1.2 IMPLANTATION**

This is a complex but tightly regulated process by which the early blastocyst burrows into the endometrium. The process of implantation begins six to seven days following fertilization (Vigano *et al.*, 2003) and also signifies the beginning of the formation of the placenta. Implantation is believed to consist of basically three stages (Norwitz *et al.*, 2001), an apposition phase, with the initial unstable adhesion of the blastocyst to the uterine wall, a stable adhesion phase, which denotes a close interaction of the embryonic trophoblast and the endometrial epithelial cells, and the last, invasion phase. In man, the description of early implantation is still not well established but what is now certain is that it is the trophoblast, a direct descendant of the blastocyst cells which makes the first contact with the uterine epithelium during the attachment phase (Benirschke and Kaufmann, 2000; Ockleford *et al.*, 2004). The blastocystic trophoblast penetrates the endometrial epithelium by an invasive mechanism, completely burying itself in the maternal uterine endometrium. This type of implantation is called interstitial implantation and it is found in humans and in guinea pigs. Implantation is known to be most frequently on the upper part of the posterior wall, near the mid-sagittal plane of the uterus (Boyd and Hamilton, 1970). The portion of the endometrium (the decidua) in which the blastocyst is embedded soon becomes thicker than the other parts of the decidua and to distinguish them, these are given different names. The decidua between the zygote and the myometrium is called decidua basalis and the decidua between the conceptus and the uterine lumen is called the decidua capsularis. Once the conceptus has expanded to fill the uterine lumen the decidua capsularis meets tissue lining the uterus. This transforms into decidua parietalis and then decidua capsularis and parietalis merge (Boyd and Hamilton, 1970) see figure 1.0.

# Week 10 of Pregnancy



**Figure 1.1** Taken from Sargent (2008). “Molecular Mechanisms of Implantation”  
proceedings of Second EMBIC Summer School.

The type of placentation in which the trophoblast comes into direct contact with maternal blood supply is described as haemo-chorial (Benirschke and Kaufmann, 2000). The advantage of this mode of placentation is to establish the most intimate relationship between the developing embryo and the source of nutrition from the mother (Loke and King, 1995). Since the trophoblast that makes up the chorion is initially two cells thick and later for the most part a single cell layer thick the name can be extended as haemo-dichorial or haemo-monochorial.

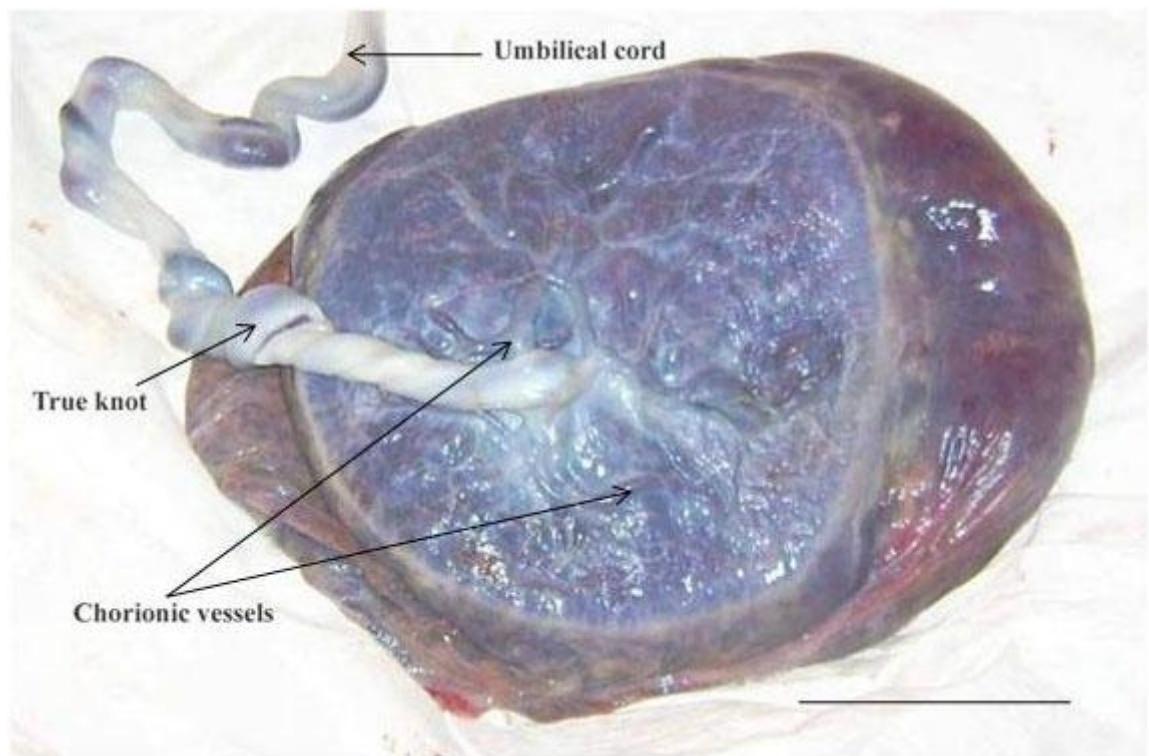


### **1.1.3 FORMATION OF VILLI**

The initiation of the embryonic circulation and the associated vascularization of the villi provide the effective basis for the establishment of a functional placenta (Boyd and Hamilton, 1970). At first, the whole of the membrane enclosing the conceptus has villous projections on its surface, the chorion frondosum. The chorionic villi, the basic structure of the early placenta, are formed during the 4<sup>th</sup> and 5<sup>th</sup> week post-menstruation (Boyd and Hamilton, 1970). A large portion of these villi are known to regress and the persistent part of the frondosum then become the placental disc. The resulting area of villous retrogression is smooth and this is called the chorion laeve. As early as the third week of development, the trophoblast become characterised by primary villi from the chorionic plate. The primary villus consists of a cytotrophoblastic core covered by a syncytial layer. As development continues with expansion of the implantation site, the primary villous stems increase in length and their cytotrophoblastic cores extend in a distal direction towards the region of attachment of the syncytium to the endometrium (Boyd and Hamilton, 1970). Mesodermal cells then penetrate the cytotrophoblastic core of the primary villi and the structures now formed are termed secondary villi. By the end of the third week, mesodermal cells in the secondary villi begin to differentiate into small blood vessels and blood cells, forming a villous capillary system (Boyd and Hamilton., 1970). The villi are now called tertiary villi or definitive placental villi. The embryonic vessels link with the vessels in the mesoderm of the chorionic plate and finally with the fetal vessels to establish the feto-placental circulation.

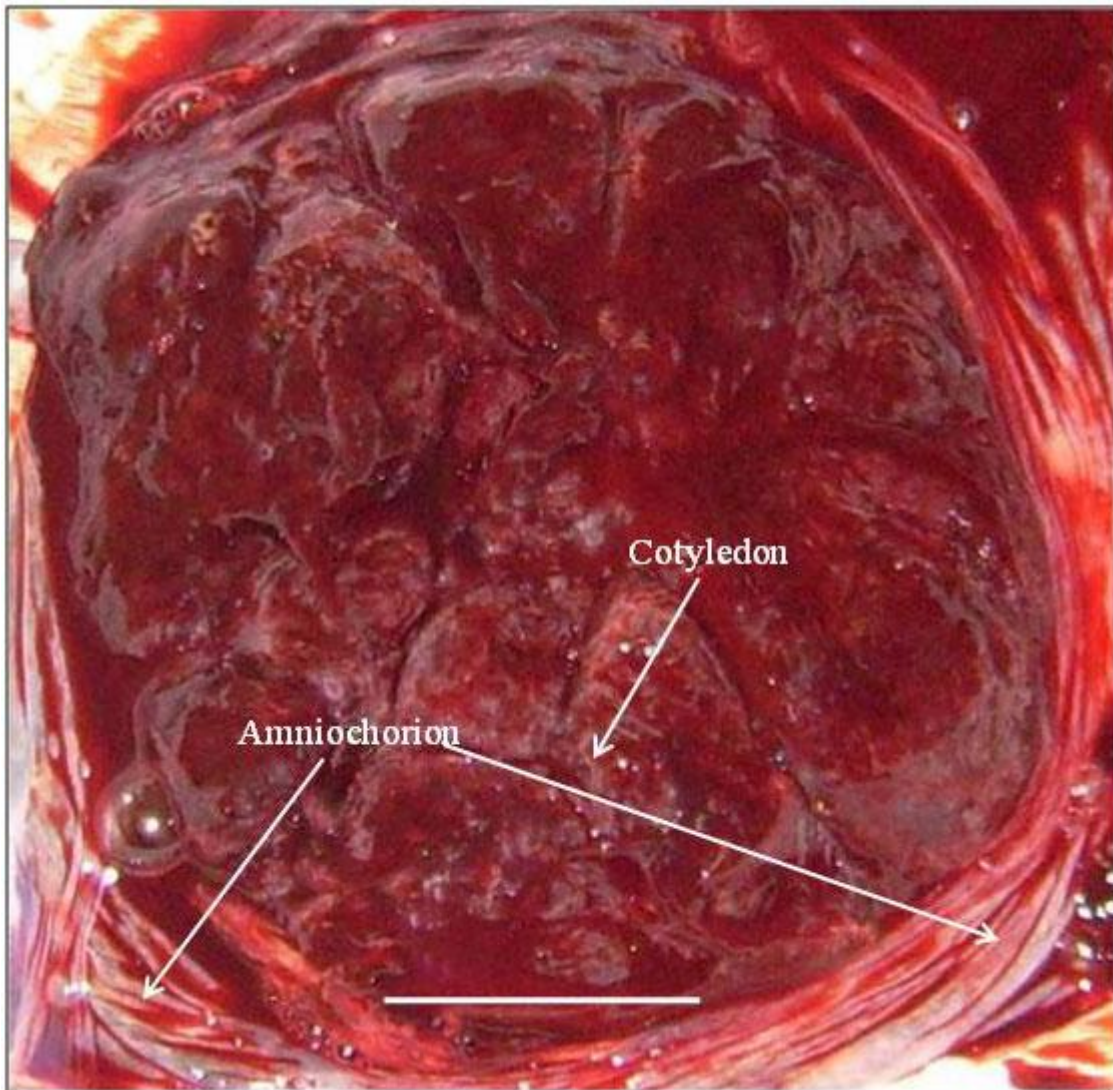
#### 1.1.4 THE FULL TERM HUMAN PLACENTA

At term, the human placenta is described as discoid in shape: it weighs about 300 to 600g with a diameter ranging approximately from 15 to 25cm (Sadler, 2000). The fetal surface of the placenta shows the umbilical cord inserted on the chorionic plate with chorionic vessels ramifying all over the surface. These vessels can be seen through the transparent amnion.



**Figure 1.2** The fetal surface of a freshly delivered human placenta. Scale bar = 10cm

The maternal surface of the placenta has numerous lobes (cotyledons). Each compartment or cotyledon is separated from the other by septae which are infoldings of the decidua basalis. A thin basal plate tissue covers the maternal surface when the placenta is delivered.



**Figure 1.3** The maternal surface of a freshly delivered human placenta. Scale bar = 5.0cm.

The human placenta according to Benirschke *et al.* (2006) at term is a local, disk-like thickening of membranes into two separate sheets, the chorionic plate and the basal plate. These two plates enclose a space, the intervillous space as a cover or top (chorionic plate) and a bottom, basal plate. The margins are obliterated such that the chorionic plate and the basal plate fuse with each other to form the chorion laeve. The intervillous space is

perfused with maternal blood directly around the trophoblastic surfaces of the villi. The villi are basically, complex tree-like projections of the chorionic plate into the intervillous space. Inside the villi are the fetal vessels that are connected to the fetal circulatory system via the chorionic plate and the umbilical cord.

The human placenta has been studied extensively over the years and some interesting findings suggest for instance that blood pressure and the risk of hypertension in adult life are predicted by a combination of placental weight and birth weight. The highest risk of hypertension was reported to be among people who were born small with large placentae (Barker *et al.*, 1990).

The field is still progressing actively as indicated by the recent demonstration of the presence of interstitial Cajal-like cells outside the gastrointestinal tract in the mesenchymal tissue of the villi from human term placenta (Suciu *et al.*, 2007). The authors suggesting possible roles like intercellular signalling, paracrine activity or immune surveillance for this type of cell in the placenta.

### **1.1.5 CHORIONIC VILLOUS TROPHOBLAST**

It is generally accepted that the human villous trophoblast is a continuously-renewing epithelium which consist of an inner proliferating mononuclear layer, the cytotrophoblast and an outer differentiated multinuclear layer, the syncytiotrophoblast. The villous cytotrophoblastic cells are progenitor cells that occupy a niche between the syncytiotrophoblast and the villous basement membrane (Jones and Fox, 1991).

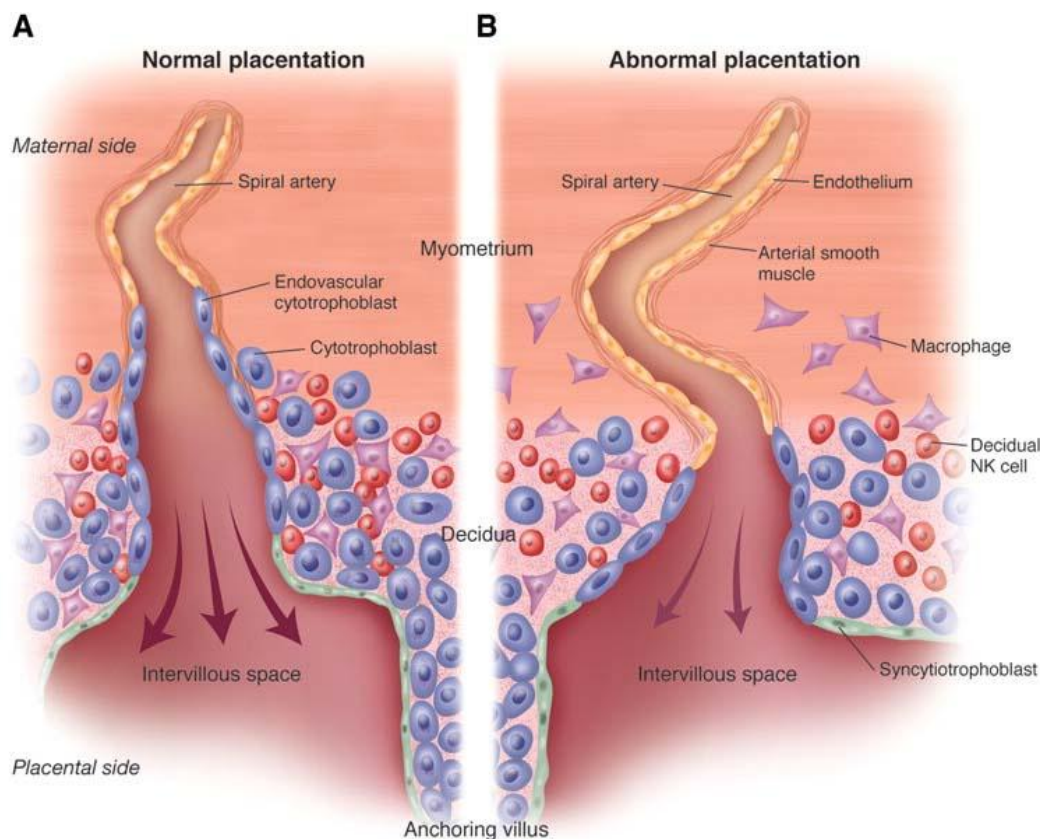
The syncytiotrophoblast is the epithelial covering of the villous tree and it is estimated to cover a surface area between 12 to 14m<sup>2</sup> at term without apparent lateral cell boundaries (Gaunt and Ockleford, 1986; Burton and Jauniaux, 1995). A conventional view of the cytotrophoblast layer over the course of gestation is that the layer transforms from a

continuous to an incomplete layer (Bright and Ockleford, 1995; Benirschke *et al.*, 2006). Dearden and Ockleford (1983) reported that the syncytiotrophoblast makes contact with the trophoblast basement membrane through cytoplasmic projections extending between the cytotrophoblastic cells, from the first trimester well into the second half of pregnancy. A report by Mori *et al.* (2007) who studied the structural integrity of the cytotrophoblast layer of human full-term placenta using advanced microscopy techniques with a specific antibody to SPINT1 (a hepatocyte growth factor activator inhibitor type 1) known to be expressed exclusively by the cytotrophoblast cells and not syncytiotrophoblast cells, showed that the layer becomes thinner and mostly continuous as opposed to the conventional view. Mori *et al.* (2007) estimated that at term the cytotrophoblast (CT) cells rather occupy approximately 80% of the epithelial surface, compared with 90% in the first trimester. The cells in this layer were reported to rather transform into flat cells with many cellular processes and together with those of the syncytiotrophoblast spread over the basal lamina in a series of complex interdigitations at term.

In a related work, Jones *et al.* (2008) used stereology and transmission electron microscopy coupled with immunofluorescence approach to study term placental cytotrophoblast. The authors reported the CT cells and their processes at term cover only 44% of the basal lamina surface with intervening regions occupied by syncytiotrophoblast. What is clear from the two studies is that the CT cells transform from cuboidal phenotype early in gestation to flattened cells with multiple interconnecting processes.

### 1.1.6 REMODELLING OF SPIRAL ARTERIOLES.

In normal pregnancies, the spiral arterioles are known to be invaded by endovascular extravillous trophoblast cells. The musculo-elastic media of the spiral arterioles of both the decidual segment and as far as the inner third of the myometrial segment are thought to be destroyed and replaced by the extravillous trophoblasts (EVTs). It is the alteration of the spiral arteries during pregnancy that has been described as “physiological change” (Brosens *et al.*, 1967; Pijnenborg *et al.*, 1980; Gerretsen *et al.*, 1981). Pijnenborg *et al.* (2006) have suggested that the term “physiological change” be replaced by “trophoblast-associated remodelling” as the latter is more appropriate to what actually occurs.



**Figure 1.4** Remodelling of spiral arterioles in two pregnancies.

(A) represents a normal placentation in which the spiral arteriole has been remodelled deep into the myometrial segment and (B) Poor placentation at 15 to 16 weeks of pregnancy in which the spiral arteriole has been partially remodelled up to the decidua. (Taken from Redman and Sargent, 2005).



Physiological changes that accompany early pregnancy are adaptations to the growing demand of the fetus for maternal blood. The vessels now have a wider bore allowing blood to flow under low resistance and pressure into the intervillous space (Gerretsen *et al.*, 1981). Deficient conversion of the spiral arteries into a wide bore, has been reported to result in the retention of more smooth muscle cells in the walls of the spiral arteries than normal and this has been proposed to lead to exaggerated intermittent perfusion of the placenta *in vitro* (Hung *et al.*, 2001).

#### **1.1.7 THE EXTRAVILLOUS TROPHOBLAST (EVT)**

The term extravillous trophoblast or extravillous cytotrophoblast is used as a general heading for the entire population of trophoblast cells residing outside the villi (Bernischke *et al.*, 2006). It is used to describe the topographical situation of these particular trophoblast cells in the chorionic plate, basal plate, cell column, cell islands, septae, and membranes (Bernischke *et al.*, 2006). EVTs may be further subdivided into “intra-arterial trophoblast” which refers to those EVTs present within the uteroplacental vessel lumen (Beck and Beck, 1967) and “interstitial trophoblast” comprising all the EVTs outside uteroplacental arteries (Pijnenborg *et al.*, 1980). In the junctional zone, it has been reported that definition of interstitial trophoblast includes intramural trophoblast cells, which are localised in the remodelled vessel wall of spiral arteries (Blankenship and King, 1993). Different populations of trophoblast are known to exhibit distinct morphological, immunophenotype and biological functions (Shih and Kurman, 1998; 2002; Shih *et al.*, 1999a, 1999b).

The structure of trophoblast cells is generally variable and these cells connect to each other by desmosomes (Bou-Resli *et al.*, 1981). It has been shown that desmosomes are found between cytotrophoblast cells and also between cytotrophoblast and syncytiotrophoblast interfaces (Metz and Weihe, 1980), at syncytial bridges (Metz *et al.*, 1979) and at the borders of microvilli membranes (Carter, 1964; Enders, 1965). The fact that cytokeratins play an important role in desmosomal junctional complexes, especially in trophoblastic cells, is important in this study. While some EVT's are proliferative, undifferentiated rounded cells with large, oval nuclei, scarce organelles that rest on basal lamina and are said to incorporate <sup>3</sup>H-thymidine (Kaltenbach and Sachs, 1979), others are nonproliferative, differentiated, large polygonal cells with highly irregular, invaginated nuclei and condensed cytoplasm, rough endoplasmic reticulum, lipid droplets, and glycogen.

The cytotrophoblast differentiates into intermediate trophoblast at the trophoblastic columns and then into extravillous trophoblast in the basal plate at the implantation site or chorionic-type intermediate extravillous trophoblast in the chorion laeve (Shih *et al.*, 1999b; Shih and Kurman, 2002). EVT's are essentially epithelial in origin and normal epithelia are known to either secrete extracellular matrix in a polarized manner (for instance to form a basal lamina) or to secrete no extracellular matrix at all (post proliferative cells of stratified epithelia). EVT's are reported to secrete extracellular matrix (Frank *et al.*, 1994; Huppertz *et al.*, 1996) and also fibronectin isoforms, collagen IV, laminins, vitronectins, and heparin sulphate along their invasive pathway (Bernischke and Kaufmann, 2000). The establishment of a successful pregnancy requires the proper invasion of EVT's into the uterine decidua and myometrial stroma (Pijnenborg *et al.*, 1980) but EVT's invasiveness when uncontrolled may proceed through the myometrium leading to placenta accreta (Goldman-Wohl *et al.*, 2000). Incomplete invasion and spiral



artery remodelling, it is claimed, potentially leads to a range of pregnancy complications which include miscarriages (Ball *et al.*, 2006), pre-eclampsia (Pijnenborg *et al.*, 1991), and fetal growth restriction (Khong *et al.*, 1986).

In term pregnancies, extravillous trophoblast shows considerably reduced proliferative activities unlike the situation in the first two trimesters of pregnancies (Benirschke and Kaufmann, 2000). The extravillous cytotrophoblastic cells which leave the cell columns and migrate into the decidua are known to exhibit some pseudo-malignant features (Fisher *et al.*, 1985; 1989; Ohlsson, 1989; Lala and Graham, 1990). The dominant integrin of the proliferating subset of trophoblast has been reported to be  $\alpha 6 \beta 4$  (Damsky *et al.*, 1992; Aplin, 1993) a usual basal lamina receptor. The gradual switch from the basal lamina receptor  $\alpha 6 \beta 4$  to interstitial receptors such as  $\alpha 5 \beta 1$  and  $\alpha 1 \beta 1$  integrins in normal intrauterine pregnancies is characteristic for the transition from the proliferative to the invasive phenotype of extravillous trophoblast which has been referred to as integrin switch (Bernischke and Kaufmann, 2000). Integrin switching has been a subject of interest because it is thought to be involved in the regulation of trophoblast invasion in the placental junctional zone (Aplin, 1993; Zhou *et al.*, 1993; Damsky *et al.*, 1993; Lim *et al.*, 1995).

Aplin *et al.* (2000) based on observations in explants model of anchoring villus development, proposed that two types of signals are required to trigger the entry of cytotrophoblast into the migratory extravillous lineage. The first is mediated by the contact of the tip of the mesenchymal villous with the decidual extracellular matrix. In response, the stem villous cytotrophoblast then undergoes a proliferative burst and differentiates into cytotrophoblastic cell column, anchoring peripheral villi to the uterus. Secondly, column stability is also dependent on the interactions between extracellular fibronectin and integrin  $\alpha 5$  and  $\beta 1$  expression at the cell surface, which are reported to be upregulated in this

pathway. Aplin *et al.* (2000) reported that cells detach from the periphery of the columns and become migratory infiltrative cells which depend on the paracrine signals from the mesenchymal cells beneath the villous basement membrane. During the course of differentiation, EVTs are known to acquire a distinct phenotype, losing some typical epithelial components like E-Cadherin, Integrin  $\alpha 6$  and  $\beta 4$  but retaining others like **cytokeratins** (Vicovac and Aplin, 1996). It has been reported that the secretions from the uterine glands contain a cocktail of growth factors, such as TNF- $\alpha$ , epidermal growth factor, colony stimulating factor and vascular endothelial growth factor (VEGF) which modulates trophoblast proliferation and migration *in vitro* (Lala *et al.*, 1998). Lash *et al.* (2006) showed that trophoblast invasion was inhibited by interferon-gamma, by increased EVT apoptosis and by reduced levels of active proteases.

#### **1.1.7.1 SOME FUNCTIONS OF EVTs**

##### **1) Invasion of maternal tissue:**

This process according to Bernischke *et al.* (2006) includes infiltration of maternal vessels, which is supported by the lytic activities of proteases.

##### **2) Anchorage of the placenta.**

Extravillous trophoblast anchors the placenta to the maternal tissues by secretion and continuous turnover of trophoblastic extracellular matrix which act as a kind of glue between cells of maternal and fetal origin (Feinberg *et al.*, 1991). It has been reported that these two functions of the extravillous trophoblast can be attributed to two morphologically different subtypes of cells. These are the highly invasive small spindle-shaped trophoblast and the non-invasive large polygonal trophoblast cells (Kemp *et al.*, 2002). In early implantation, the EVTs form a continuous shell at the level of the decidua and some of the

EVTs are known to form plugs in the tips of the utero-placenta arteries (Pijnenborg *et al.*, 1983; Burton *et al.*, 1999).

### **1.1.8 SOME FUNCTIONS OF THE HUMAN PLACENTA**

The human placenta performs a range of functions which includes nutrition, gaseous exchange, and transport of substances from mother to fetus and *vice versa*. Its role in the nutrition of the fetus and mediating the active transport of nutrients and metabolic wastes across the barrier separating the maternal and fetal compartments is essential for the growth of a healthy fetus (Garnica and Chan, 1996).

It has been reported that the fetus during the first trimester feeds histiotrophically under low oxygen conditions. Once this stage is complete, there is a transition to haemotrophic nutrition at the beginning of the second trimester when feto-maternal placental circulation is fully established and where fetal oxygen requirement is increased. How this switch in nutritional pathway might be regulated is unknown (Burton *et al.*, 2001). It has been suggested in recent years that at an earlier stage, only maternal plasma and uterine secretions perfuse the intervillous space because its vascular supply is initially plugged by extravillous trophoblast cells which acts like filters permitting a slow seepage of plasma into the intervillous space and true maternal blood flow does not become established until about the 12<sup>th</sup> week of gestation (Hustin, 1992; Burton *et al.*, 2001).

As an endocrine organ, the human placenta is known to produce a large number of hormones including growth hormones (GH) and insulin-like growth factor (IGF)-1, as well as their corresponding receptors (Bauer *et al.*, 1998). Many other hormones like human placental lactogen (hPL), human chorionic gonadotrophin (hCG), estrogens and progesterone, human placental growth hormone, human chorionic adrenocorticotrophin (hACTH) and relaxin are also produced by the placenta.

### **1.1.9 THE BASAL PLATE TISSUE**

Benirschke *et al.* (2006) defined the basal plate as the maternal aspect of the intervillous space and the most intimate and important contact zone of the placenta. The authors described it as a highly complex structure, because it is composed of various tissues, such as EVTs, endometrial stroma with its pregnancy-specific specialisation, fibrinoid, residues of degenerating villi and maternal vessels. Owing to the intimate relationship between the trophoblast shell and the surrounding endometrium, the early steps in the formation of the basal plate are known to couple with the mechanisms of implantation (Benirschke *et al.*, 2006). The trophoblast shell represents the invasion front of the blastocyst. The basal plate is therefore inclusive of the base of the intervillous space together with all placental and maternal tissues that adhere to it after parturition. The deeper tissue layer of the placenta site after parturition which remains in the uterus and is discharged as “lochia” shows a similar admixture of maternal and placental tissues (placental bed). *In situ*, the placenta bed and the basal plate are continuous and together comprise what is called the “junctional zone”. Therefore, the term “basal plate” is applicable only to the delivered placenta. The basal plate attaches the placenta to the endometrium and its position between the mother and foetus may suggest an involvement in immunological reaction between the two organisms (Boyd and Hamilton, 1970).

#### **1.1.9.1 GROWTH OF THE BASAL PLATE**

The mature basal plate is reported to be of a variable thickness, ranging from 100µm to 1.5mm (Bernischke *et al.*, 2006). The growth of the basal plate is lateral as well as in thickness due to the proliferation of EVTs originating from the cell columns. The basal plate has incomplete partitions between placental cotyledons. The partitions are called septae which are covered with trophoblast and contain a core of maternal tissue.

At term, the basal plate consists of layers which are usually difficult to identify in an undisturbed order (Bernischke *et al.*, 2006). These layers include:

**1) Basal plate syncytiotrophoblast / lining cells:**

This is the inner surface that faces the intervillous space. This area has previously been thought to consist of only one type of cells but recent work (Byrne *et al.*, 1998, 2001) showed that it is a mosaic of cells. Some areas of the lining cells are trophoblastic whilst others are endothelial and with yet other unknown components which are a topic of a current study. According to Benirschke *et al.* (2006), due to much tissue necrosis that occur when maternal and fetal cells come together in the basal plate, the necrotic residue of decidua and trophoblast are transformed into fibrinoid. Bernischke *et al.* (2006) reported that Grosser, (1925) was the first to describe the term “fibrinoid” as non fibrous, non cellular, somewhat homogeneous products in the placenta, which is derived from heterogeneous sources, such as the cellular secretion and cellular degeneration of unknown origin. Different types of fibrinoids have been described. One, fibrin-type fibrinoid is derived from the polymerisation of blood fibrinogen which lines the intervillous spaces in all locations where the syncytiotrophoblast layer is interrupted. The Rohr’s fibrinoid is less focal and replaces missing elements of the superficial layer of the basal plate syncytiotrophoblast.

**2) Extravillous trophoblast layer:**

This is the principal layer of the basal plate. It is highly variable in thickness ranging from 50µm to 1mm. It is composed of extravillous trophoblast cells, patches of fibrinoid; loosely arranged connective tissues admixed decidual cells of maternal origin, fibroblast-like cells and some macrophages. The number cells in this layer which are large granular

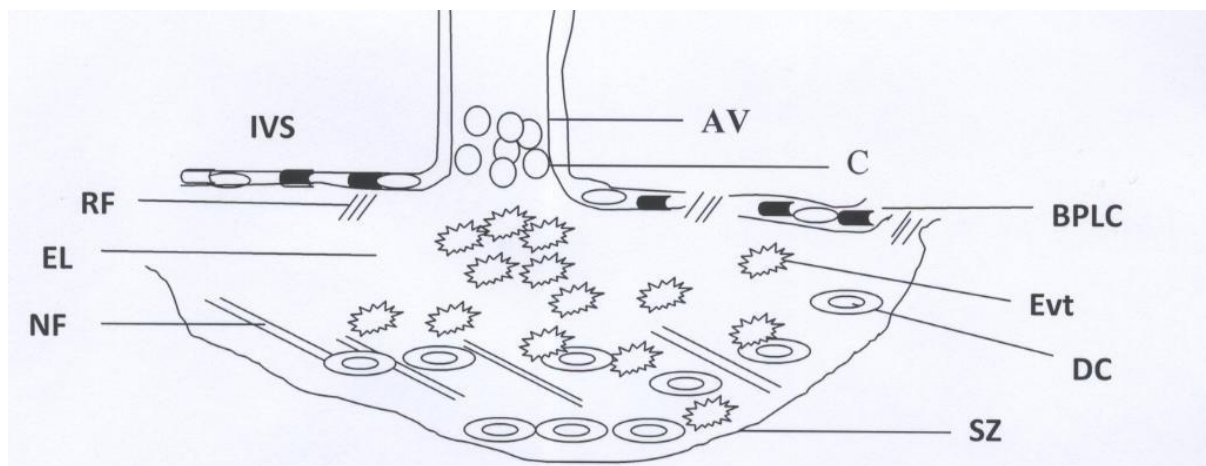
lymphocytes or uterine natural killer cells ((LGLs/uNK cells) may vary greatly as they may be absent or even in early pregnancy form the majority of cells. Their origin is not yet defined.

### 3) The Nitabuch's fibrinoid layer:

It is located in the immediate maternofetal “battlefield” of the junctional zone, a site of immunological processes and marks the exact maternofetal border with the trophoblast cells. It is superficially positioned compared with the more basally located decidual cells. However, mixed populations of the two cell types, trophoblast and decidua on one or both sides of the stria are commonest.

### 4) The separation zone:

This is the site of placental separation. It is the deepest part of the basal plate. Most cells in this area are decidual cells and other components of the endometrial stroma (Benirschke *et al.*, 2006).



**Diagram 1.1** A schematic drawing of the human placental basal plate tissue

IVS = Intervillous space, AV = Anchoring villus, C = Cytotrophoblast, RF = Rohr's fibrinoid, BPLC = Basal plate lining cells, ET = Extravillous trophoblast layer, Evt = Extravillous trophoblast, DC = Decidual cell, NF = Nitabuch's fibrinoid layer, SZ = Separation zone

## **1.2 HYPERTENSIVE DISORDERS IN PREGNANCY**

Hypertensive disorders complicating pregnancy are common and have been considered as one of the major causes of maternal and perinatal mortality and morbidity worldwide (Khan *et al.*, 2006). Examples of these disorders of pregnancy are pre-eclampsia and eclampsia. Eclampsia is defined as the occurrence of one or more convulsions superimposed on pre-eclampsia (Duley, 2003). Although eclampsia is rare in developed countries, it is reported to affect around 2,000 deliveries (Douglas and Redman, 1994) whereas in developing countries it is estimated to affect around one in 100 to one in 1700 deliveries (Crowther, 1985; Bergstrom *et al.*, 1992). Between the year 2000 and 2002, eclampsia accounted for 6% of direct maternal deaths in the United Kingdom (RCOG, 2004). Worldwide, it is estimated that half a million women die each year from various complications of pregnancy. Of these, about 50,000 women die annually following eclamptic convulsions, with nearly 99% of these deaths occurring in low and middle income countries (Duley, 1992). It is reported that pre-eclampsia-eclampsia may develop before, during, or after delivery (Witlin and Sibai, 1998) and deaths associated with the conditions may be due to cerebrovascular events, renal or hepatic failure, Hemolysis, Elevated Liver Enzymes, and Low Platelets (HELLP) syndrome, or other complications of hypertension (Mackay *et al.*, 2001). A recent report by Knight (2007) showed that the incidence of eclampsia and the proportion of women with eclampsia who experience further fits have decreased significantly since 1992. 37% of women had established hypertension and proteinuria during the week before their eclampsia, compared with 57% in 1992 as a result of the introduction of management guidelines for eclampsia and pre-eclampsia. This suggests that very few women who were managed with magnesium sulphate for pre-eclampsia went on to have an eclamptic fit.

### **1.2.1 PRE-ECLAMPSIA**

High blood pressure which develops alone after 20 weeks of gestation in a previously normotensive woman is defined as gestational hypertension (ACOG bulletin, 2002). It is generally shown to have a good prognosis but when the hypertension is accompanied by proteinuria it is classified as pre-eclampsia (Walker, 2000). Pre-eclampsia is reported to be a relatively common, dangerous, unpredictable, and a highly variable complication of the second half of pregnancy which causes variable maternal and fetal problems (Redman and Sargent 2000; 2005). It may threaten the survival of both the mother and baby and is found to be a significant cause of maternal and perinatal morbidity and mortality worldwide (Stone *et al.*, 1994). Pre-eclampsia can be subclassified into mild or severe, as well as early onset (before 34 weeks) and late onset (after 34 weeks) of pregnancy. The early onset type according to von Dadelszen *et al.* (2003) is usually associated with intrauterine growth restriction (IUGR).

### **1.2.2 ETIOLOGICAL THEORIES**

The etiology and pathogenesis of pre-eclampsia remains unclear despite several years of intensive research into the disease. Pre-eclampsia is reported to originate in the placenta, as the presence of a placenta is said to be necessary to cause the disorder (Redman, 1991). The fetus is not required to cause the disease as pre-eclampsia has been reported to occur with hydatidiform mole, a complication of pregnancy which is characterised by dysregulated trophoblast proliferation without a fetus (Borzychowski *et al.*, 2006). Roberts (1998) described pre-eclampsia as a “disease of theories” because of the confusion surrounding its cause and pathophysiology. The key features of the pathogenesis of pre-eclampsia according to Dekker and Sibai (1998) are shallow endovascular cytotrophoblast



invasion into the spiral arteries, an exaggerated inflammatory response, and inappropriate endothelial-cell activation.

Ness and Roberts (1996) proposed an hypothesis, namely that pre-eclampsia may be “placental”, caused by poor perfusion, or “maternal”, being the result of a maternal predisposition to arterial disease, later expressed in longer term problems such as atherosclerosis or chronic hypertension. In placental pre-eclampsia, there is an abnormal placenta in a normal woman whereas in maternal pre-eclampsia, there is a normal placenta within a woman who suffers from a pre-existing problem such as cardiovascular disease or diabetes (Borzychowski *et al.*, 2006). Some women are said to be more sensitive to endothelial dysfunction or have pre-existing endothelial dysfunction associated with a long-term tendency to such disease as hypertension or type 2 diabetes (Ness and Roberts, 1996).

### **1.2.3 ENDOTHELIAL DYSFUNCTION**

Normal functions of endothelial cells generally include: mediation of coagulation, platelet adhesion, immune functions, and control of vascular tone among others.

In pathological conditions, the characteristics of the endothelium change and become dysfunctional (Shimokawa, 1999; Boulanger, 1999). Endothelial dysfunction leads to impaired endothelium-dependent relaxation and results in the failure of vasoactive, anticoagulant, and anti-inflammatory effects of the endothelium (Rentzsch *et al.*, 2008). Placental endothelial cell dysfunction is accepted to be the common pathophysiological factor that contributes to the clinical syndrome observed in pre-eclampsia (Roberts *et al.*, 1989; Roberts and Cooper, 2001). Vascular endothelial growth factor (VEGF) is produced by the placenta. It is an angiogenic factor that also acts as a pro-inflammatory cytokine by increasing endothelial cell permeability. VEGF is a known intermediary of cell-mediated

immune inflammation. VEGF concentration has been reported to be elevated in preeclamptic women (McKeeman *et al.*, 2004).

An isoform of VEGF, VEGF<sub>165</sub> is known to increase the vascular leakage, induce vasodilation and promote angiogenesis (Ferrara, 2004) but another isoform VEGF<sub>165b</sub> has been shown to be up-regulated in the first trimester in pregnancies that will later be complicated by pre-eclampsia (Bills *et al.*, 2009). It is reported that sFlt-1 and sEng bind to VEGF/PlGF and prevent it from exerting its physiological effects (Levine *et al.*, 2006). It has been shown that sFlt-1 an anti-angiogenic molecule is able to induce a pre-eclamptic-like syndrome of hypertension and proteinuria when administered to pregnant rats (Maynard *et al.*, 2003; Mutter and Karumanch, 2008) whereas sEng an anti-angiogenic protein also inhibits transforming growth factor (TGF)  $\beta_1$  and  $\beta_2$  signalling and increases the severity of pre-eclampsia in pregnant rats treated with sFlt-1 (Venkatesha *et al.*, 2006). Endothelin, an endothelial-derived peptide which is a potent vasoconstrictor has also been reported to be produced by endothelial cells (Yanagisawa *et al.*, 1988a) and when the endothelium is damaged, it becomes a stimulus for endothelin synthesis and modulates smooth muscle  $\text{Ca}^{2+}$  (Yanagisawa *et al.*, 1988b).

It has been reported that secretion of factors by the placenta into maternal circulation, activates the vascular endothelium (Roberts *et al.*, 1989). Studies have shown that the serum from patients with pre-eclampsia show increased levels of circulating factors which are associated with endothelial injury. These include fibronectin, factor VIII antigen and thrombomodulin (Taylor *et al.*, 1991; Hsu *et al.*, 1993; Friedman *et al.*, 1995). It has been shown that there are high levels of circulating Von Willebrand factor, endothelin, and cellular fibronectin in the sera of pre-eclamptic women as a result of a damaged endothelium (Roberts and Redman, 1993; Nova *et al.*, 1991). Studies have shown that

endothelial dysfunction observed in pre-eclampsia, persists even beyond pregnancy (Lampinen *et al.*, 2006) which could increase the risk of hypertension, coronary and cerebro-vascular disease as suggested by epidemiological data (Wilson *et al.*, 2003).

Other data that support endothelial dysfunction include the decreased generation of endothelium-derived vasodilators such as prostacyclins and increased vascular sensitivity to angiotensin II and norepinephrine-mediated vascular constriction (Gant *et al.*, 1973; 1987; Mills *et al.*, 1999) all of these can have adverse effects on blood pressure. It has been found that circulating levels of nitrite are decreased in patients with pre-eclampsia, supporting the concept that diminished nitric oxide synthesis contributes to the pathophysiology of pre-eclampsia (Seligma *et al.*, 1994). However some workers report the reverse, that high levels of nitric oxide are produced in pre-eclampsia (Lyll *et al.*, 1995; Rowe *et al.*, 2003).

The etiology of pregnancy induced hypertension suggests a pathway that starts with inadequate trophoblast invasion of the maternal spiral arteries. This may lead to a decrease in placental perfusion (Gerretsen *et al.*, 1981). This situation will in turn lead to placental ischemia which will result in the placenta releasing some factors which include the pro-inflammatory cytokines TNF $\alpha$  and the interleukins (Redman *et al.*, 1999; Benyo *et al.*, 1997). A consequence of this is damage to the lining of blood vessels (Pijnenborg *et al.*, 1998) and subsequent maternal endothelial dysfunction, leading to a systemic vasoconstriction (Roberts *et al.*, 1991).

In a related hypothesis, Redman (1991) had earlier suggested that pre-eclampsia is a two stage disease. First, a poor placentation and secondly, the clinically recognisable maternal syndrome. The maternal syndrome of pre-eclampsia is reported to be caused by generalised maternal endothelial cell dysfunction which is part of a more global maternal systemic inflammatory response (Redman and Sargent, 2005). According to Redman and

Sargent (2000) these hypotheses give a clear explanation of the association between the medical conditions and pre-eclampsia.

#### **1.2.4 Inappropriate remodelling of spiral arteries in pre-eclampsia**

It has been reported that in pre-eclampsia, endovascular trophoblast does not invade the myometrial segment of the spiral arteries but rather the physiological change which occurs in normal pregnancies is restricted to the decidual portion of the vessels (Brosens *et al.*, 1972; Gerretsen *et al.*, 1981) see Figure 1.4. The absence of physiological changes in the spiral arteries is known to impede the blood supply to the placenta (Brosens *et al.*, 1972). In contrast another study found that remodelling of the spiral arteries is not restricted to the decidua portion alone but rather, 18% of the myometrial segments of the spiral arteries in pre-eclampsia were invaded by the endovascular trophoblast with reduced medial disorganisation and hyperplasia compared with 100% in the normal and 44% in the decidual segment with acute atherosclerosis compared with 76% in normal pregnancies (Meekins *et al.*, 1994). Pre-eclampsia has been associated with abnormally shallow placentation (Zhou *et al.*, 1998) and shallow trophoblast invasion (Caniggia *et al.*, 2000). However, clinical and basic research data suggest that maladaptation and malinvasion of the uteroplacental arteries which are characteristic of pre-eclampsia and intrauterine growth restriction (IUGR) result from a variety of factors which interact with each other in a cascade of events (Bernischke *et al.*, 2006). These factors have been reported to include an intrinsic abnormal biology of the extravillous trophoblast which act in concert with external maternal uterine denominators like impaired decidual remodelling (Aplin, 1991; Brosens *et al.*, 2002), macrophage-based defence mechanisms (Reister *et al.*, 1999), and maternal endothelial failure to express selectins (King and Loke, 1988; Burrows *et al.*, 1994).

### 1.2.5 TROPHOBLAST DEPORTATION

One hypothesis suggests that pre-eclampsia is the result of the deportation of syncytiotrophoblast microparticles (STBM) into the maternal circulation (Knight *et al.*, 1998; Johansen *et al.*, 1999; Sargent *et al.*, 2003). These particles are said to provoke a systemic inflammatory response in all pregnant women (Redman *et al.*, 1999; Redman and Sargent, 2000). The phenomenon of trophoblast “deportation” is not a new concept (Boyd and Hamilton, 1970) but has only recently been linked with disease.

The systemic inflammatory response is reported to be initiated by the interaction of the STBM with T cells (Gupta *et al.*, 2005) which are then taken up by maternal monocytes as demonstrated by *in vivo* and *in vitro* experiments which stimulates pro-inflammatory cytokine production (Germain *et al.*, 2007) and known to cause endothelial dysfunction (Smarason *et al.*, 1993; Cockell *et al.*, 1997; Gupta *et al.*, 2005). Aly *et al.* (2004) reported that in pre-eclamptic women neutrophils are stimulated to generate superoxide radicals by STBM. The syncytiotrophoblast (STB) nuclei which are formed from the underlying cytotrophoblast cells are known to be extruded into the maternal circulation as “syncytial knots” –( groups of heterochromatic nuclei which become closely packed and form raised structures on the apical surface of syncytiotrophoblast) . These are occasionally reported to lead to pulmonary emboli, which are eliminated by phagocytosis in the lungs (Bernischke and Kaufmann, 2000). Little is known about the mechanisms of release of placental debris, whether they come from syncytial knots or syncytial sprouts, their clearance and the ways in which the debris interact with the inflammatory network. Syncytial sprouts have been reported to more common in pre-eclamptic placentas (Aladjem, 1968) and according to Burton and Jones (2009a), it is more probable that sprouts may be dislodged more frequently due to the turbulent flow of maternal blood (Toal *et al.*, 2007) into placental lakes at the opening ends of spiral arteries and the

evidence that STB debris burden is increased when higher placental perfusion pressure are used *in vitro* (Crocker, 2007). According to Burton and Jones (2009a), it seems more likely that the most of the deported trophoblast debris may be “syncytial sprout” which may be necrotic in origin following ischemic injury. This, the authors suggested explains better the pathophysiology of preeclampsia.

The “deportation” hypothesis has been expanded by two models. The models both suggest that in all pregnancies, there is repair and renewal of the syncytiotrophoblast layer. One believes that this depends on apoptosis the other necrosis (Mayhew *et al.*, 1999; Huppertz *et al.*, 2003). It has been a subject of debate whether the process of renewal of the syncytial layer or trophoblast deportation is solely by apoptosis or necrosis. Huppertz *et al.* (2003), suggested that there may be a shift from apoptosis to necrosis under severe local hypoxic conditions. Thus the turnover of trophoblast may lead to incomplete execution of the apoptotic program and the subsequent degeneration via necrosis leading to the term “Aponecrosis” coined by Formigli *et al.* (2000). This process leads to the release of a continuous stream of placental microparticles into the maternal circulation. The released debris creates an inflammatory burden in maternal blood as a result of activating the endothelial cells which become damaged and dysfunctional (Roberts *et al.*, 1989). This is because microparticles according to Tannetta *et al.* (2008) are not inert but contain cell free surface proteins and cytoplasmic components of the cell of origin which can be pro-inflammatory and procoagulant. A feed-back mechanism where monocytes or granulocytes are activated and they in turn activate the maternal endothelium would lead to a body-wide systemic inflammatory response (Sacks *et al.*, 1998; Redman *et al.*, 1999). It has been shown that pulmonary endothelial cells become activated after phagocytosing necrotic trophoblast cells and not apoptotic ones. This is expected to lead to the release of Interleukin-6 (IL-6). This can then activate additional endothelial cells (systemic

endothelial activation) characteristic of pre-eclampsia but treatment of endothelial cells with vitamin C has been shown to prevent activation (Chen *et al.*, 2006; 2009).

It has been suggested that as a result of poor placentation and/or acute atherosclerosis leading to spiral artery insufficiency which occurs in pre-eclampsia, the placenta becomes oxidatively stressed. Hypoxia is known to encourage the release of apoptotic and necrotic trophoblastic debris in larger quantities in pre-eclamptic pregnancies than in normal pregnancies. Hence, there is a greater inflammatory burden in the maternal blood, which in turn exaggerates the activation of the endothelial dysfunction and leads to the maternal symptoms of pre-eclampsia. The increased shedding of cellular debris, which includes syncytiotrophoblast microparticles (STBM), cell-free DNA and mRNA, from the surface of the placenta (syncytiotrophoblast) in pre-eclampsia has therefore been reported to be caused mainly by placenta ischemia on one hand, reperfusion and oxidative stress on the other (Reddy *et al.*, 2008). Excess STBM shedding has been reported in early-onset pre-eclampsia (Goswami *et al.*, 2006).

The argument was strengthened by the previous work of Schrocksadel *et al.* (1993) who reported that there was an increased concentration of circulating markers of syncytial debris including **cytokeratin**, fetal DNA (Lo *et al.*, 1999) and the increased shedding of cellular syncytial fragments (Chu *et al.*, 1991; Johansen *et al.*, 1999). 3g of apoptotic syncytiotrophoblast are reported to be shed daily in the third trimester into maternal circulation when the rate of syncytial fusion exceeds the requirement for growth of developing placental villi (Huppertz *et al.*, 1998). Reddy *et al.* (2008) reported that labour and placenta separation appear to enhance the shedding of STBM and levels of placental cell-free corticotrophin releasing hormone mRNA in the plasma samples from pre-eclamptic labour which the authors suggested may play a role in cases of postpartum worsening of pre-eclampsia.

Redman and Sargent (2000) proposed that the key to understanding this pregnancy disease (pre-eclampsia) lies in the hypothesis above which is central to this current study.

A recent paper which challenges the current hypothesis of placental origin of pre-eclampsia (Huppertz, 2008) proposes that pre-eclampsia may develop at the onset of placentation and that it is as a result of failure of villous trophoblast differentiation, which on the placenta side may lead to abnormal release of trophoblast material into maternal circulation. The different scenarios are that in normal pregnancy the apoptotic programme continues until parturition where membrane-sealed corpuscular structures are apoptotically generated and released from apical syncytiotrophoblast membrane into maternal circulation. Macrophages are known to engulf these apoptotic materials, reducing the secretion of proinflammatory cytokines as the macrophages are silenced (Freire-de-Lima *et al.*, 2006; Krysko *et al.*, 2006) and this explains why the peripheral blood of healthy pregnant women is virtually free of apoptotic debris.

On the other hand, according to Huppertz (2008) during pre-eclampsia the release of syncytiotrophoblast material is altered and the mechanism is by necrosis and apoptosis (Formigli *et al.*, 2000). In his view the process releases necrotic and cell-free trophoblast materials which are termed STBM that are non-apoptotic and not membrane-sealed structures. The debris is therefore easily detected in peripheral blood of pre-eclamptic pregnant women and may cause systemic alterations of maternal endothelium and inflammatory system. It has been demonstrated however, that syncytial microparticles from shed primary trophoblast cultures contain abundant tissue transglutaminase (TGM2) which is known to cross-link with cytoskeletal proteins (actin, myosin, tubulin, cytokeratins) and stabilizes the particulate materials shed from the placenta (Robinson *et al.*, 2007). The modification of cytoskeletal proteins by TGM2 had earlier been reported



to stabilize apoptotic cells, preventing the release of cellular components into surrounding tissues, thereby circumventing inflammatory response (Piredda *et al.*, 1997).

Another support to the release of placental debris into maternal circulation is the oxidation stress that affects the human placenta (Redman *et al.*, 1999; Tjoa *et al.*, 2006). The human placenta is known to be exposed to major changes in oxygen concentration from conception to delivery (Jauniaux *et al.*, 2000; Burton *et al.*, 2003). The placental syncytiotrophoblast is particularly sensitive to oxidative stress, partly because it is the outermost of the conceptus and so exposed to the highest concentration of oxygen coming from the maternal blood (Jauniaux *et al.*, 2006). This has been explained from the view of incomplete conversion of the spiral arteries into wide-bore conduits. The arteries in this case are said to retain some smooth muscle cells within their wall such that some vasoreactivity are said to persist in about 30 -50% of the placental vascular bed (Jauniaux *et al.*, 2006). The situation may lead to intermittent perfusion which may result in transient hypoxia (Hung *et al.*, 2001) which may lead to a chronic injury (Jauniaux *et al.*, 2006). Jauniaux *et al.* (2006) asserted that a drawback of the haemo-chorial type of placentation is that inflammatory cytokines, soluble receptors, fetal DNA and trophoblastic debris can be released with ease directly into maternal blood and quickly distributed widely throughout the mother's body. Hung *et al.* (2002) demonstrated that hypoxia-reoxygenation *in vitro* is a powerful inducer of apoptosis in syncytiotrophoblast and the extent of apoptosis can be modulated by the addition of antioxidant molecules. Oxidative stress results in fragmentation of the syncytiotrophoblast apical membrane which allows the release of cytoplasmic contents into culture supernatant. When the production of highly reactive oxygen free radicals (OFRs) exceeds the natural cellular protection, serious damage is known to occur to proteins, lipids and cell DNA (Jauniaux *et al.*, (2006). OFRs have been shown to lead to the formation of lipid peroxides which

can alter cell membranes by increasing incorporation of cholesterol and oxidised free fatty acids (FFAs) and low-density lipoproteins (LDLs) (Hubel *et al.*, 1989).

Lipid peroxides are directly involved in mediating maternal endothelial dysfunction by increasing the production of thromboxane A<sub>2</sub> and the expression of cell adhesion molecules in the utero-placental and maternal peripheral vasculature (Uotila *et al.*, 1993; Walsh and Wang, 1995; Myatt *et al.*, 1996; Poranen *et al.*, 1996; Wang and Walsh, 2001). Of particular importance to this study, is that the human placenta is said to be sensitive to oxidative stress and that it leads to irreversible damage to the syncytiotrophoblast (Burton *et al.*, 2003), partly because it contains low concentrations of principal antioxidant enzymes (superoxide dismutase, catalase and glutathione peroxidase), particularly in early pregnancy (Watson *et al.*, 1998). The physiological hypoxia which occurs in the first trimester gestational sac protects the developing fetus against the deleterious and teratogenic effect of OFRs (Jauniaux *et al.*, 2006). During early placentation, the formation of the chorion laeve has been explained as owing to focal trophoblastic oxidative damage and progressive villous degeneration when a burst of oxidative stress was caused by local unplugging of the trophoblastic shell (Jauniaux *et al.*, 2003).

A continuum theory of pre-eclampsia (Redman and Sargent, 2000) implies that any factor that would increase the maternal systemic inflammatory response to pregnancy would predispose to pre-eclampsia. These factors the authors suggested were a large placenta; an abnormal stimulus from a small placenta; or an excessive maternal sensitivity to such stimuli. The stimulus should originate in the placenta and be released during all pregnancies and should be larger when the placenta is oxidatively stressed.

### 1.2.6 IMMUNE / IMMUNOGENETIC MALADAPTATION

This hypothesis according to Dekker (2002), immune maladaptation may, via an inappropriate decidual release of Th1 cytokines, proteolytic enzymes and free radicals species (Dekker and Sibai, 1998) causes both shallow invasion of spiral arteries by endovascular cytotrophoblast cells and systemic endothelial cell dysfunction. The core concept of immune maladaptation is the protective effect of regular sperm exposure over a prolonged period prior to conception and primipaternity (Dekker and Robillard, 2007). The term “primipaternity” which is the paternal factor in pre-eclampsia was introduced by (Robillard *et al.*, 1993). Ness *et al.* (2004) suggest that tolerance to paternal antigen, resulting from prolong exposure to sperm, protects against the development of preeclampsia. Major support for this hypothesis comes from various epidemiological studies. The most significant risk factors according to a review of literature on the subject are

- A history of pre-eclampsia and the presence of antiphospholipid antibodies (Duckitt and Harrington, 2005).
- Pre-existing diabetes and a pre-pregnancy body mass index (BMI) of  $\geq 35$  – this almost quadruples the risk;
- Nulliparity,
- Family history of pre-eclampsia,
- Twin pregnancy almost triples the risk
- Maternal age  $\geq 40$
- Systolic blood pressure  $\geq 130\text{mmHg}$ .
- Pre-existing hypertension,
- Renal disease,
- Chronic autoimmune disease,

- $\geq 10$  years between pregnancies increase the risk.
- Nulliparous women have been found to have a high risk of pre-eclampsia compared with multiparous women (Robillard *et al.*, 1993; Skjaerven *et al.*, 2002).

However, the protective cover which a multiparous woman will enjoy is reported to be lost when she changes her partner (Robillard *et al.*, 1993; Trupin *et al.*, 1996; Tubbergen *et al.*, 1999; Dekker, 2002). This might probably provide an explanation for the high frequency of pre-eclampsia in teenage pregnancies as reported by Marti and Hermann (1977). It has been found that nulliparous women who had an abortion with a different partner were at the same risk of developing pre-eclampsia as a primigravida (Dekker, 2002) but a nulliparous woman who had a previous spontaneous or induced abortion gains a substantial protection against pre-eclampsia in a pregnancy with the same partner. It has been shown that semen exposure over a long period decreases the risk of pre-eclampsia (Einarsson *et al.*, 2003). In a prospective study on the relationship between sperm exposure and pre-eclampsia, Robillard *et al.* (1994) showed that a short cohabitation is associated with an increased risk of pre-eclampsia (with women cohabitating for more than 12 months as their reference). They reported a cohabitation period of 0-4 months was found to be associated with an odds ratio of 11.6, 5-8 months period was 5.9 odds ratio, and an odds ratio of 4.2 for a period of 9-12 months for developing pre-eclampsia. In related study, a longer cohabitation with the use of condoms has been found to increase the risk of developing pre-eclampsia (Klonoff-Cohen *et al.*, 1989). Koelman *et al.* (2000) found that the frequency of oral sex or swallowing semen were significantly lower in pre-eclamptic cases compared with primipara normal pregnancy subjects. It thus appears that induction of oral tolerance by semen intake might partly reduce the risk of pre-eclampsia.

Although nicotine is a known neuroteratogen that has been associated with numerous effects on fetal brain development (Slotkin, 1998), evidence from a review of epidemiologic studies reports consistent reduction in the risk of pre-eclampsia in mothers who smoke (England and Zhang, 2007). Conde-Agudelo and Belizan (2000) reported a 30 to 40% decrease in the risk of pre-eclampsia with cigarette smoking but when taken in context of the harmful effect of nicotine on fetal growth and general well being, the benefit is cancelled out. It has been suggested that nicotine might mediate the inhibition of interleukin-2 and tumour necrosis factor production by mononuclear cells (Madretsma *et al.*, 1996; Redman *et al.*, 1999). Possible explanations are in relation to endothelial dysfunction. According to England and Zhang (2007) there is an inhibitory effect of nicotine on endothelial cell and neutrophil adhesion molecule expression which could decrease leukocyte-endothelial cell adhesion, thereby contributing to the protective effect of smoking against pre-eclampsia. It has been found from animal models that nicotine decreases leukocyte adhesion to uterine vascular endothelial cell and also inhibit endothelial cell surface intercellular adhesion molecule (ICAM) expression and neutrophil integrin expression of CD11a, and CD11b (Speer *et al.*, 2000; 2002). In black populations, it is reported that mutations in human leukocyte antigen (HLA)-G which is known to be expressed by EVT's could account for the high incidence of pre-eclampsia (van der Ken and Ober, 1994). Defective HLA-G function is said contribute to the low trophoblast invasion and vascular abnormalities observed in pre-eclamptic placentas (Le Bouteiller *et al.*, 2003).

### **1.2.7 GENETIC AND EPIGENETIC CONSIDERATIONS OF PRE-ECLAMPSIA**

Maternal and fetal genes, including paternal genes expressed in the fetus, have been reported to play a part or contribute to pre-eclampsia (Irgens *et al.*, 2001). The authors, using data from the Norwegian birth registry, also reported that women who had pre-eclampsia during a pregnancy that ends in preterm delivery had an eightfold higher risk of death from cardiovascular disease later on in life, compared with women who did not have pre-eclampsia and whose pregnancy goes to term. Ironically, fathers of pregnancies in which pre-eclampsia occurred have no increased risk of death from cardiovascular disease.

### **1.2.8 MANAGEMENT OF PRE-ECLAMPSIA**

At the moment there is no known cure for pre-eclampsia except the timely intervention of delivery (ACOG practical bulletin, 2002; Borzychowski *et al.*, 2006). The improvement of the patient following the removal of the placenta has reinforced the widely held belief that pre-eclampsia/ eclampsia are placental diseases and probably mediated by trophoblast. For many years, anticonvulsant drugs have been given to women with pre-eclampsia to reduce the risk of seizure (Roberts, 1995). Some of these drugs have been used over the years to manage pre-eclampsia and eclampsia. These include diazepam, benzodiazepine, phenytoin, barbiturates and magnesium sulphate (Gulmezoglu and Duley, 1998).

Magnesium sulphate is one among many drugs for which there is strong evidence of its efficacy, safety and also cost-effectiveness for the treatment of eclampsia and severe pre-eclampsia (The Eclampsia Trial Collaborative Group, 1995; The Magpie Trial Collaborative Group, 2002). The world health organisation (WHO) recommended magnesium sulphate as the most effective, safe and low-cost drug to treat eclampsia and

severe pre-eclampsia (WHO, 1994). Langer *et al.* (2008) commented that even though magnesium sulphate has been the standard treatment in developed countries for over 20 years, some developing countries still use less effective and even higher-risk drugs like diazepam and phenytoin. Some reasons that were identified as barriers for the use of magnesium sulphate especially in low income countries are the lack of licensing of the drug, difficulties due to import restrictions, poor incentive for local production and lack of political will among policymakers to promote the use of the drug locally (Aaserud *et al.*, 2005; Sevene *et al.*, 2005). Since women with pre-eclampsia have excessive production of thromboxane, a vasoconstrictor and platelet agonist, the potential use of Aspirin, a drug which has anti-platelet effect has been a subject of debate in the prevention and treatment of pre-eclampsia with regards to its benefits (Beilin, 1994; Bower, 1998; Duley, 1999; Duley *et al.*, 2001). Soluble VEGF receptor-1 (soluble fms-like tyrosine kinase 1, sFlt-1) and soluble placental growth factor (PlGF) have been identified as potential serum markers for pre-eclampsia (Levine *et al.*, 2004, Thadhani *et al.*, 2004). Bill *et al.* (2009) suggested VEGF<sub>165b</sub> as a useful clinical first trimester marker for increased pre-eclampsia risk. It is accepted that early detection, careful monitoring, and treatment of preeclampsia are crucial in preventing mortality related to the disorder (Mackey *et al.*, 2001, Dekker and Sibai, 2001).

### 1.3 CYTOSKELETON

The cytoplasm of eukaryotic cells is a well organised complex network of morphologically distinct protein filaments called the cytoskeleton (Alberts *et al.*, 2002). The cytoskeleton participates in several important cell functions like general motility, maintenance of cell shape, growth, cell division, secretion, adhesion, and cell-cell contacts. Bissel *et al.* (1982) proposed that there exists a “dynamic reciprocity” among several cellular compartments, the cytoskeleton and the nucleus matrix. This theory suggests that the extracellular matrix can exert physico-chemical changes via transmembrane receptors that influence the cytoskeleton. The cytoskeleton in turn alters the association of mRNA and other cytoplasmic structures with the cytoskeleton and ultimately alters the chromatin and the nuclear matrix. A similar cytoskeletal function as a linkage between the nuclear and the plasma membranes, permitting environmental stimuli acting at the cell membrane to be transmitted to the nucleus for initiation of an appropriate response has been proposed as a possible basis for constructing models of cellular transformation in cancer therapeutics (Scott, 1984).

The cytoplasm of animal cells is structured by scaffolding of three highly abundant principal protein types of filaments: microtubules, microfilaments, and intermediate filaments which help in the varied functions of the cytoskeleton. An important fibrous component of the cytoskeleton is the intermediate filaments (IFs). Different kinds of IFs share some basic characteristics. Their cytoplasmic filaments have an average of 10nm in diameter and are thus “intermediate” in size between actin filaments with an average of 8nm in diameter and microtubules which are 25nm. Cytokeratins/Keratins classified as Type I and Type II IFs, desmin, glial filaments and vimentin belong to Type III, neurofilaments (Type IV), and recently nuclear lamins (Type V). Lamin IF forms a network, the nuclear lamina, which supports the nuclear envelope. Desmin IFs are the



structural components of the sarcomere in muscle cells, whereas Vimentin IFs are found in fibroblasts and endothelial cells. Eye lens IF has been classified under Type VI intermediate filaments (Szeverenyi *et al.*, 2008).

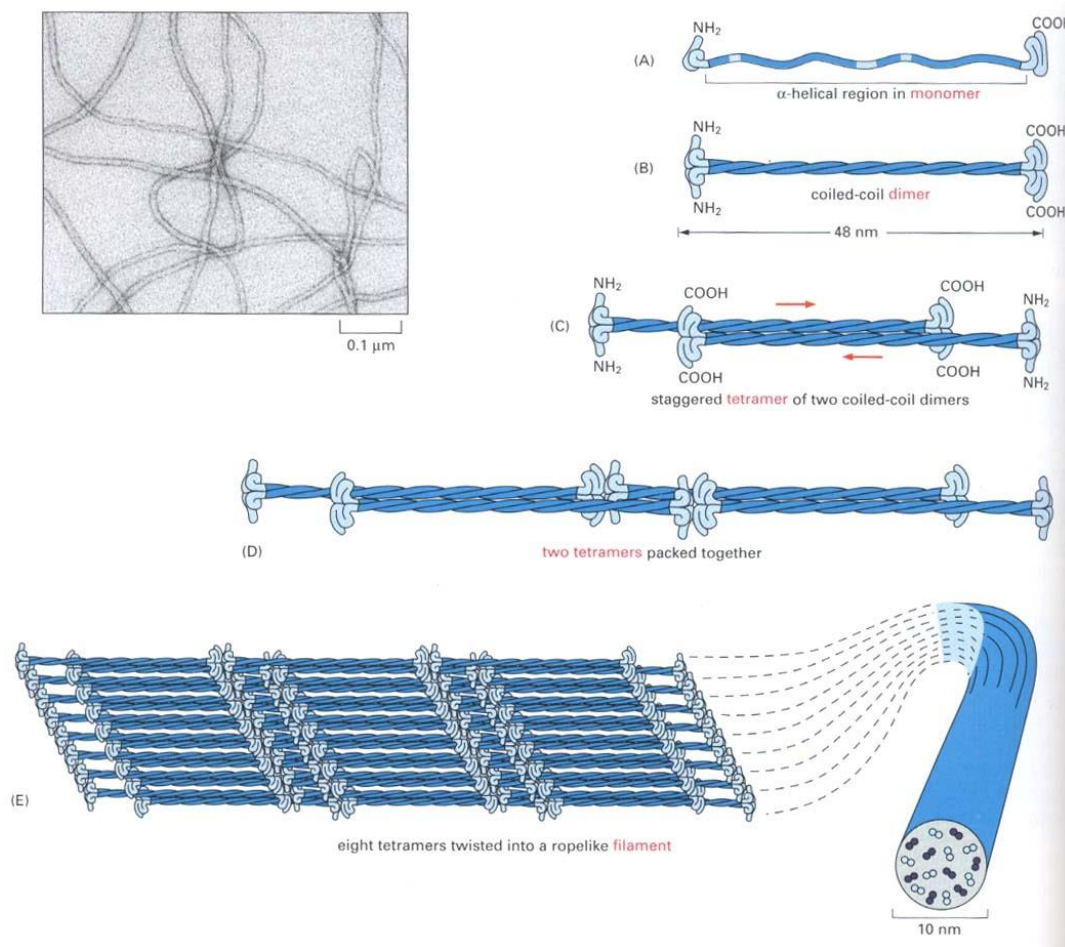
### 1.3.1 GENERAL STRUCTURE OF INTERMEDIATE FILAMENTS

The general structure of intermediate filament proteins domain structure is as follows:

NH<sub>2</sub>-E1-V1-H1-1A-L1-1B-L12-2A-L2-S-H2-V2-E2-COOH

(Taken from (<http://www.interfil.org/aboutDB.php> ).

- 1) A central rod domain comprising some 310 amino acids is predominantly arranged in coil-coiled  $\alpha$ -helices 1A,1B,2A,2B. These are divided by linker sequences L1, L12, L2. ( $\alpha$ -helices are a common secondary structure of proteins, characterized by a single, spiral chain of amino acids stabilized by hydrogen bonds).
- 2) An amino-terminal, non-  $\alpha$ -helical head domain of variable length E1; and
- 3) A carboxylic-terminal tail region E2 which is also not  $\alpha$ -helical and shows extreme length differences between different IF proteins (Geisler and Weber, 1982). The V1 (head) and V2 (tail) domains contains loose repeat sequence motifs and H2 (tail) and a variable stretch that contain phosphorylation target sites (Lane and McLean, 2004; Parry *et al.*, 2007).



**Figure 1.5** Formation of an intermediate filament: taken from Alberts *et al.* (2002).

IF proteins central  $\alpha$ -helical domain is flanked by a nonhelical head (an amino-end) and a tail (carboxy-end) domains. The rods of two polypeptide chains intertwine in a coil-coil dimer fashion which can then be staggered depending on the type of IF to form tetrameric structures and may further be packed into a rope like filament.

### 1.3.2 KERATINS (Ks)

Keratins are the major structural proteins in all epithelial cells and different epithelial tissues express different combinations of keratin protein (Moll *et al.*, 1982; Yamada *et al.*, 2002).

The keratin family is divided into two groups, the “Soft” keratins and the “Hard” keratins. The hard keratins are those used in the production of hair (trichocytes), nail, hoof and horn whilst the soft keratins or cyto-keratins are abundant in the cytoplasm of epithelial cells forming intracellular network of filaments of vertebrates (Coulombe and Omary, 2002). There are over twenty (20) distinct members of cytokeratins which have been identified and numbered by the pioneering work of (Moll *et al.*, 1982; 1990). Their molecular weight ranges between 40-68kDa and they have an isoelectric pH range between 4.9-7.8. Keratins were grouped into two (2) subfamilies, type I (“acidic”) and type II (“basic to neutral”) groups. Keratins **K1 to K8 or Hb** (basic hair) trichocyte keratins belong to the neutral –basic group whereas Keratin **K9 to K24 or Ha** (acidic hair) trichocyte keratins are classified under the acidic group. Keratin intermediate filaments are formed by the obligate polymerisation of type I and type II proteins, through the initial formation of heterotypic dimer (Hatzfeld and Weber, 1990) and subsequently through tetrameric complexes (Geisler and Weber, 1983; Quilan *et al.*, 1984) as the basic building block. This is a unique feature of keratins compared with other intermediate filaments.

Based on the new consensus nomenclature, it has been suggested that the term “keratin” (K) be used rather than the old “cytokeratin” (CK) and their gene designated KRT#; for example KRT1 represents keratin 1 gene (Schweizer *et al.*, 2006). Genome analyses have recently demonstrated that humans possess a total of 54 functional keratin genes

comprising of 28 type I and 26 type II keratins, which form two clusters of 27 genes each on chromosome 17q21.2 (type I keratin except K18) and 12q13.13 (type II keratins including K18) (Schweizer *et al.*, 2006). This large mammalian gene family led to suggestion of a revised nomenclature (Hesse *et al.*, 2001; 2004; Rogers *et al.*, 2004; 2005). However, owing to the extensive number of existing publications and for historical reasons, the Moll designation for the epithelial keratins has been retained. Several new keratins have been added to the cytokeratin catalogue such as keratin 20 (K20; Moll *et al.*, 1990; 1992), keratin 2e expressed in the upper epidermis, now designated K2, K2p for hard palate epithelium now K76 (Collin *et al.*, 1992a; 1992b) and keratin 6 which has several isoforms (K6a-h) (Takahashi *et al.*, 1995). Detailed classification of all keratin genes can be accessed at Human Intermediate Filament database at <http://www.interfil.org/aboutDB.php> Szeverenyi *et al.* (2009).

The 54 human keratins and their genes have been divided into three categories.

- Epithelial keratins/genes
- Hair keratins/genes and
- Keratin pseudogenes.
- A fourth category of non human epithelia and hair keratins of other mammalian species has been included.

These four categories are numerically arranged in both type I and type II Keratins as (1) Human epithelial keratins (2) Human hair keratins (3) Non human epithelial/hair keratins and (4) Human keratin pseudogenes (see Schweizer *et al.*, 2006).

Keratin expression is known to be usually regulated *in vivo* in a pairwise fashion such that specific combinations of type I and type II keratin genes are expressed in a tissue-specific and differentiation-specific manner and so they called “expression pairs” (Sun *et*

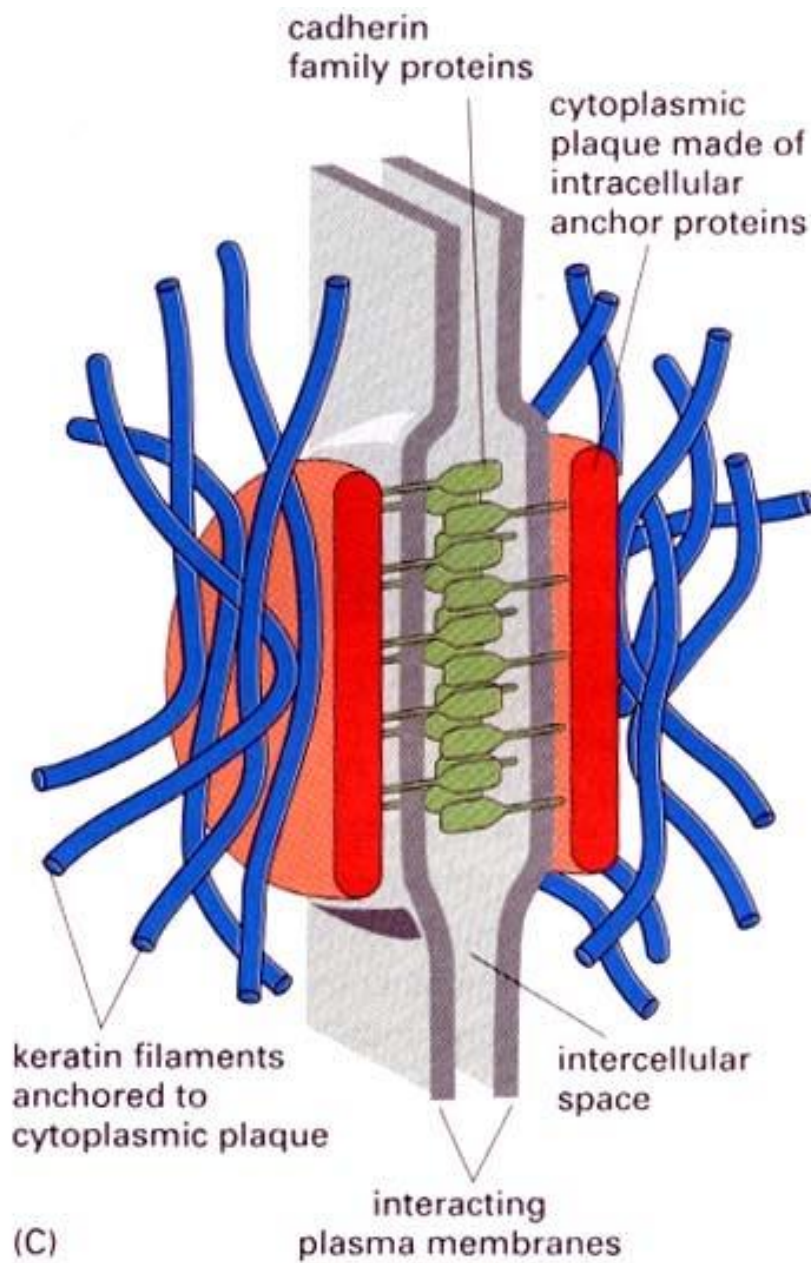
*al.*, 1984; Cooper *et al.*, 1985). It has been shown that type I and Type II polypeptides form *in vitro* and *in vivo* complexes that are remarkably stable to denaturing agents such as urea (Fuchs *et al.*, 1981; 1984; Crewther *et al.*, 1983) and according to Franke *et al.* (1983; 1984) the dissociation (“melting”) point of type I and type II keratins is a characteristic of a given pair. K18 (Type I) pairs with K8 (Type II), and K 19 (Type I) pairs with K7 (Type II), (Hutton *et al.*, 1998; Coulombe and Omary, 2002). They are known to be expressed in stoichiometric equal amounts in a tissue-specific and cell-type restricted pattern (Moll *et al.*, 1982; Fuchs and Weber, 1994). Hatzfeld and Franke (1985) showed that cytokeratin and IF formation *in vitro* requires the pairing of one representative of each type I and type II and can be between any members of the two subfamilies, suggesting that cytokeratins are “promiscuous”.

Keratin structures are based on rod-like subparticles (Fuchs and Weber, 1994) each single polypeptide chain has amino and carboxy-terminal domains of characteristic size, composition and sequence that are separated by an  $\alpha$  -helix-rich domain. There is a remarkably high amino acid identity in the alpha-helical rod within type I and Type II keratin sequences, which is not shared by their end domains. Two polypeptide chains spontaneously form coil-coil dimers in solution, by interfacing their respective apolar areas of the  $\alpha$  -helix (Fuchs and Weber, 1994; Klymkowsky, 1995 and Steinert and Roop, 1988). Thus keratin filaments occur in bundles containing two or more different keratins, which are necessary for the formation of polymeric filaments (Franke *et al.*, 1984). Keratin filaments are considered to be particularly important for the epithelial resilience to mechanical stress and they achieve this by forming stable networks which are attached to specific cell-cell contacts of desmosome type (Schmidt *et al.*, 1994; Bornslaeger *et al.*, 1996; Fuchs and Cleveland, 1998). Electron microscopy and immunofluorescence studies have shown that cytokeratin bundles contact the cell periphery at desmosomal plaques

and probably perform a mechanical function (Franke *et al.*, 1981; Geiger *et al.*, 1983; Mueller and Franke, 1983). They are also regarded as anchorage points between individual cells of a tissue, and able to distribute the mechanical stress applied to one cell among nearby cells and thus to the entire tissue (Cowin and Garrod, 1983; Pitelka *et al.*, 1983; Staehelin, 1974).

### **1.3.3 KERATIN AND DESMOSOMES**

A desmosome (or macula adherens) is a cell structure specialised for cell-cell adhesion. These structures are molecular complexes of cell adhesion proteins and linking proteins that attach the cell surface adhesion proteins to intracellular keratin cytoskeletal filaments. The cell adhesion proteins of desmosomes belong to the cadherin family of cell adhesion molecules. They are proteins that bridge the space between adjacent epithelial cells. Desmosomes linking proteins such as desmoplakin bind to the intracellular domain of cadherins and form a connecting bridge to the cytoplasm. Other adaptor proteins are plakoglobin, desmogleins and desmocoilins whereas filagrin binds keratin filaments in differentiating epidermal cells and plectin isoforms connect keratins to microtubules and actin filaments (Alberts *et al.*, 2002; Szeverenyi *et al.*, 2008).



**Figure 1.6** Taken from Alberts *et al.* (2002) showing cell-cell junction linked to keratin filaments.

Individual keratins bind to the desmoplakin component of desmosomes with varying affinity and structural requirements. Intracellular epithelial keratins such as keratin 5 (K5) and keratin 14 (K14) are reported to cross bridge desmosomal junctions, thereby providing structural continuity with the edge of epithelial cells (Meng J-J *et al.*, 1997; Smith and Fuchs, 1998). Cytotrophoblast cells are known to adhere to each other by desmosomes and other cell junction proteins (Harris *et al.*, 2009).

Hemidesmosomes on the other hand, are very small stud-or rivet-like structures on the inner basal surface of the cell. They attach one cell to the extracellular matrix. They use integrin cell adhesion proteins rather than cadherins (Alberts *et al.*, 2002). It is reported in a review (Moll *et al.*, 2008) that in non-stratified (simple) epithelia of internal parenchymatous organs, which experience little mechanical stress, few “simple epithelial keratin” members like K8/K18 and K19 form loose filaments, distributed in the cytoplasm. Otherwise, more keratin members take part in the filament cytoskeletal composition of squamous epithelia which even increases in the cornified stratified epithelia such as the epidermis which are built up from keratinocyte-type keratin like K5/K14 usually in the basal layer with more pronounced bundling, followed by K1/K10 in the suprabasal layers and K2/K10 in the uppermost layer. Therefore, the contribution of keratin intermediate filaments to the stability and integrity between epithelial cells and also to the basement membrane cannot be overemphasised.



### 1.3.4 KERATIN ASSOCIATED DISEASES

One of the first keratin diseases to be identified in 1991 was the mutations in both K5 and K14 genes (Epidermolysis bullosa simplex) of which there are many subsets. This disease renders the basal epidermal keratinocytes less resilient to trauma which results in skin fragility (Bonifas *et al.*, 1991; Coulombe *et al.*, 1991; Lane *et al.*, 1992). In human pathology, it has been reported that defects in K8 and K18 may predispose to liver disease, in particular cryptogenic liver cirrhosis (Ku *et al.*, 2003; Zatloukal *et al.*, 2004). The pemphigus family of human autoimmune blistering disease (for example, Pemphigus vulgaris, Pemphigus gestationis) are another group in which autoantibodies against keratinocyte cell surface cause loss of cell-cell adhesion, resulting in blister formation (Stanley, 1989). Several other details of keratin diseases are updated at <http://www.interfil.org/diseaseTypeInII.php>.

### 1.3.5 OTHER FUNCTIONS OF KERATINS

We have had to extend our view that keratin is simply a structural protein of the cytosol. In mice, it has been shown that keratins perform other functions which include the protection of the placental and trophoblast barrier (K8/K18/K19: Hesse *et al.*, 2000; Jaquemar *et al.*, 2003). The deletion of keratin 18 and 19 was found to lead to trophoblast giant cell fragility and causes embryonic lethality between E9.0 and E9.5, which according to Hesse *et al.* (2000) means that the absence of keratin filaments in the trophoblast giant cells caused a drastic reduction in the number of desmosomes. Hence these cells are not protected from mechanical stress and because of their large size, trophoblast cells seem to rely on their keratin cytoskeleton to withstand mechanical stress.

Baribault *et al.* (1993) also reported that K8-deficient mice die from a liver defect at around E12.5 and may also suffer from colorectal hyperplasia. This view has however

been disputed by some worker in the field (Magin *et al*,1998; Harada *et al.*, 1999) who reported the lack of phenotypic abnormalities in embryos of mice deficient for K18 or K19. They explained that the two keratins are able to replace one another.

Recent work shows for instance that Keratin 1 is a component of the multiprotein kininogen receptor complex on endothelial cells (Schmaier, 1998; Shariat-Madar *et al.*, 1999) and K8 has been reported to be a receptor for plasminogen and tissue plasminogen activator (Hembrough *et al.*, 1996). Endothelial cytokeratin 1 (K1) expression has been shown to significantly increase after oxidative stress compared with normoxic human umbilical vein endothelial cell (HUVEC) cultures and has a role in immune responses via the lectin complement pathway (LCP) after oxidative stress (Collard *et al.*, 2001). Collard and his colleagues showed that K1 mRNA and protein expression, mannose-binding lectin (MBL) binding, and C3 deposition are increased after human endothelial oxidative stress in vitro. They also showed that inhibition of MBL deposition with GlcNAc or anti-human MBL mAb attenuates MBL and C3 deposition on purified K1 and the finding that anti-human cytokeratin Fab fragment attenuates endothelial MBL and C3 deposition after oxidative stress. They suggested from these results that MBL deposition and activation of LCP after oxidative stress may be mediated by endothelial cytokeratins. Keratins may have a link with pre-eclampsia, which is essentially an endothelial related disease under hypoxic conditions. Their role in epithelial polarity and membrane traffic has been reported (Oriolo *et al.*, 2007). Therefore, keratins do more than just undertaking structural or mechanical functions. It is also believed that keratins (K17) could be involved in regulation of protein synthesis and cell size during wound healing involving intracellular signalling pathways (Kim *et al.*, 2006). Luna and Hitt (1992) reported the possible involvement of keratins in the transduction of signals and transport of nutrients from inside to the outside of the cell and vice versa due to the fact that they are connected at one end to lamins of the nuclear

envelope, while at the other they interact with the plasma membrane proteins. The membrane proteins in turn interact with extracellular matrix proteins. The role of keratins in programmed cell death (apoptosis) has been reported, that epithelial cell lines deficient in K8 and K18 intermediate filaments are more sensitive to apoptosis induced by the combination of tumour necrosis factor (TNF) to its receptors (K8: Caulin *et al.*, 2000; K18: Ku *et al.*, 2003). K8 and K18 have been found to bind to the cytoplasmic domain of TNFr2 and the lymphotoxin- $\beta$  receptor (LT Br) but not TNFr1 or Fas (Oshima, 2002) co-localization of TNFr2 and K8 and K18 was detected at the cell periphery. Rasmussen *et al.* (1999) have also reported K8 protection against Fas mediated apoptosis of hepatocytes and Caspase cleavage at the L1-2 linker region which has been confirmed for K14, K17 and K19 (Ku *et al.*, 2001). Epithelial tumours, including metastases are known to most widely retain the keratins of their normal epithelial origin and this has been exploited in many pathology laboratories for immunohistochemical typing of carcinomas in tumour diagnosis (Moll *et al.*, 2008). A clinical application is the detection of soluble keratin protein fragments derived from K8, K18, and K19 in the blood of cancer patients to monitor tumour load and even assessing the type of chemotherapy-induced tumour cell death by distinguishing between apoptosis and necrosis (Linder *et al.*, 2004, Linder, 2007).

### 1.3.6 REGULATION OF TRANSCRIPTION OF KERATIN GENES

It has been demonstrated that nuclear receptors for retinoic acid and thyroid hormone regulate keratin gene synthesis by binding to negative recognition elements in the upstream DNA sequence of the keratin genes (Tomic *et al.*, 1990; Blumenberg *et al.*, 1992). Some associations have been made between keratin genes and specific phases of skin growth like K1 and K10 associated with epidermal differentiation; K6a, K16, and K17 are associated with epidermal proliferation and wound repair; and K5 and K14 are expressed at the basal skin layer where their expression decreases as the skin cells differentiate (Fisher *et al.*, 1995; Paladini *et al.*, 1996; Freedberg *et al.*, 2001). According to Blumenberg *et al.* (1992) the way in which retinoic acid interacts with the epidermis is important because vitamin A derivatives are used as therapy for various skin disorders.

K6a knockout mice experiments have shown that the absence of K6a resulted in diminished superficial wound healing (Wojcik *et al.*, 2000), whereas when K16 was over expressed in cultured human keratinocytes, proliferation was shown to be enhanced (Paramio *et al.*, 1999). Safer *et al.* (2004) demonstrated that thyroid hormone ( $T_3$ ) exerts influence by stimulating expression of wound-healing keratin genes. The authors suggested surgical patients should have their thyroid status ascertained and their data support the introduction of  $T_3$  treatment during perioperative period.

### 1.3.7 KERATINS AND THE HUMAN PLACENTA

It has been reported that the first intermediate filaments to be synthesised during early development are the keratins and considering that placenta trophoblast is derived from cells of epithelial origin, keratins are reported commonly found in these cells (Hesse *et al.*, 2000; Babawale *et al.*, 2002). Keratin antigen is expressed by all cells of epithelial origin like amniotic epithelium. Cytokeratin antibodies are said to be the most suitable marker among many markers for the distinction of extravillous trophoblast cells from decidual cells, since all cells of decidual origin (decidual cells, endometrial stroma cells, macrophages, lymphocytes, natural killer cells) are cytokeratin negative (Benirschke *et al.*, 2006). Daya and Sabet (1991), first report on the relevance of using intracellular cytokeratins as markers for trophoblast cells unlike human chorionic gonadotropin (hCG) and human placental lactogen (hPL), which stain only the syncytiotrophoblast and intermediate trophoblast, cytokeratin were found to stain all three types of trophoblastic tissue. Cytoskeletal markers of extra-embryonic membrane epithelia to 10nm diameter bundles of intermediate filaments which are comprised of cytokeratins were first reported by (Ockleford *et al.*, 1981a;1981b; Ockleford *et al.*, 1984; Ockleford *et al.*, 1990) whereas the use of anti-cytokeratins were recognised as useful ectodermal lineage markers and became widely used to assist identification of cell populations in the human placental basal plate tissue (Byrne *et al.*, 1998; 2001). Several authors have reported that cytokeratin 7 (K7) intermediate filament in particular is highly expressed throughout the trophoblast lineage and the fact that trophoblast does not express vimentin (Haigh *et al.*, 1999; Blaschitz *et al.*, 2000). K7 has been suggested as the most specific intracellular marker for purity of human villous trophoblast cells (Pötgens *et al.*, 2001; Maldonado-Estrada *et al.*, 2004). Benirschke *et al.* (2006) reported that anti-cytokeratin 7 is the only trophoblast marker that does not cross react with contractile mesenchymal cells

(myofibroblasts and some smooth muscle cells). It has been demonstrated that K17 gene is strictly regulated in trophoblast subpopulations and distinctively expressed in intramural trophoblasts in first trimester pregnancies (Pröll *et al.*, 1997), suggesting this is a useful immunohistochemical marker for this group of cells. Loke and King (1995) reported that the interstitial extravillous trophoblastic cells which invade the spiral arteries have a curious distribution of keratin filaments which probably prevent the collapse of the cell.

There are a few other data which have been documented regarding the expression profile of keratins in the human placenta (Clark and Damjanov, 1985; Bulmer and Johnson 1985; Khong *et al.*, 1986; Yeh *et al.*, 1990; Muhlhauser *et al.*, 1995; Neudeck *et al.*, 1997) at various stages of pregnancy. However, these authors have not examined the differential expression of single keratins in the CVT and EVT of the basal plate tissue at term in healthy and in disease states, which is the main object of this thesis.

Muhlhauser *et al.*, (1995) reported that the proliferative and differentiation processes of the human chorionic villous and extravillous trophoblast are accompanied by alterations in the keratin pattern of expression at various stages of pregnancy. This view has been further exemplified by the work of Ockleford *et al.*, (2004), who reported an observed reduction of anti-pan cytokeratin (K4, 5, 6, 8, 10, 13 and 18) immunofluorescent reactivity of both EVT and CVT cells in pre-eclamptic placentae as compared with healthy placentae and also an upregulation of anti-pancytokeratin immunofluorescence in the EVT compared with CVT in both pre-eclamptic and healthy placentae. Ockleford *et al.* (2004) proposed that any attempt to explain the probable cause of pre-eclampsia should include the cytoskeletal dysregulation hypothesis which predicts a fall in keratin in the trophoblast because keratin filaments are a key component of the apical syncytioskeleton of the term placental villus tree surface.

This leads to a proposed first hypothesis that a weaker syncytioskeleton, will facilitate greater deportation of placental debris. In their prediction, Redman and Sargent (2000) relate increased trophoblast deportation in maternal circulation to pre-eclampsia. Earlier I described how “toxic trophoblast” causes an increased vascular inflammatory reaction compared with that of healthy mothers when it is released into the circulation.

A second hypothesis is that, increased specific keratins (as opposed to pan-cytokeratin), measured by the intensity of immunofluorescence in the trophoblastic cells will correlate with the anchorage phenotype of extravillous trophoblastic cells in the basal plate.

#### **1.4 CONFOCAL LASER SCANNING MICROSCOPY (CLSM)**

The confocal laser scanning microscopy technique is an advanced form of fluorescence microscopy. According to Sheppard and Shotton (1997) the idea for a confocal microscope technique was first patented by Minsky in as far back as 1957 but the first analogue mechanical confocal microscope was designed and produced by Eggar and Petran, ten years later.

With the advent of computers and lasers, coupled with digital image processing software, single-beam confocal laser scanning microscopes were developed and applied to biological and material specimens. The first commercial confocal laser scanning fluorescence microscopy systems were produced by Bio-Rad Microscience Ltd in Oxfordshire, UK (Sheppard and Shotton, 1997).

The most important advantage among several others, is the fact that out-of-focus blur is essentially absent from images obtained by confocal microscopy. This allows for a direct non-invasive serial optical sectioning of intact and living specimens. This confers the ability to obtain a time-series of three-dimensional images or data from a living specimen with quality temporal and spatial resolutions. This was previously impossible to obtain using conventional flood-beam fluorescence microscopy.

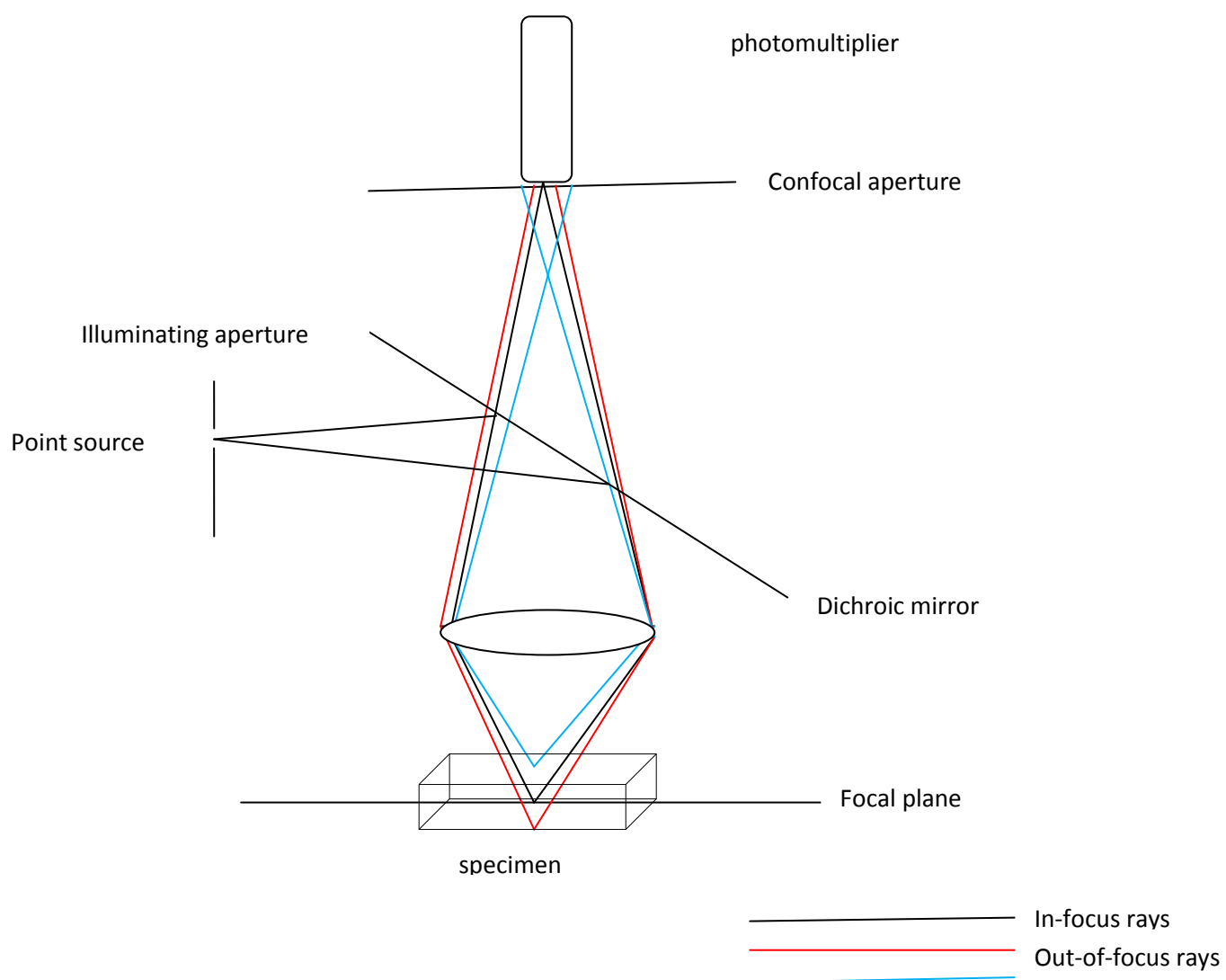
In confocal laser scanning microscopy, the illumination of the specimen is restricted to a single point (the laser beam) which is scanned to produce a complete image with a high resolution. It rejects stray light not only from out-of-focus specimen planes but also light scattered from the optical instrument itself. By contrast, conventional epi-illumination light microscopy stimulates illumination of the entire field of view of a specimen with



fluorescence emissions or reflections throughout the whole depth of the specimen rather than just at the focal plane. Since much of the light collected by the objective lens to form the image by epi-fluorescence light microscopy comes from regions above and below the selected focal plane, it contributes to the out-of-focus blur reducing the resolution of the final image. The CLSM is compatible with computers and therefore various quantifications can be performed on captured digital images and stored safely. One disadvantage of confocal laser scanning microscopy is photobleaching. Increased laser exposure or intensity quickly saturates the fluorochrome used (drive all the molecules into the excited state) affecting the linearity of the signal over the range of intensities of illumination.

#### 1.4.1 PRINCIPLE OF CONFOCAL FLUORESCENCE MICROSCOPE

Fluorescent light is emitted by an excited fluorochrome molecule located at the single diffraction-limited point that is illuminated in the focal plane. The light is collected by the lens (which acts as both condenser and objective lens) and is brought to a focus at an aligned confocal aperture in the primary image plane of the objective. The confocal aperture ensures that only light emanating from the in-focus plane is fully detected by the photomultiplier tube whilst preventing illumination from other regions of the specimen from reaching the photomultiplier detector and contributing to the image. Scattered illuminating light is prevented from contributing to the final image by a system of wavelength selective dichroic filters that separate the usually shorter wavelength illuminating beam from the longer wavelength emitted light from the fluorochrome



**FIGURE 1.7** A schematic drawing of the principles of confocal laser scanning microscopy adapted from Shotton (1988).

## 1.5 LASER CAPTURE MICRODISSECTION (LCM)

The idea of LCM was conceived and first developed as a research tool at the National Institute of Health (NIH) in 1996, through a collaborative research and development agreement partnership with Arcturus Engineering (Mountain View, CA). A prototype was then developed into a commercial instrument (Bonner *et al.*, 1997). Emmert-Buck *et al.* (1996) reported that the most sophisticated genetic testing method will be of limited value if the DNA, RNA, or proteins are not derived from pure populations of cells.

LCM is essentially a rapid way to procure pure populations of targeted cells from specific microscopic region of tissue section. Although manual microdissection can achieve quite good precision, it has its own range of problems. It is time-consuming, labour-intensive, and requires a high degree of manual dexterity (Emmet-Buck *et al.*, 1996).

Emmet-Buck *et al.* (1996) developed the laser capture microdissection system which basically entails placing a thin transparent film over a tissue section, visualising the tissue microscopically, while selectively adhering the cells of interest to the film with a fixed-position. This is done for a short duration and focusing the pulse from an infrared laser. The film with the procured tissue is then removed from the section and placed directly into a DNA, RNA, or enzyme buffer for downstream processing. The handling of transfer films has recently been simplified by bonding the film to a float or conical vial cap. This allows multiple homogeneous samples within tissue sections or cytological preparations to be targeted and pooled for extraction of molecules for analysis.

The system according to Tangrea *et al.* (2005) uses a near infrared gallium arsenide laser diode integrated into an inverted compound microscope with alignment into the optics subsystem. The cap has a thin layer of thermoplastic polymer film containing an infrared-absorbing dye (ethylene vinyl acetate polymer).

A robotic arm of a given microscope precisely positions the transfer film onto the tissue on a slide and the microscope focuses the laser beam to discrete focal volumes, delivering precise pulsed doses to the targeted film. The targeted cells are then transferred to the cap surface and the cap is gently placed onto the vial for molecular processing. The laser beam diameter in the mid-focal plane ranges between 7, to 15 and 30 $\mu$ m. This can be adjusted by varying the power (in milliwatts) and the timing (microseconds) of pulses. Single cells can be individually targeted and transferred from a complex tissue provided the cells of interest can be clearly identified. The cell(s) can be chosen on the basis of their morphology or following immunocytochemical staining or in-situ hybridisation, which can direct the capture of cells of a defined phenotype.

The system has a software that has the ability to capture images before and after microdissection and also records the appearance cells that have been captured in the cap (see Figures 3.30-3.33). This is a useful tool in recording accurately a record of each micro-dissection against any subsequent molecular results.

### **1.5.1 Advantages of LCM over conventional microdissection**

1. It is simple, easier and faster
2. It does not involve manual microdissection or manipulations
3. The transferred tissue on the film retains its original morphology which allows microscopic verification of the specificity of the captured materials
4. The potential disadvantage of manual microdissection where fragment of the tissue can detach from the tool and contaminate adjacent dissections is not encountered in LCM.

### **1.5.2 Disadvantage of LCM**

A major disadvantage of LCM with quantitative polymerase chain reactions (QPCR) is that the use of any archival tissues is found to be ineffective (Chan *et al.*, 2004).

Investigations that require the use of LCM in placental tissue (Chan *et al.*, 2004) and when coupled with real-time quantitative RT-PCR (QPCR) is now established as an accurate method for the quantitative analysis of mRNAs encoding specific genes (Chan *et al.*, 2002). Although in-situ hybridisation (ISH) can also provide a more sensitive method of mRNA detection, which could be useful for genes expressed at low levels, LCM with QPCR according to Chan *et al.* (2004) appears to be a superior method of assessing mRNA in tissues.

## **1.6 RESEARCH AIMS AND OBJECTIVES**

As mentioned, scanty information is available on the alterations in keratin expression that accompany the differentiation of the human placental trophoblast from the villous to the extravillous form in the materno-fetal junction at term in both healthy and in the diseased state.

The aims and objectives of this research are:

1. To extend the finding that keratin related immunofluorescence is greater in EVT than in CVT by defining which specific keratins, if any were responsible for the observation that pan-cytokeratins appears to be upregulated in the EVT (Ockleford *et al.*, 2004).
2. To compare CVT and EVT expression of keratins in healthy and pre-eclamptic placental basal plate tissues using indirect immunofluorescence and confocal laser scanning microscopy.
3. To quantify gold particles associated with keratin filaments in CVTs and in EVTs at the Electron Microscopy Level as an independent quantification method.
4. To use laser catapult microdissected samples from chorionic villous trophoblast and the extravillous villous trophoblast cells for quantitative RT-PCR.

By characterising the differences in the expression levels of keratins in the basal plate area of the materno-fetal interaction zone among other methods in healthy and in the disease condition, it is hoped that this research will further add to our understanding of the alterations in keratin expression with differentiation of the trophoblast cell lineage and the possible unique contribution of individual keratin genes to pre-eclampsia when the trophoblast is dysfunctional.

## **1.7**

### **SUMMARY**

Since the human trophoblast (villous and extravillous) is epithelial in origin, it is expected to express a certain pattern of keratin intermediate filament proteins which are generally a characteristic of epithelial tissues. The contribution of keratin intermediate filaments to desmosomes and hemidesmosomes which are junctional complexes also found in trophoblast and in particular the syncytiotrophoblast could be important when the placenta is from pre-eclamptic patients and deportation is increased.

## **2.0 CHAPTER TWO: MATERIALS AND METHODS**

### **2.1 Patient Recruitment**

Pre-eclamptic patients were from the antenatal hypertension clinic at the Leicester Royal Infirmary. They were patients who met defined diagnostic criteria based on the American College of Obstetricians and Gynecologist (ACOG practical bulletin, 2002) clinical classifications and their classification was consistent with the International Society for the Study of Hypertension in Pregnancy (ISSHP). The criteria were:

1. A blood pressure of  $\geq 140/90$  mmHg on two or more separate occasions  $> 4$  hours apart.
2. A 24 hour urine sample collection with total protein excretion of  $\geq 300$  mg/24 hours or a random urine sample with  $\geq 0.5$  g/L of protein, for mild cases.

In addition to these criteria, a patient was classified as severely pre-eclamptic when they presented with one of the following features: raised blood pressure ( $\geq 160$ -180 mmHg systolic or 110 mmHg diastolic) or elevated serum creatinine, seizures (eclampsia), pulmonary oedema, intrauterine growth retardation or oligohydramnios. Only primigravidae were included in this study and pregnancies meeting the criteria after 20 weeks of gestation.

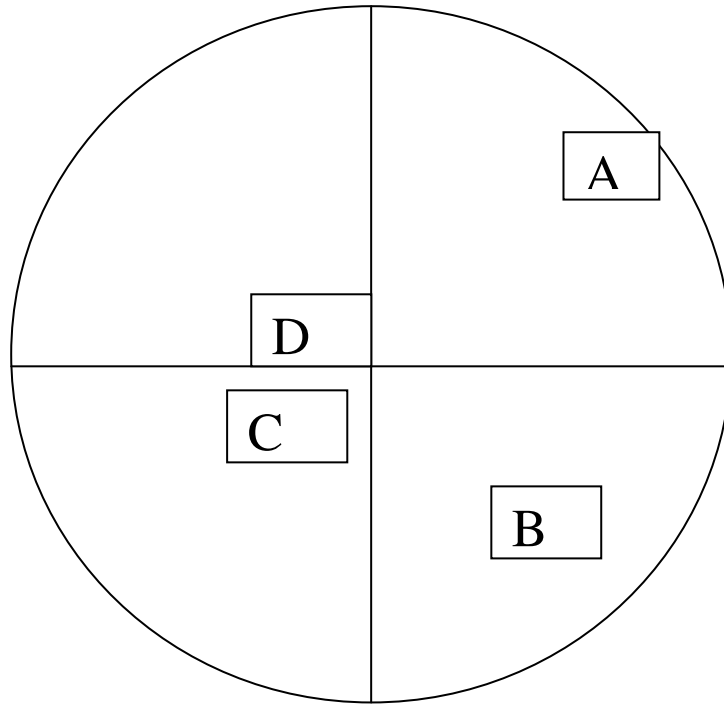
Exclusion criteria were previous cardiovascular disease (including underlying essential hypertension), diabetes, renal disease, hydatidiform mole and multiple pregnancies.

Control healthy patients were recruited from the delivery suite. Placental samples were taken following spontaneous vaginal deliveries or elective/emergency Caesarean section, having obtained informed written consent before or within an hour of delivery.

The research was approved by Leicestershire, Northamptonshire & Rutland Research Ethics Committee Two (Ref: 7144.) and by the University Hospitals of Leicester NHS Trust (Project no. LGH 9161 Version no. 2003CD01). Patient information and consent form is appended.



## 2.2 Tissue sampling:



**Diagram 2.1:** Diagram to illustrate the quadrants and positions on the maternal surface of the placenta from which samples were taken.

Rectangular areas of placental basal plate approximately 1 x 1 x 0.5cm in size were used as outlines to resect blocks of placental tissue from the maternal side of freshly delivered placentae of selected patients. Samples were obtained within one hour of delivery. The samples were labelled A, B, C and D corresponding to the quadrants from which the tissues were taken as shown in diagram 2.1 above for each placenta. These were ordered in a clockwise direction, sample “A” was taken at the edge of the placenta, followed by sample “B” about 2cm from the edge, sample “C” about 4cm from the edge and sample “D” from the central portion of the placenta. This sampling method was a modification of that used by Boyd *et al.* (1980).

Samples were placed vertically in aluminium foil moulds containing cryo-embedding medium OCT Tissue-Tek (Tissue-Tek, Bayer UK, Basingstoke, UK) and were freeze-fixed in a slush of hexane (from Sigma Aldrich) and dry ice in a Dewar flask until the samples solidified. The samples were transferred to storage in coded, sealed freezer bags at  $-80^{\circ}\text{C}$ .

### **2.3 Sectioning:**

The tissue blocks were removed from the Sanyo freezer ( $-80^{\circ}\text{C}$ ) and left in a Bright Cryomicrotome for an hour to adjust to the temperature of the cryostat.

$7\mu\text{m}$  thick sections were cut at  $-13^{\circ}\text{C}$  from each of the four blocks. The sections were thawed onto “subbed” glass slides (coated with 3-aminopropyltriethoxysilane) and left to air-dry at room temperature for 10mins.

### **2.4 Fixation:**

Sections were fixed in 1:1 acetone and methanol for 10minutes at room temperature and then given five times (5 minutes each) rinses in Tris-buffered saline solution and Tween-20 (TBS-T) (Appendix 4). This effectively removed all the fixative. TBS-T provided a suitable environment for antigen-antibody attachment. Tween-20 is a detergent which helps to block non-specific antibody binding and remove lipids.

## **2.5 IMMUNOHISTOCHEMISTRY**

### **2.5.1 Primary (first- Step) Antibody Incubation**

These were mouse monoclonal primary antibodies raised against various isoforms of human keratins 1, 2, 4, 5, 7, 8, 9, 10, 13, 14, 15, 16, 17, 18, 19, 20, 23 and also goat polyclonal keratin 3 and 12.

Each antibody was diluted to an optimum working concentration in an Eppendorf tube by adding the antibody to 20% non-immune fetal calf serum (FCS) in TBS-T (4ml of TBS-T with 1ml FCS) .The dilutions were ascertained by titration (see Table 1 in Appendix 1).

The Eppendorf tube containing the antibody was vortexed for a few seconds to ensure adequate mixing and centrifuged at 13,000 rpm for 1min to sediment any particulate matter. The slides were removed from the Hellendahl jar and wiped with tissue, and a ‘gum’ Immunopen (Calbiochem) was used to draw a ring round the tissue, creating a hydrophobic ring that confines the antibody to be applied to the tissue. The sections were flooded with 100µl of a given primary antibody and incubated overnight at 4°C in a closed container lined with tissue soaked in TBS-T to avoid drying out.

### **2.5.2 Secondary (second-step) fluorescent antibody incubation**

After overnight incubation, the sections were given five times (5 minutes each) washes in TBS-T solution. Optimal dilutions of the second-step antibody were determined by creating a matrix of dilutions. The secondary antibody was added to TBS-T containing 20% FCS in an Eppendorf tube, vortexed and spun as before, then applied to the sections.

The second step antibody was a fluorescein isothiocyanate (FITC) – labelled sheep anti-mouse IgG (Sigma-Aldrich F-3008 Lot 128H9153) or FITC-labelled sheep anti-goat (Sigma-Aldrich product No.F-2016) where applicable. Sections were incubated for two hours at room

temperature in the dark. The slides were finally given five times, 5 minutes washes in TBS-T solution and wiped carefully. Whilst the sections were still wet, a drop of an aqueous mountant (Mowiol 4-88 from Calbiochem) containing the anti-photobleaching agent DABCO (Diazabicyclo [2.2.2] octane) was applied to a (No.0) coverslip and the slide was inverted onto this. The slides were allowed to air dry at room temperature for 30mins before viewing. Negative controls were produced using the procedure previously described except that the primary antibody was replaced by an equal volume of either the isotype of each primary antibody or 20% FCS in TBS-T and with the most concentrated dilution of the second-step antibody. Positive controls such as the amniotic epithelium also followed the procedure described above.

### **2.5.3 Immunofluorescence**

Sections were initially viewed using an epifluorescence microscope equipped with standard filter sets for FITC. FITC has peak excitation and emission wavelengths of 496nm and 518nm respectively.

### **2.5.4 CONFOCAL LASER SCANNING MICROSCOPY (CLSM)**

Sections were examined using a Biorad MRC 600 confocal attachment to a Zeiss Axiovert microscope and images were recorded digitally and processed using COMOS software.

The CLSM is an advanced light microscope which utilizes a reverse-light-path fibre-optic channelled Nomarski DIC signal to a second detector to allow comparison of immunofluorescent and refractive index related images of the same specimen (Ockleford *et al.*, 2004). It was chosen because it gives a better resolution compared with conventional wide-field light microscopy for imaging fixed tissues labelled with fluorescent probes (Paddock, 1999). The (CLSM) has the ability to significantly reduce out-of-focus light and

thereby increase specimen clarity and detail. The term “confocal” means that the objective lens and the condenser lens in the confocal system are both focused on the same small spot on the tissue. They are therefore “confocal” with each other.

### **2.5.5 Measurements and statistical analysis**

Digital images of anti-cytokeratin immunofluorescence of healthy and pre-eclamptic placentae comprising both chorionic villous trophoblast (CVT) and extravillous trophoblast (EVT) of the basal plate tissue were measured using the same rectangular boxed area of  $340.8\mu\text{m} \times 226.6\mu\text{m}$  ( $77225.28\mu\text{m}^2$ ). Percentage of pixels with intensity in the high intensity band (210-255) for both (CVT) and (EVT) were recorded. The criteria for taking measurements were, to randomly select regions of EVTs or CVTs on the same basal plate tissue image and to ensure that each area selected to be measured did not overlap an area already chosen. Paired measurements of areas of EVT and CVT in each image from the same section were made, so as to minimise the effects on the comparison of inter-preparation variation. It was ensured that the area being measured contained only either EVT or CVT. Therefore measurements were not made in overlap zones. Images where the basal plate widths were smaller than the rectangular box were not measured. Results were recorded in Excel 2007 spread sheets and statistical analyses were carried out using STATA™ version 9.2 StataCorp, Texas. (See appendices 5a-5e).

## **2.6 ELECTRON MICROSCOPY-IMMUNOGOLD LABELLING**

The use of antibodies conjugated with colloidal gold particles and electron microscopy permits the high-resolution detection, localization and quantification of defined antigens in cellular compartments (Mayhew, 2007). This is because gold particles are electron dense, punctate, and available in different sizes and when coupled with the ability of the transmission electron microscope (TEM) to resolve both the particles and compartments of interest, the method becomes a useful tool for subcellular studies.

According to Mayhew *et al.* (2004) and Mayhew (2009) quantitative immunoelectron microscopy involves determining the distributions of gold label in different intracellular compartments in the same sample of cells or between experimental groups. The method is reported to be applicable to investigations involving comparing compartmental labelling distribution of for instance cytoskeletal elements (filaments) between groups.

### **2.6.1 Methodology**

Basal plate tissue blocks of approximately (10 x 10 x 2 mm) thick were randomly sampled from freshly delivered placentae. 2 each were taken from pre-eclamptic and healthy donors and fixed in 4% paraformaldehyde + 0.1% glutaraldehyde in phosphate buffered saline (PBS) pH 7.4 for 1hour (for immuno-EM). The use of 4% paraformaldehyde and only 0.1% glutaraldehyde rather than the conventional 4% glutaraldehyde followed by 1% Osmium tetroxide was to optimise morphology and preserve antigenicity.

### **2.6.2 Tissue processing**

After fixation the specimens were rinsed in PBS then dehydrated through a series of 70%, 90% and 100% ethanol solution for 1hour (2 changes in each concentration). The specimens were trimmed to size (4mm x 3mm x 1mm block edge) and placed in a glass vial containing medium grade LR White (London Resin Company Ltd, Reading, Berkshire, UK) at room

temperature. These were changed 3-4 times over 2 to 3 days. The specimens were then placed in labelled gelatin capsules containing LR White making sure to exclude air and incubated at 50-55<sup>0</sup>C in an oven for 2-3days.

### **2.6.3 Sectioning:**

The specimens in resin blocks were shaped by jig-sawing and filing from each of healthy and pre-eclamptic placentae. These were then attached to a cylindrical brass stub, using a cyanoacrylate adhesive. Blocks were “faced up” using a glass knife. Semi-thin sections (0.5-1.0 $\mu$ m) thick were cut on a Reichert-Jung Ultracut microtome using a fresh glass knife, and floated onto water contained in an attached trough. The sections were transferred to a drop of distilled water on a glass slide using a wire loop and dried down on a hot-plate. These were stained with 1% toluidine blue in 2% borax on the hot-plate, rinsed with distilled water and viewed microscopically. An appropriate area was selected so as to include any features which were of interest at the ultrastructural level (Basal plate, EVT, CVT). The large block face was trimmed further to a size suitable for ultramicrotomy (0.5mm<sup>2</sup>). Sections were cut at 80-100nm thickness (pale to dark gold interference colour) using a diamond knife and collected onto 300 hexagonal mesh nickel grids pre-coated with Sellotape adhesive dissolved in chloroform (10cm<sup>2</sup> of Sellotape per 5ml of chloroform).

### **2.6.4 Immunogold labelling with primary antibody**

Grids were floated with section side down on 10 $\mu$ l droplets of blocking solution in small depressions made on a piece of dental wax in a covered Petri-dish that contained moistened filter paper to prevent drying out.

After pre-incubation with the blocking solution (PBS with 5% non-immune Goat serum, Bovine Serum Albumin and Tween-20 (PBSGAT) (see Appendix 4) for 1-2hrs at room temperature (approximately 20<sup>0</sup>C), the grids were transferred onto 10 $\mu$ l droplets of the

primary antibody in the same solution. The experimental primary antibodies were monoclonal mouse anti-keratin 18 and anti-keratin 7 (clone number CY-90: product number C8541; Sigma for K18 and clone number LDS-68: product number C6417 for K7). For K18, the dilution was 1:100 in blocking solution and the grids were incubated at 4<sup>0</sup>C overnight.

#### **2.6.5 Pre-treatment step:**

For keratin 7 antibody, grids were first placed in a cassette and immersed in epitope unmasking solution of 10mM citrate buffer, pH 6.0 for 20mins at 95<sup>0</sup>C. The grids with the cassette were removed gently and allowed to cool down in cold citrate buffer for 20mins. The grids were then removed singly with a pair of forceps, dipped 10 times in two changes of distilled water before floating on blocking solution as above and then transferred onto 10 $\mu$ l droplets of the primary antibody with a working dilution of 1:20 in blocking solution and incubated at 4<sup>0</sup>C overnight.

Control grids were not incubated with the primary antibody, this stage was replaced by immersion in the blocking solution alone. After this incubation, the sections were washed by flotation as before (5 minutes x 6 changes) in PBS-T, then transferred to blocking solution for 5mins and then exposed to the secondary antibody (a 10nm gold conjugated goat anti mouse IgG from Sigma (product number G7777 lot 084k1581) diluted at 1:50 in blocking solution for 1hour at RT. The sections were then washed as above in PBS-T, then 5mins x 2 times in distilled water and air-dried.

#### **2.6.6 Staining:**

The sections were stained with 5% uranyl acetate in 9% aqueous isobutanol for 15-20 minutes and then washed by dipping each section 10 times each in 3 pots of distilled water, blotted dry on lint- free tissue and stored in a labelled grid case.



### **2.6.7 ELECTRON MICROSCOPY: IMAGING**

Digital images were obtained using a JEOL JEM-1220 electron microscope at 10- 40,000 X magnification. These JPEG files were printed either on photo-quality glossy paper, for print production or on standard matt white paper for counting purposes.

### **2.6.8 Counting of gold particles:**

Areas which included obvious intermediate filament bundles were circumscribed and the numbers of gold particles within these areas were counted. Areas on the electron micrographs containing the nucleus were also circumscribed and any gold particles counted were recorded as background. Counts were made for images from CVT and EVT for healthy placentae and pre-eclamptic placentae. A  $1\mu\text{m}^2$  area (from the scale bar on the print) was cut out of the paper and weighed using a 1mg balance. The circumscribed areas were similarly cut out and weighed; the counts associated with these were recorded and this allowed the number of gold particles per  $\mu\text{m}^2$  to be calculated for each area and cell type (Byrne *et al.*, 2007).

## **2.7 WESTERN BLOTTING**

### **2.7.1 FINE MANUAL MICRODISSECTION:**

3 placental basal plate tissue samples, from healthy and pre-eclamptic mothers, were sectioned on a cryomicrotome at 15µm and thawed onto plain glass slides (n=30sections) for each group. The slides were allowed to air dry at room temperature for 30mins.

The slides were manually microdissected on a dissecting microscope, using a sharp hypodermic needle and a scalpel blade. The needle was used to demarcate the boundary of the basal plate tissue from the chorionic villous trophoblast tissue and the surrounding cryofixative (OCT).

The scalpel blade was used to scratch carefully the basal plate tissue away from the chorionic villous tissue and the two tissue groups collected into labelled, pre-weighed Eppendorf tubes. The Eppendorfs were reweighed to ascertain the actual weights of CVT samples for the healthy and pre-eclamptic groups. The basal plate areas for the two groups were stored in a freezer at -80<sup>0</sup>C.

Total weight of Healthy CVT (CVTh) sample = 8.00mg

Total weight of Pre-eclamptic CVT (CVTp) sample = 5.55mg

#### **PROTEIN CONTENT ESTIMATION**

2.72mg of Healthy CVT and 2.68mg of Pre-eclamptic CVT samples were weighed out using a precision weighing balance (Sartorius). Each sample was digested in 500µl Laemmli sample buffer (Appendix 4).

## STANDARD CURVE SOLUTIONS

40mg of bovine serum albumin (BSA) was weighed into 20ml distilled water (2mg/ $\mu$ l) which was further diluted to 1.0mg/ $\mu$ l (250  $\mu$ l of BSA + 250  $\mu$ l of sample buffer), 0.5mg/ $\mu$ l (1.25  $\mu$ l + 375  $\mu$ l sample buffer), 0.2mg/ $\mu$ l (50  $\mu$ l + 450  $\mu$ l sample buffer) and a blank which contained sample buffer only.

Protein estimation utilised a Bio-Rad Dc Protein Assay kit. 20 $\mu$ l of reagent S was added to 1.0ml of reagent A in an Eppendorf tube. Small volumes (25  $\mu$ l) of CVTh, CVTp and standard curve solutions were pipetted into different Eppendorf tubes. Exactly 1.0ml of reagent B was added to each tube. From the standard curve (Appendix 6), the protein concentrations of CVTh and CVTp were estimated at 2.250mg/ml and 1.508mg/ml respectively.

The protein concentrations of CVTh and CVTp obtained were then used to ensure that equal amounts of proteins were loaded into western blot gels.

40  $\mu$ l of each sample were loaded in gel lanes. This contain 22.2  $\mu$ l of Healthy sample + 17.8  $\mu$ l of Laemmli sample buffer and 33.2  $\mu$ l of pre-eclamptic sample + 6.8  $\mu$ l Laemmli sample buffer (see Figure 28 and 29).

The remaining samples of the CVTh (5.28mg) and CVTp (2.87mg) were dissolved in 0.5 ml Laemmli sample buffer solution (containing 5.7% w/v SDS, 29% v/v glycerol, 0.003% bromophenol blue and 0.18 M Tris HCl) pH approx. 6.8. 100mM dithiothreitol (DTT), boiled for 3mins, cooled and centrifuged for 3mins at 13,000 rpm. The supernatants of the samples were aliquoted into small vials and stored in the freezer (-80°C).

To determine the best volume of samples to load when running the gel, a trial of 10 $\mu$ l of sample + 30 $\mu$ l of sample buffer (**SB**), 20 $\mu$ l of sample + 20  $\mu$ l of **SB**, 30  $\mu$ l of sample +10  $\mu$ l

**SB** and 40 µl of sample only, were used to load the wells for healthy CVT and Pre-eclamptic CVT samples and similarly derived basal plate samples and amnion.

## **2.7.2 Sodium Dodecyl Sulphate Polyacrylamide Gel Electrophoresis (SDS PAGE)**

### **2.7.2.1 Preparation of glass plates:**

A pair of glass plates (18.5cm wide x 13.5cm tall), made of 4mm thick float glass consisting of a plain plate and a notched plate. The notched plate was 14.5cm long and 2.0cm deep leaving two “ears” (2.0 x 2.0 cm) at each of the top corners. The pair of glass plates were washed with a detergent rinsed in distilled water and dried using a lint-free paper towel. This was to remove any residual contamination.

Two side spacers 1.9 x 13.2cm, made of 1.5mm rigid grey polyvinylchloride (PVC) and a bottom spacer, 18.0 x 1.0cm were washed and lightly coated with petroleum grease. They were placed at the sides and base of the unnotched glass plate. The notched glass plate was placed on the set-up so that the two plates were brought into register. The assembly was then clamped together using 5cm “Bulldog” spring-clips (2 at each side and 3 at along the bottom). It was ensured that the side spacers aligned precisely with the bottom spacer to prevent leakage when filled.

### **2.7.2.2 Casting of polyacrylamide gradient gel**

The SDS PAGE method was adapted from Laemmli (1970) under reducing conditions (by adding DTT). The recipes for individual components for the SDS PAGE can be found in the Appendix 4.

The solutions were mixed gently to prevent too much oxygen being trapped in them which can prevent polymerisation. The ammonium persulphate (APS) was added only when the solution was ready for use because it catalyses the polymerisation reaction and aids the formation of the gel.

The light and the dense acrylamide solutions were poured into the L and R chambers of the gel gradient mixing equipment ensuring that the connection between the chambers was closed. The twin chambers were lowered to sit on a stirrer and the connection opened. The peristaltic pump force removes the two solutions from the chambers into the gap between the plates to form a gradient gel (5-20%). After this, 1ml (0.5ml at each end) of distilled water was poured on the gel gently and left to set for an hour and the water was tipped off when the gel was set. The APS was added to the stacking gel and poured into the top of the plates and a comb inserted between the plates to create the loading wells for the samples. The set up was left for an hour to set and the comb was removed. Gradient gels were used because they give optimum resolution of proteins in a mixture of high and low molecular weights.

#### **2.7.2.3 Running the gel**

All bulldog clips were removed from the polymerised gel/plates. The gel and the plates were attached to the gel tank using 2 top clips and the handles removed whilst all other clips were removed. The long bottom spacer was removed and the tank filled with running buffer (see Appendix 4 for running buffer constituents). A syringe filled with running buffer with a bent-ended needle, was used to remove bubbles from the bottom of the gel. The wells in the stacking gel were washed out with distilled water, followed by running buffer. 40µl of sample solutions and 5 µl of the standard molecular weight marker (Bio-Rad, prestained SDS-PAGE standard-low range cat. No. 161-0305 control 98578) + 35 µl SB were loaded into the wells. The gel was run for about 2.5 hours at 50mA constant current (the voltage was set to 300V) and was stopped when the blue dye front reached the bottom of the gel.

#### **2.7.2.4 Staining the gel with Coomassie brilliant blue**

The stain was made of ( 10% v/v acetic acid, 45% v/v of industrial methylated spirit (IMS), 0.08% w/v Coomassie brilliant blue R-250 ) which was placed in a shallow dish with a lid. The gel to be stained (not the gel to be blotted) was placed in the stain and the lid replaced and then placed on an orbital shaker at low speed overnight. Destaining solution (10% acetic acid in deionised water with 5% IMS) was added to the gel and replaced at hourly intervals until the matrix was clear. The destained gel was scanned and saved.

.

#### **2.7.2.5 Semi-dry transfer of proteins from gel to membrane**

The size of the gel to be blotted was measured and placed in a container with transfer buffer [3g of Tris-Base, 14.25g of Glycine and 10% methanol made up to 1 litre] and gently agitated for 20mins to remove some of the SDS from the gel matrix.

8 pieces of Whatman no.1 filter paper were cut to the same size as the gel and placed in transfer buffer in a separate dish. A single piece of polyvinylidene fluoride (PVDF) membrane was cut to the same size as the gel. The membrane was immersed in a small volume of 100% methanol in a clean dish, which allowed the hydrophobic membrane to become wetted. The membrane was then rinsed twice in distilled water and then twice in transfer buffer. Two (2) sheets of the soaked filter paper were placed on the graphite anode plate of the transfer apparatus. Air bubbles trapped between the sheets were removed by gently rolling a glass pipette across the surface. The PVDF membrane was placed on the sheets and a few ml of buffer was poured over it, followed by the gel and then the 6 remaining filter papers sheets.

The cathode plate was placed on top of this set up and after connection; a small weight was placed on the top to ensure good electrical contact was maintained.

Transfer was accomplished using a constant current of  $1\text{mA}/\text{cm}^2$  (the voltage was set to 20V). When the run was complete, the gel was removed and placed in a dish. The membrane was rinsed in 3 washes of TBS-T for 5 minutes each.

The blot was wrapped in Saran wrap and the positions of the standard molecular weight were permanently marked on the blot by pricking through either side of each band.

#### **2.7.2.6 Detection of antigens immobilised on the membrane**

The lanes in the membrane were cut into strips for the individual antibodies.

The strips were first blocked in blocking solution (“milk”) for 20 mins (see Appendix 4), and a series of dilutions of primary antibodies, mouse monoclonals raised against keratins 4, 5, 7, 13, 15, 16, 18, 19, obtained from Sigma were prepared in milk ascertained by titration as follows:

K4, 30 $\mu\text{l}$  in 20ml of milk; K5, 10 $\mu\text{l}$  in 20ml of milk; K7 10 $\mu\text{l}$  in 10ml of milk; K13, 10 $\mu\text{l}$  in 20ml of milk; K15, 10 $\mu\text{l}$  in 20ml of milk and K16, 10 $\mu\text{l}$  in 20ml of milk K18, 0.5 $\mu\text{l}$  in 20ml of milk; K19, 25 $\mu\text{l}$  in 20ml of milk. The individual strips were then incubated with one of the primary antibody solutions at  $4^{\circ}\text{C}$  overnight on a rocking platform. After overnight incubation, the blots were washed 5 times for five minutes in TBS-T and the secondary antibody, Goat anti-mouse peroxidase conjugate diluted at 1 $\mu\text{l}$  in 20mls of milk ( 1: 20,000 dilution) was used to incubate the strips at room temperature for 2 hours, followed by 5 times, five minute washes in TBS-T.

### **2.7.2.7 Chemiluminescent detection of keratins**

A luminol based chemiluminescent detection system (SuperSignal® West Pico PIERCE, Rockford, IL, USA) was used to localise the antibody on the blots. Horseradish peroxidase (coupled to the secondary antibody) catalyses the hydrolysis of hydrogen peroxide; the free oxygen liberated causes the luminol to emit light in the blue part of the visible spectrum and this can be detected on photographic film.

Equal volumes (about 3mls) of the two components of the kit were mixed together. The strips were carefully aligned, (protein side uppermost) on a piece of Saran wrap and the substrate was flooded over these for 1minute. After this the excess fluid was tipped off and the surrounding area was quickly dried. The top surface was then covered with further Saran wrap and the whole placed in an x-ray cassette. The dark room light was then extinguished and the safe light switched on. A piece of Fuji x-ray film was placed on top of the blot and exposed initially for 1 minute and turned round end-to-end and a second exposure of 2 minutes made. A fresh piece of film was then placed in the cassette. The exposed film was then developed either automatically or by hand. If the first two exposures were found to be inadequate, the second piece of film was left in the cassette for up to 30 minutes.

The developed film was placed back in the cassette and the positions of the various strips were marked on the film with a fine marker pen. Similarly, the positions of the marker track were also drawn on the film. Digital images of the films were made.



## **2.8 METHODOLOGY OF LASER CATAPULTING MICRODISSECTION (LCM)**

The cryostat cabinet and knife were cleaned with 70% alcohol and all glassware and pipette tips were RNase free. Solutions were prepared with water that had been treated with diethylpyrocarbonate (DEPC) to inhibit RNase activity.

### **2.8.1 Tissue preparation and staining**

Fresh blocks of placental basal plate were taken from the -80°C freezer, 2 each of healthy and pre-eclamptic blocks.

The Bright cryo-microtome was set to a cabinet temperature of -13°C. Tissue blocks were mounted on the chuck in the cryostat using OCT. Tissues were trimmed, with the cutting thickness of the microtome knife initially set at 20µm, until the tissue with the basal plate was visible. The thickness was readjusted to 10µm and the sections cut and thawed on a 0.17mm PEN (polyethylene naphthalate) 1.35µm membrane slides from P.A.L.M Microlaser Technologies, Bernried, Germany (Art. No.440-150). The membrane slides were pre-exposed to UV light for 10minutes. The sections were labelled CVTh, EVTh, CVTp, and EVTp for tissue blocks from healthy (h) and pre-eclamptic (p) placentae. A 'gum' Immunopen (Calbiochem) was used to draw a ring round the tissue on the membrane slide, creating a hydrophobic ring that confines any solution to be applied to the tissue. The tissue slides were then fixed in 1:1 (v/v) acetone-methanol at room temperature by pipetting 100µl of the fixative onto the tissue slide for 5 minutes. After fixation, the fixative was pipetted away and the slides were washed 5 times, each lasting 1 minute in PBS using the same pipetting procedure.

The antibody used to detect the trophoblastic cells was a FITC-conjugated cytokeratin 18 (Sigma F4772) diluted in 1: 50 of 20% fetal calf serum prepared with PBS and 20µl RNase inhibitor (Ambion® cat # AM 2682). 100 µl of the antibody solution was pipetted unto the

slides and incubated for 5 minutes at room temperature. After incubation, the slides were washed 5 times, each lasting 1 minutes in (PBS) using the same pipetting procedure.

100 µl of 70% ethanol prepared with (DEPC) water were placed on the sections for 1 minute, followed by 100% alcohol for 1 minute using the pipette method. The sections were air dried for 10 minutes and were ready to view on the P.A.L.M microscope using the FITC channel to locate the positions of the CVT and EVT cells.

### **2.8.2 Laser cutting of cells**

Zeiss PALM microlaser Technologies equipment was set to the FITC channel and a Laser cut UV energy value of 60, UV focus at 78 and a selected speed value between 30 and 58. The objective lens selected was 20x magnification and the corresponding lens on the computer also 20x magnification.

The desired area was circumscribed using the mouse and the machine set on AUTO LPC to automatically cut the cells of interest and catapult them into a fitted cap of an Eppendorf which has a thin layer of thermoplastic polymer film containing an infrared-absorbing dye (ethylene vinyl acetate polymer) on the robotic arm. Extravillous trophoblast cells which were taken from the basal plate and CVT taken from the periphery of chorionic villi (cytotrophoblast and syncytiotrophoblast) were identified by their immunostain with FITC-labelled anti-K18 antibody, a modification of Arechavaleta-velasco *et al.* (2006) protocol. The caps were carefully closed and stored on wet ice or at -80°C.

### **2.8.3 RNA ISOLATION AND REAL-TIME RT-PCR**

#### **2.8.3.1 Total RNA extraction using TRI REAGENT™ solution**

250µL of Tri reagent™ from Sigma-Aldrich (product No. T9424) were added to approximately 500 laser captured cells each of CVTh, EVTh, CVTp, EVTp, in labelled Eppendorf tubes, using a Gilson pipette.

50µL of chloroform was added to each tube and the cap tightly closed. The contents were mixed by turning upside down, and vortexed at full speed for 15sec till a milky colour appeared. The tubes were allowed to stand at room temperature for 10minutes.

The tubes were then centrifuged at 12000rcf for 15minutes at 4<sup>0</sup>C.

The upper, clear, aqueous phase was carefully pipetted into fresh labelled Eppendorf tubes.

125µL of isopropanol was added to the solutions and vortexed for 15seconds to precipitate the RNA. The tubes were allowed to stand at room temperature for 10minutes and then centrifuged at 12000rcf for 10minutes at 4<sup>0</sup>C.

In one motion, the supernatants were discarded and excess fluids were removed using a 200µL Gilson pipette. 250 µL of 75% ethanol was added to each tube to remove any salt. The tubes were inverted a few times and centrifuged at 12000rcf at 4<sup>0</sup>C for 10minutes.

The supernatants were again discarded by tilting into a collector and pipetting the remaining using a 200µL Gilson pipette. The tubes were opened and incubated in a cell culture flow cabinet for approximately one hour to dry.

20µL of RNase free water (DEPC water) was added to the tubes and then incubated for 10minutes at room temp to allow the RNA to dissolve.

The above method was used to extract RNA from a sample (3cm x 3cm x 2cm) block of fresh placental tissue including the basal plate, washed in DEPC water and immersed in liquid

nitrogen. The basal plate part of the tissue and the chorionic villous part were manually dissected into clean tubes weighed approximately 20mg each and labelled (BPmd) , (CVTmd) respectively and in addition a sample from the amnion (Am) .

### **2.8.3.2 Reverse transcription**

Here single-stranded DNA copies are made from the mRNA in the RNA extracted samples. The DNA strands are complementary copies of the mRNA that has been copied and hence generally called (cDNA).

Exactly 9 µl of each RNA sample (CVTh, EVTh, CVTp, EVTp, Am, BPmd, CVTmd) were pipetted into 0.6ml Eppendorf tubes separately including a negative control (sterile deionised water).

The RNA samples and the control were denatured by putting them into PCR apparatus with a set cycle of heating at 70<sup>0</sup>C for 5 minutes and followed by cooling to 42<sup>0</sup>C and then the program was paused.

#### **REVERSE TRANSCRIPTION (RT) MASTERMIX**

The RT mastermix contains the following components for a reaction:

Hexanucleotides (random 6 bp oligonucleotide primers 0.2µg/µl	1.0µl
AMV Buffer (5x, 5 times final concentration)	4.0µl
10mM dNTP mix	2.0µl
dH <sub>2</sub> O (sterile, deionised, RNA-free)	2.7µl
AMV (Avian Myeloblastosis virus) RT enzyme (10 units/ µl)	0.8µl
RNase Inhibitor (40units/ µl)	0.5µl

Adequate mastermix was prepared for the reactions and stored on ice until needed.

Aliquots (11 µl) of the RT mastermix were added to the denatured RNA and control samples using a fresh tip each time and were pipetted up and down carefully to mix properly and then centrifuged to ensure all the liquid was collected at the bottom of the tube.

The PCR equipment heating programme was then resumed to incubate the samples at 42<sup>0</sup>C for 1hour to allow the reverse transcriptase enzyme to copy the RNA into cDNA and then

denature the double stranded material at 90<sup>0</sup>C for 4minutes. The samples were centrifuged at the end of the RT incubation.

### 2.8.3.3 Quantification of housekeeping gene beta-2 microglobulin (B2M)

This gives an accurate measurement of RNA present in each sample so that differences in the efficiency of RNA extraction could be taken into account when compared with the target gene of interest.

Beta 2 microglobulin primers sequence used are as follows:

Fwd 5' - GGCTATCCAGCGTACTCCAAAG-3'

Rev5'-CAACTTCAATGTCGGATGGATG-3' at 5μM final concentration of each primer.

5 μl each of the (cDNA) samples CVTh, EVTh, CVTp, EVTp, Am, BPmd, and CVTmd were pipetted into an Eppendorf to prepare a serial dilution for the standard curve labelled 1.

5μl of label 1 were pipetted into 20μl of dH<sub>2</sub>O and labelled 0.2. 5μl of label 0.2 were pipetted into 20μl of dH<sub>2</sub>O and labelled 0.04 which was further diluted to 0.008 and 5μl of this discarded.

#### PCR MASTERMIX for a reaction contains:

2X SensiMixPlusSYBER (enzyme, dNTPs etc)		50μl
3' Primer (5μM)	B2M	10μl
5' Primer (5 μM)	B2M	10μl
Water (dH <sub>2</sub> O)		15μl

The SensiMixPlus SYBER contains reaction buffer, heat-activated Taq DNA polymerase, dNTPs, 6mM MgCl<sub>2</sub> which is a co-factor for DNA polymerase, internal reference dye, stabilizers and SYBER® GREEN 1 from Quantace, UK Cat. No.QT605-02.

This is a kit that has been developed especially for qPCR assays. It is optimised for use with SYBER® GREEN 1 ([www.quantace.com](http://www.quantace.com)).

#### **2.8.3.4 Amplification reaction**

Mastermix were prepared for the number of reactions required and 17µl of the master mix was aliquoted into 11 PCR tubes.

3µl of each sample (CVTh, EVTh, CVTp, EVTp, Am, BPmd, CVTmd) and a negative control (PCR water) including the serial diluted samples were added to the mastermix in the tubes. The tubes were loaded into a CORBETT Rotor-Gene 600 series machine which runs on Software version Rotor-Gene 1.7.87 and the reaction set for 45 cycles.

Step 1 @ 95°C, hold 10sec, Step 2 @ 60°C, hold 5sec, Step 3 @ 72°C, hold 25sec.

Melt temperature (72-95°C).

The increasing amount of RNA was quantified automatically by the CORBETT equipment after each cycle using the measured fluorescence of the dye SYBER Green which intercalates into the DNA.

The Corbett at the end of each PCR dissociates the two DNA strands “melts” by slowly heating the samples and measuring the gradual reduction of fluorescence in each sample. The fluorescence/temperature curves obtained give an indication of the size of A-T/G-C base composition of the amplified PCR product DNAs.

### **2.9 KERATIN 7 PCR**

#### **2.9.1 Keratin 7 primer design**

Specific primers were designed with the Primer3 software, Roze and Skaletsky (2000) for K7 after a nucleotide sequence (BLAST: Basic local assignment tool) and primers were obtained from MWG-Biotech AG, Germany.

Keratin 7 inner and outer primer sequences are as follows:

K7 (outer) Left 5' ATTCCACTGGTGGCAGTAGC 3'

Right 3' GGGTGGAATCTTCTGTGA 5'

K7 (inner) Left 5' AGTGGCGGTGGCATTGGGCT 3'

Right 3' TTGTGGGTGGTGGCTGGAGG 5'

The outer primers were 222 base pairs and the inner primers were 182 base pairs.

### 2.9.2 Nested PCR

A nested PCR uses two sets of amplification primers. The target DNA sequence of one set of primers (termed "inner" primers) is located within the target sequence of the second set of primers (termed "outer" primers). In practice, a standard PCR reaction is first run with the "outer primers". A second PCR reaction is then run with the "inner primers" using the product of the first reaction as the amplification target. This procedure increases the sensitivity of the assay by reamplifying the product of the first reaction in a second reaction. The specificity of the assay is increased because the inner primers amplify only if the first PCR reaction yielded a specific product (Knox and Carrigan, 2009). According to Arechavaleta-velasco *et al.* (2006), a nested PCR ensures that adequate amount of DNA/mRNA were extracted from the sample. This method was chosen over the conventional PCR due to the smaller number of laser dissected cells. The outer primers were used to PCR the samples and 3µl of the PCR products were used as the template for a second PCR using the inner primer.

#### PCR MASTERMIX with outer primers:

2X SensiMixPlusSYBER (enzyme, dNTPs etc)	50µl
3' Primer (5µM)    K7 (outer)	10µl
5' Primer (5µM)    K7 (outer)	10µl
Water (dH <sub>2</sub> O)	15µl

## AMPLIFICATION REACTION

Mastermix was prepared for the number of reactions required and 17µl of the master mix was aliquoted into PCR tubes with the outer primers of keratin 7.

3µl of each sample and control including the serial diluted samples were added to the mastermix in the tubes. The tubes were loaded into the Rotor-Gene 600 running on Software version Rotor-Gene 1.7.87 and the reaction set for 45 cycles.

Step 1 @ 95°C, hold 10sec, Step 2 @ 60°C, hold 5sec, Step 3 @ 72°C, hold 25sec.

Melt temperature (72-95°C).

This was followed by another PCR with the inner primers as above.

The samples were labelled as follows:

(CVTho) = chorionic villous trophoblast healthy, outer K7 primer PCR product

(CVThi) = chorionic villous trophoblast healthy, inner K7 primer PCR product containing 3µl of outer primer PCR product

(CVTpi) = chorionic villous trophoblast pre-eclamptic, inner K7 primer PCR product containing 3µl of outer primer PCR product

CVTpo) = chorionic villous trophoblast pre-eclamptic, outer K7 primer PCR product

EVTho = extravillous trophoblast healthy, outer K7 primer PCR product

EVThi = extravillous trophoblast healthy, outer primer K7 PCR product containing 3µl of outer primer PCR product

EVTpi = extravillous trophoblast pre-eclamptic, inner K7 primer PCR product containing 3µl of outer primer PCR product

EVTpo = extravillous trophoblast pre-eclamptic, outer K7 primer PCR product

PCR water = (-ve),

Amo = amnion outer K7 primer PCR product

Ami = amnion inner K7 primer PCR product

(CVTmdo) = chorionic villous trophoblast healthy manually microdissected outer K7 primer PCR product



CVTmdi) = chorionic villous trophoblast healthy manually microdissected inner K7 primer PCR product

(BPmdi) = basal plate tissue manually microdissected inner K7 primer PCR product containing 3µl of outer primer PCR product

(BPo) = basal plate tissue manually microdissected outer K7 primer PCR product

### **2.9.3 2% Agarose Gel electrophoresis of keratin 7 DNA using PCR product of outer and inner primers.**

A gel casting tray composed of UV- transparent plastic was washed with detergent and cleaned with distilled water. The open ends of the tray in which the gel will be cased were closed with adhesive tapes.

The electrophoresis buffer was made from 1X Tris-acetate-EDTA (TAE) which establishes the pH and also provides the ions to support the conductivity.

3g of Agarose powder was weighed and added to 150ml of TAE solution in a 200ml bottle.

The bottle was then microwaved for 1.5 minutes at full power. The solution was swelled intermittently to make sure all the Agarose were dissolved.

The solution was allowed to cool down to about 60<sup>0</sup>C and with a pair of gloves, 7.5µl of Ethidium bromide out of a stock solution of 10mg/ml was placed in the solution, making a final concentration of 0.5microgram/ml, the fluorescent dye, intercalates between bases of DNA. A sample comb was inserted into the gel to create the sample wells and the gel was allowed to set for 30minutes.

After the gel was set or solidified, the comb was gradually and carefully removed and the tapes at the end of the gel casting tray removed. The gel casting tray was placed in the electrophoresis chamber filled with TAE solution until it just covered the wells.

10µl PCR products from laser captured samples from healthy(h) and pre-eclampsia(p): (CVTho), (CVThi), (CVTpi), CVTpo), EVTho, EVThi, EVTpi, EVTpo, PCR water (-ve), and Amo, Ami,(CVTmdo), CVTmdi), (BPmdi) , (BPo) samples in addition to 2µl of loading dye which contains bromophenol blue and xylene cyanol were mixed with the samples and carefully introduced into the wells with a standard marker (lane 1).

The power source was connected and the voltage set to 100V (5V per cm to the gel which is the distance between the two electrodes). The gel was allowed to run until the marker front reached about 2/3 down the gel. After the run, the gel was removed carefully and visualised on a UV- transilluminator and then photographed. The inner primers corresponded to 182bp and the outer primers corresponded to 222bp for keratin 7 gene expressed in the chorionic villous and the basal plate samples.

### 3.0 CHAPTER THREE: RESULTS

#### 3.1 OVERVIEW OF KERATIN EXPRESSION

The table shows a summary of the findings of the distribution of 20 distinct molecular forms of keratins in the human term extra-embryonic membrane ectoderm including the amniotic epithelium, chorionic villous trophoblast and extravillous trophoblast.

(K)	CVT	EVT	AMNIOTIC EPITHELIUM
1	-	-	-
2	-	-	-
3	-	-	-
4	-	-	+
5	+	++	+
6	-	-	+
7	+	++	-
8	+	++	+
9	-	-	-
10	-	-	+
12	-	-	-
13	-	-	+
14	-	-	+
15	-	-	-
16	-	-	-
17	-	-	+
18	+	++	+
19	+	++	+
20	-	-	-
23	-	-	-

**TABLE 2**

Table legend K = keratin, CVT = chorionic villous trophoblast and EVT = extravillous trophoblast. The expression is defined as follows:

(-) = not expressed above background

(+) = expressed

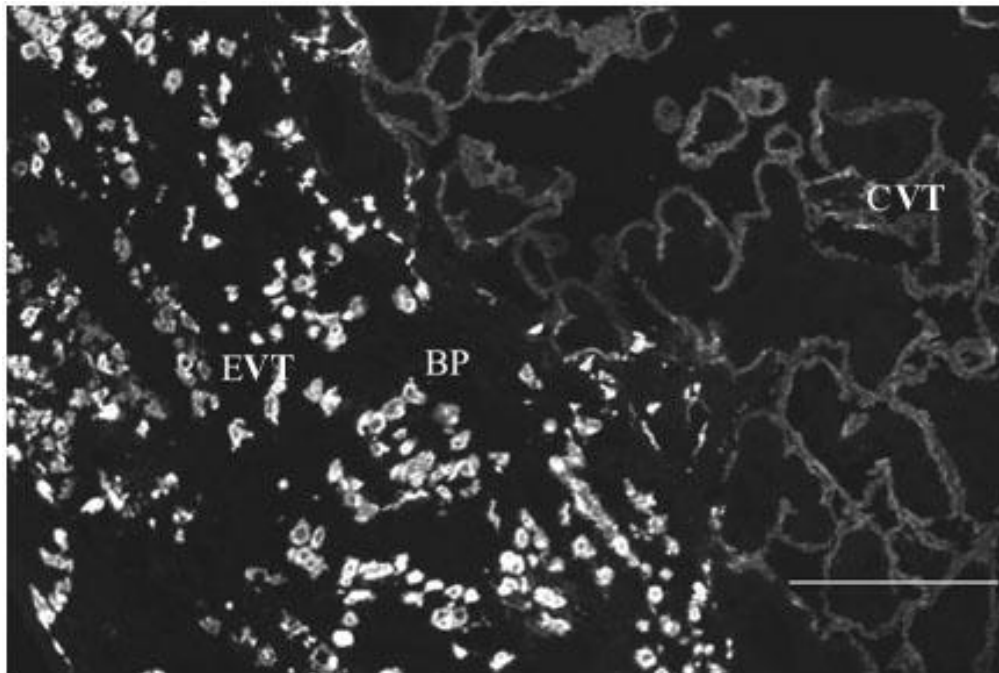
(++) = upregulated

### 3.2 Immunofluorescence results

A total of 10 healthy and 10 pre-eclamptic term placentae were used for keratin 7, 8, 18 and 19 indirect immunofluorescence Confocal Laser Scanning Microscopy (CLSM) observations as one group (Appendix 2a & 2b) and a further 10 each of healthy and pre-eclamptic placentae were obtained for the Keratin 5 (CLSM) study (Appendix 2c & 2d).

CLSM images reveal specific anti-keratin indirect immunofluorescence labelling of the cytoplasm of trophoblast cell types (CVT and EVT).

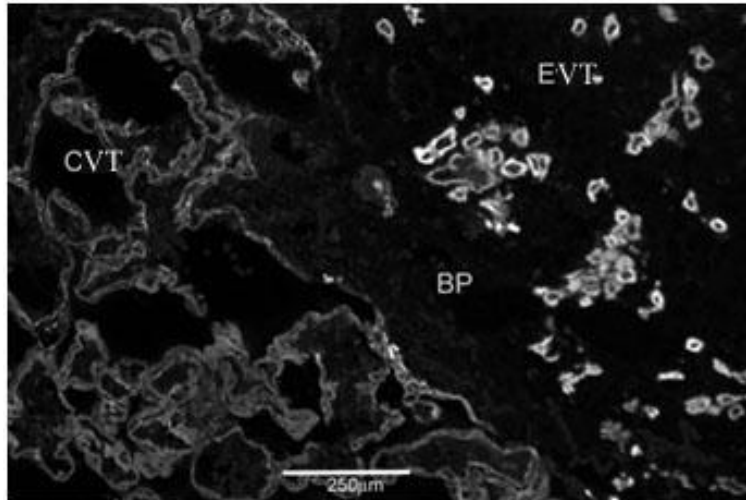
This is shown in the images below:




**Figure 3.1**

Anti-keratin 5 immunofluorescence of the basal plate tissue at term. See the low pixel intensity on the right hand side (CVT area) compared with the high pixel intensity on the left side (the EVT area) in the basal plate (BP). Scale bar = 250µm.

In figure 3.1, the pattern of high keratin pixel intensity in the EVTs and lower keratin pixel intensity in the CVT is uniform. There is no evidence of any significant expression of the keratin protein in any other cell present in the basal plate area and in the villus mesenchymal core and the intervillous spaces.



**Figure 3.2A**



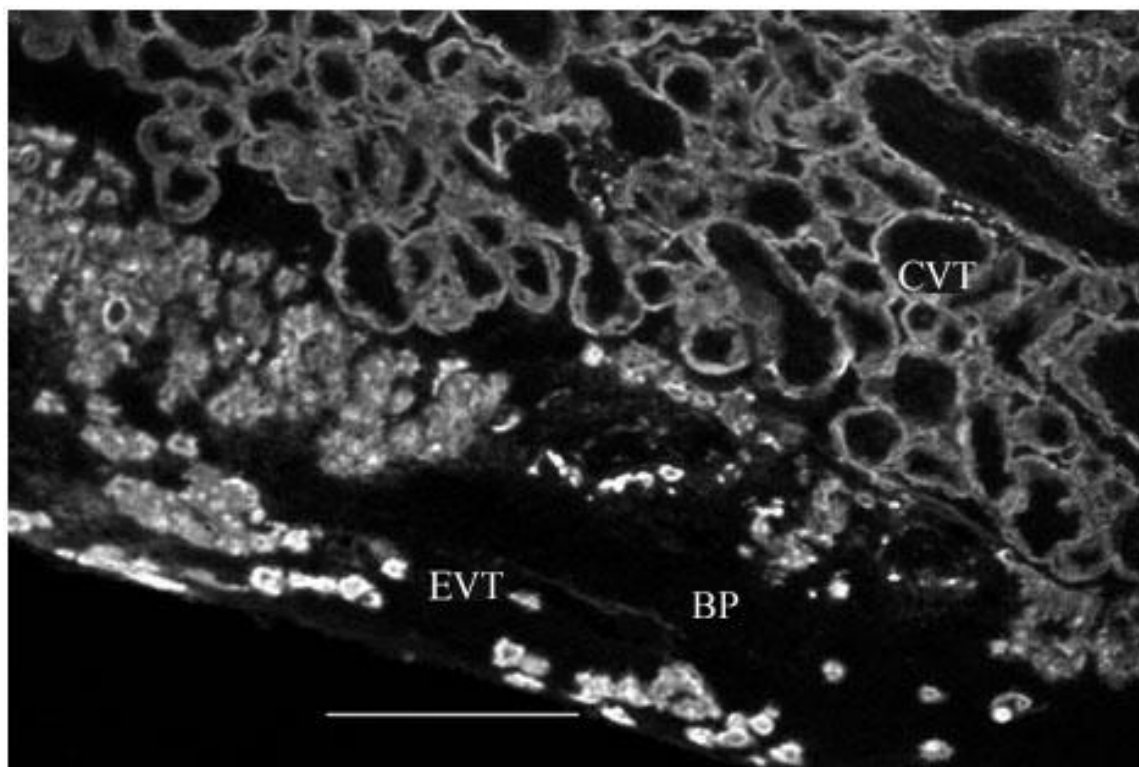
**Figure 3.2B**

3.2A. Keratin 7 distribution over the villous tree (CVT on the left) and basal plate (BP) with extravillous trophoblast (EVT on the right).

The immunofluorescence intensity is positive over the villous epithelium and the extravillous trophoblast cells but much more intense over the latter. The EVTs are scattered in the basal plate area.

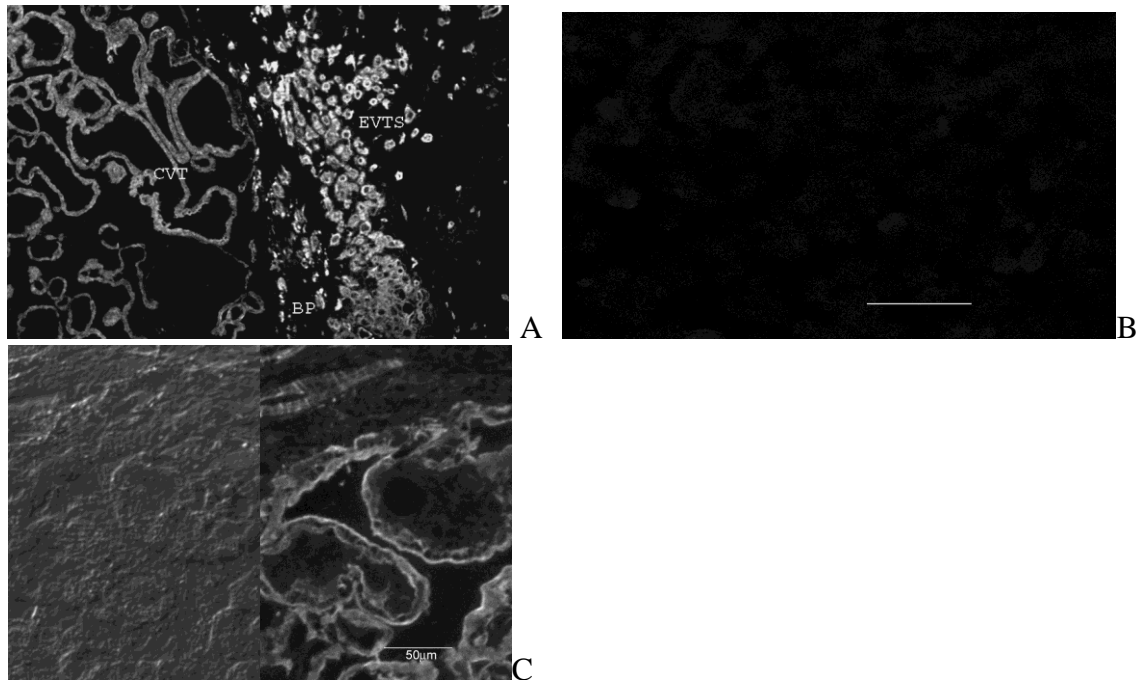
3.2B. Isotype control with mouse IgG<sub>1</sub> at the same dilution of 1: 150 as the anti-K7 antibody above. Scale bar = 250 μm.

The blank micrograph represents an image taken at the same setting as figure 3.2A on the CLSM but no immuno-reaction seen above background level. Isotype controls were used to assess the degree of non-specific binding of the experimental antibody.



**Figure 3.3**

Anti-keratin 8 immunofluorescence in basal plate tissue (BP). The immunofluorescence intensity is greater over the extravillous trophoblast (EVT) than over the chorionic villous trophoblast (CVT). Scale bar = 250 $\mu$ m.



**Figure 3.4A**

Anti-keratin 18 immunofluorescence in term placental basal plate tissue. The immunofluorescence intensity is much greater over the extravillous trophoblast (EVTs) in the basal plate (BP) than the chorionic villous trophoblast (CVT). The immunofluorescence pattern in the CVT appears to be uniform at the apical and basal surfaces of the villi. The EVTs are clustered closer to the junction between the CVT and the BP but scattered away from the junction.

**Figure 3.4B**

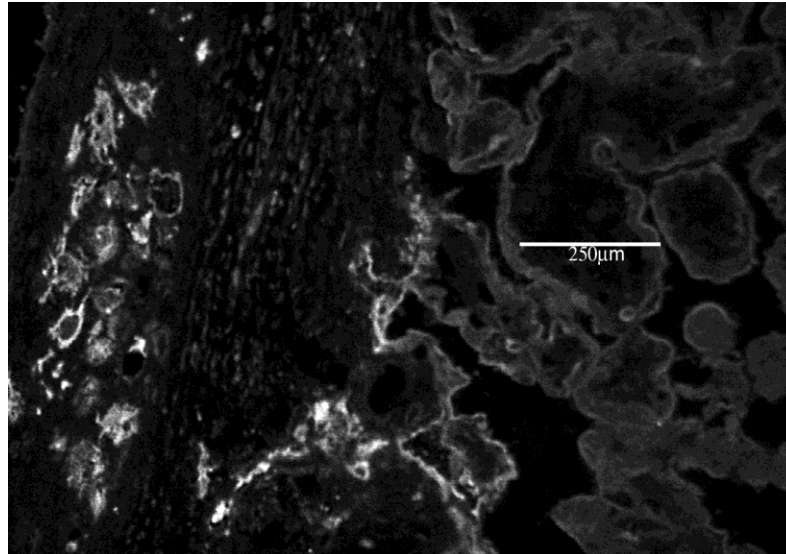
Isotype control of K18, Mouse IgG<sub>1</sub> at the same concentration of 1:1000 dilution as used for anti-keratin 18 over basal plate tissue. Scale bar = 250µm.

The control micrograph shows clearly non-immunoreactive basal plate tissue recorded using the same settings on the CLSM.

**Figure 3.4C**


A micrograph showing an anti-keratin 18 immunofluorescence over basal plate tissue on the right and a Nomarski Differential Interference Contrast (DIC) view on left showing the dry mass/ refractive index properties of the section. Note the anti-K18 labelling seems to show apical and basal immunoreactivity.

The villus mesenchymal core and the intervillous spaces appear to be completely blank or non-immunoreactive to anti-keratin 18 antibody.



**Figure 3.5A**

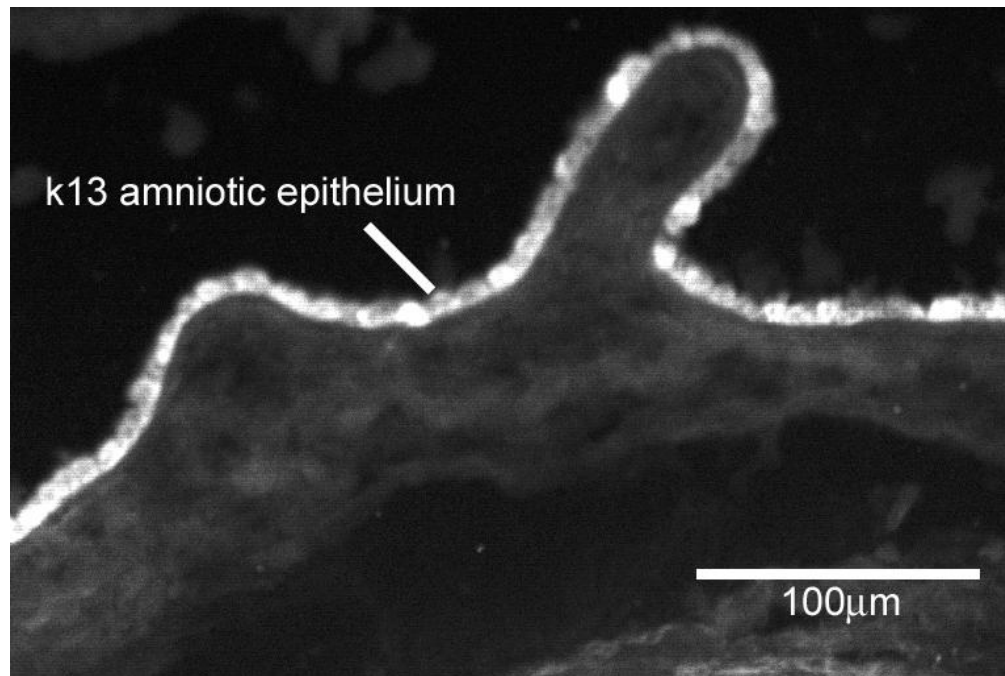
Anti-keratin 19 immunofluorescence over term placental basal plate tissue. The immunofluorescence intensity is much greater over the extravillous trophoblast on the left hand side than the chorionic villous trophoblast on the right hand side of the micrograph.



**Figure 3.5B**

IgG<sub>2a</sub> isotype control of K19 in basal plate tissue. Scale bar = 250µm  
There is no indication of immunofluorescence above background on the tissue although the micrograph was taken at the same settings as used to record figure 3.5A.






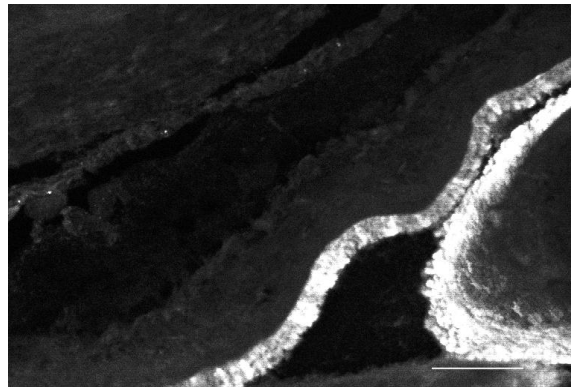
**Figure 3.6**

Anti-keratin 13 immunofluorescence of the amniochorion.

The expression of anti-K13 immunofluorescence appears to be variable but always present, bright in some cells and less so in others in the same epithelium. The dim areas may correspond to either senescent or immature cells.



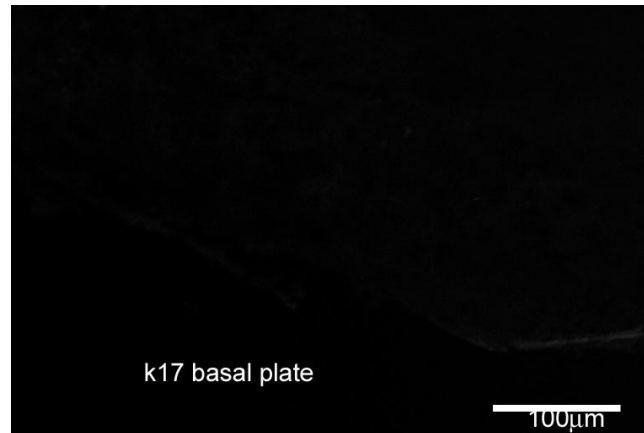
**Figure 3.7A**  
 Anti-keratin 14 immunofluorescence micrograph of term placental basal plate tissue. Note the weak immunofluorescence which is not above background levels.



**Figure 3.7B**  
 Anti-keratin 14 immunofluorescence of the amniotic epithelium at term. Note the bright immunofluorescence of the amniotic epithelium. Scale bar = 100µm

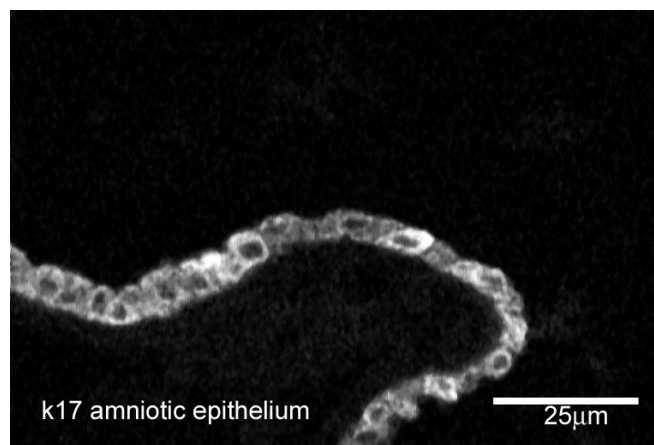


**Figure 3.7C**  
 Control micrograph of anti- Keratin 14 antibody over term placental basal plate tissue. Scale bar = 250µm.  
 K14 immunofluorescence which is undetected in the basal plate at term is expressed in the amnion.



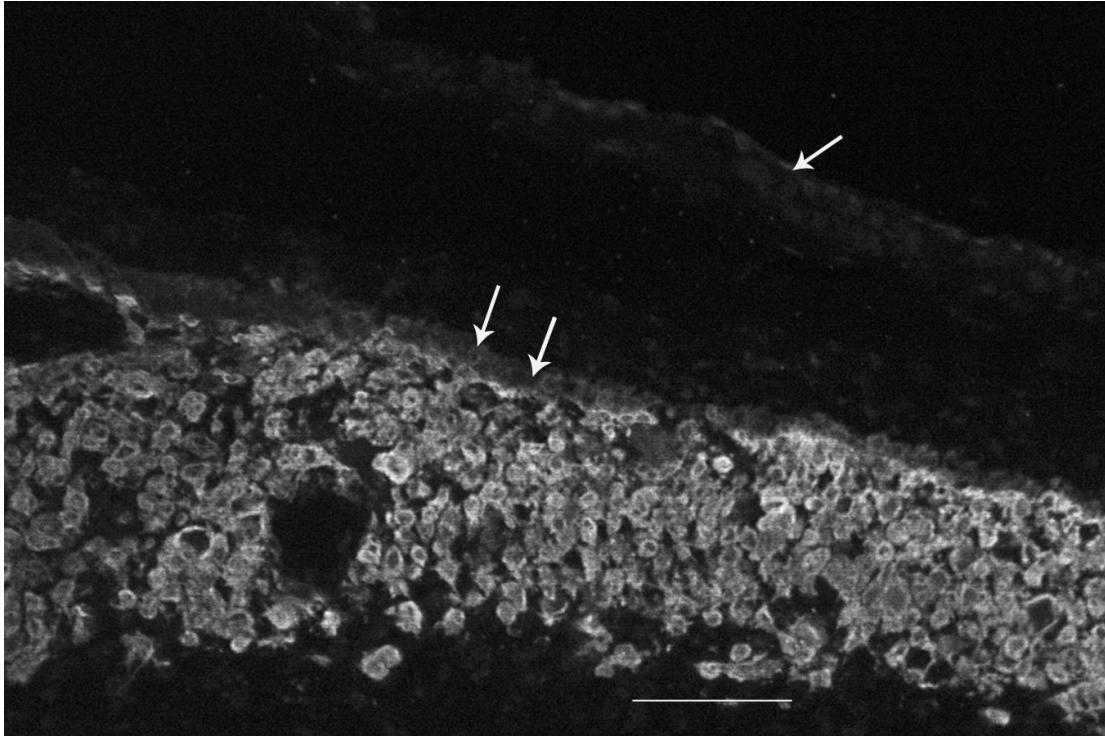
**Figure 3.8A**

Anti-keratin 17 immunofluorescence distribution over term placental basal plate tissue containing villous and extravillous trophoblast. The fluorescence intensity is below the background level of detection.



**Figure 3.8B**

Anti-keratin 17 immunofluorescence distribution over the chorion laeve taken at a high magnification (using the X63, 1.4NA, objective lens). The immunofluorescence is intense over the amniotic epithelium cytoplasm. Note that the compact, fibroblast, spongy and reticular layers and the chorion laeve trophoblast cell are unlabelled.



**Figure 3.9**

Anti-keratin 7 immunofluorescence of amniochorion. Note that the amniotic epithelium (single arrow) is scarcely above background levels whereas the EVTs in the chorion (double arrows) are highly immunoreactive. Scale bar = 250 $\mu$ m.

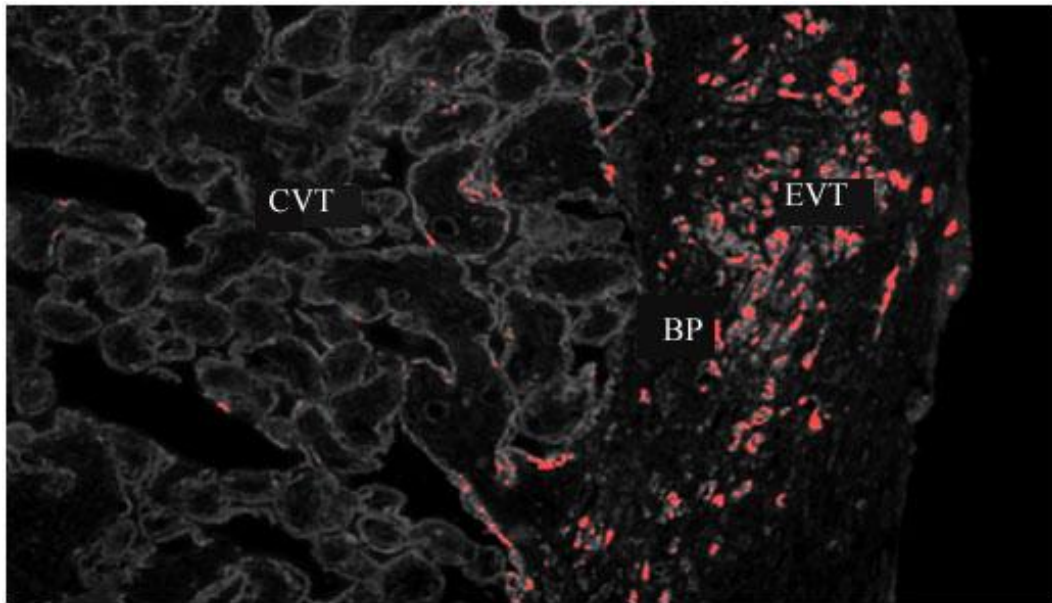
### 3.2.1 CLSM QUANTIFICATION

Preliminary work showed no regional variations in keratin expression in the samples A, B, C, and D taken from the placenta basal plate tissues (refer to chapter 2.2 diagram 2.1). The degree of difference in immunofluorescence intensity in the basal plate tissues was highlighted by a procedure called banding (Ockleford *et al.*, 2004), where a threshold of immunofluorescence intensity is set on the confocal microscope using the COMOS software and all pixels of a particular grey-scale value in an image above that level of intensity are colour coded (in this work red).

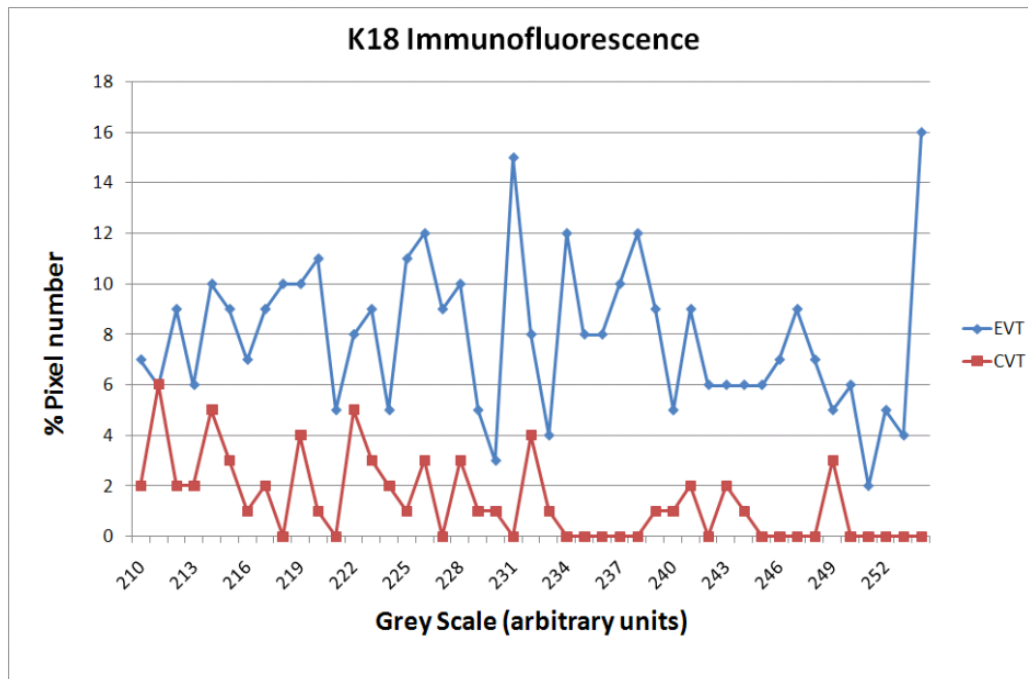
A plot of the incidence of high intensity pixels in the range 210-255 (arbitrary units) on the gray scale comparing areas of image occupied by EVT (blue) and CVT (pink) shows a consistent excess of high percentage pixels in the EVT area.

This is represented in the following micrographs and graphs.

An indirect immunofluorescence preparation using anti-keratin 18, a representative of type I keratin is shown in Figure 3.10A and a graph of percentage pixel intensity below it Figure 3.10B. Figure 3.11A represents an indirect immunofluorescence preparation using anti-keratin 7, a representative of type II keratin and a graph of percentage pixel intensity below it Figure 3.11B.



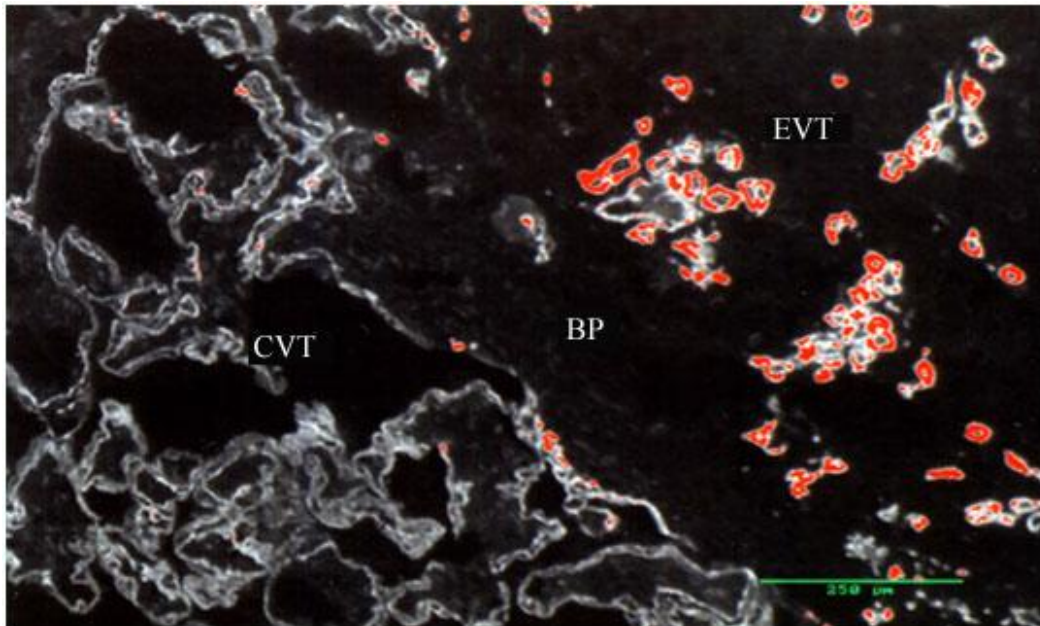
**Figure 3.10A**



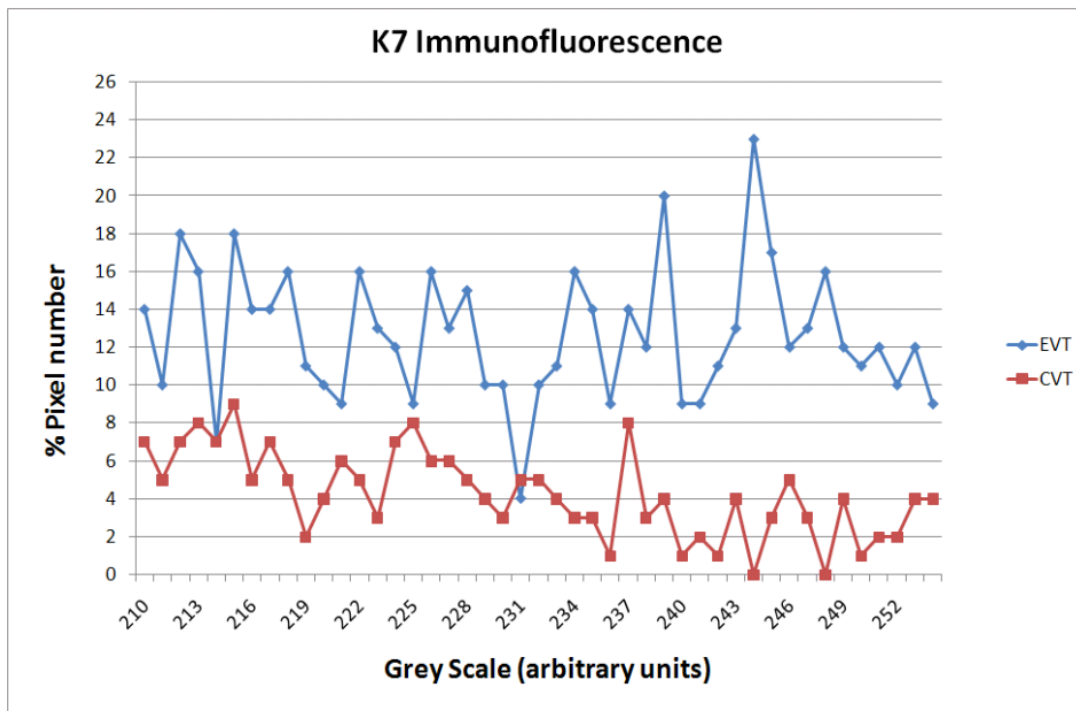
**Figure 3.10B**

The graph (Figure 3.10B) shows the pixel intensity distribution over areas of chorionic villous trophoblast (pink line) and extravillous trophoblast (blue line) when indirect immuno-fluorescence preparations of keratin 18 are imaged. The areas sampled for the intensity distribution graphs are shown above (Figure 3.10A) and the pixels of highest

greyscale value (210–255) equivalent to immuno-fluorescence intensity have been banded red. The red banding corresponds to the location of EVT and is only infrequently seen in chorionic villous trophoblast (CVT).



A



B

### Figure 3.11A & B

A) Micrograph of an indirect immuno-fluorescence preparation using anti-keratin 7. The areas sampled for the intensity distribution graphs (B) are shown and the pixels of highest grey scale value (210–255) equivalent to immunofluorescence intensity have been banded red. The red banding corresponds to the location of EVT and is only infrequently

seen in chorionic villous trophoblast (CVT). The graph shows the pixel intensity distribution of high greyscale pixels within this brightness band over areas of chorionic villous trophoblast (pink line) and extravillous trophoblast (blue line).

**TABLE 3. K5 STATISTICS**

TISSUE	n	Minimum	Maximum	% Median Pixel value	25 <sup>th</sup> percentile	75 <sup>th</sup> percentile
CVTp	112	0.00	1.74	0.06	0.00	0.19
EVTp	112	0.05	12.77	2.97	1.60	4.71
CVTh	150	0.00	3.53	0.14	0.02	0.37
EVTh	150	0.09	10.29	2.88	1.80	4.84

Table 3 Legend:

The table shows the results of statistical analysis of keratin 5 (K5) immunofluorescence intensity data in pre-eclamptic chorionic villous trophoblast (CVTp), pre-eclamptic extravillous trophoblast (EVTp) and their control tissues (CVTh and EVTh). The statistical significant level was set at  $p < 0.05$ , \*\*\* significant and ns = non-significant. Outcomes were assigned as follows:-

Wilcoxon sign-rank test:

Comparing CVTp and EVTp [  $Z = -9.186$ ,  $p < 0.0001$  ]\*\*\*

Comparing CVTh and EVTh [  $Z = -10.612$ ,  $p < 0.0001$  ]\*\*\*

Two sample Wilcoxon rank-sum (Mann-Whitney) Test:

Comparing CVTp and CVTh [  $Z = 2.653$ ,  $p = 0.0080$  ]\*\*\*

Comparing EVTp and EVTh [  $Z = 0.410$ ,  $p = 0.6821$  ]ns

**TABLE 4. KERATIN 7 STATISTICS**

TISSUE	n	Minimum	Maximum	% Median Pixel value	25 <sup>th</sup> percentile	75 <sup>th</sup> percentile
CVTp	95	0.00	4.10	0.04	0.00	0.18
EVTp	95	0.03	15.94	2.93	1.36	6.08
CVTh	95	0.00	5.60	0.17	0.02	0.75
EVTh	95	0.01	17.97	4.06	1.76	7.07

Table 4 Legend:

The table shows the results of statistical analysis of keratin 7 (K7) immunofluorescence intensity data in pre-eclamptic chorionic villous trophoblast (CVTp), pre-eclamptic extravillous trophoblast (EVTp) and their control tissues (CVTh and EVTh). The statistical significant level was set at  $p < 0.05$  \*\*\* significant and ns = non-significant. Outcomes were assigned as follows:-

Wilcoxon sign-rank test:

Comparing CVTp and EVTp [  $Z = -8.463$ ,  $p < 0.0001$  ]\*\*\*

Comparing CVTh and EVTh [  $Z = -8.248$ ,  $p < 0.0001$  ]\*\*\*



Two sample Wilcoxon rank-sum (Mann-Whitney) Test:  
 Comparing CVTp and CVTh [Z = -3.262, p = 0.0011]\*\*\*  
 Comparing EVTp and EVTh [Z = -1.509, p = 0.1312 ]ns

**TABLE 5. KERATIN 8 STATISTICS**

TISSUE	n	Minimum	Maximum	% Median Pixel value	25 <sup>th</sup> percentile	75 <sup>th</sup> percentile
CVTp	89	0.00	7.22	0.03	0.00	0.20
EVTp	89	0.60	11.40	1.86	1.13	3.55
CVTh	89	0.00	8.96	0.32	0.03	0.88
EVTh	89	0.17	13.75	2.88	1.00	4.86

Table 5 Legend:

The table shows the results of statistical analysis of keratin 8 (K8) immunofluorescence intensity data in pre-eclamptic chorionic villous trophoblast (CVTp), pre-eclamptic extravillous trophoblast (EVTp) and their control tissues (CVTh and EVTh). The statistical significant level was set at p< 0.05 \*\*\* significant and ns = non-significant. Outcomes were assigned as follows:-

Wilcoxon sign-rank test:

Comparing CVTp and EVTp [ Z = -7.974, p = 0.0001]\*\*\*

Comparing CVTh and EVTh [ Z = -7.624, p = 0.0001]\*\*\*

Two sample Wilcoxon rank-sum (Mann-Whitney) Test:

Comparing CVTp and CVTh [Z = -3.342, p = 0.0008]\*\*\*

Comparing EVTp and EVTh [Z = -1.751, p = 0.0799 ]ns

**TABLE 6. KERATIN 18 STATISTICS**

TISSUE	n	Minimum	Maximum	% Median Pixel value	25 <sup>th</sup> percentile	75 <sup>th</sup> percentile
CVTp	85	0.00	2.44	0.08	0.00	0.23
EVTp	85	0.00	11.66	2.11	1.00	4.12
CVTh	85	0.00	7.18	0.50	0.18	1.05
EVTh	85	0.11	14.66	2.90	1.54	4.70

Table 6 Legend:

The table shows the results of statistical analysis of keratin 18 (K18) immunofluorescence intensity data in pre-eclamptic chorionic villous trophoblast (CVTp), pre-eclamptic extravillous trophoblast (EVTp) and their control tissues (CVTh and EVTh). The statistical significant level was set at p< 0.05 \*\*\* significant and ns = non-significant.

Outcomes were assigned as follows:-

Wilcoxon sign-rank test:

Comparing CVTp and EVTp [ Z = -7.905, p = 0.0001]\*\*\*

Comparing CVTh and EVTh [ Z = -7.328, p = 0.0001]\*\*\*

Two sample Wilcoxon rank-sum (Mann-Whitney) Test:  
 Comparing CVTp and CVTh [Z = -6.117, p = 0.0001]\*\*\*  
 Comparing EVTp and EVTh [Z = -1.789, p = 0.0736 ]ns

**TABLE 7. KERATIN 19 STATISTICS**

TISSUE	n	Minimum	Maximum	% Median Pixel value	25 <sup>th</sup> percentile	75 <sup>th</sup> percentile
CVTp	83	0.00	1.97	0.01	0.00	0.06
EVTp	83	0.00	9.26	0.62	0.21	1.77
CVTh	83	0.00	1.38	0.04	0.00	0.10
EVTh	83	0.00	9.50	1.06	0.42	2.45

Table 7 Legend:

The table shows the results of statistical analysis of keratin 19 (K19) immunofluorescence intensity data in pre-eclamptic chorionic villous trophoblast (CVTp), pre-eclamptic extravillous trophoblast (EVTp) and their control tissues (CVTh and EVTh). The statistical significant level was set at p< 0.05 \*\*\* significant and ns = non-significant.

Outcomes were assigned as follows:-

Wilcoxon sign-rank test:

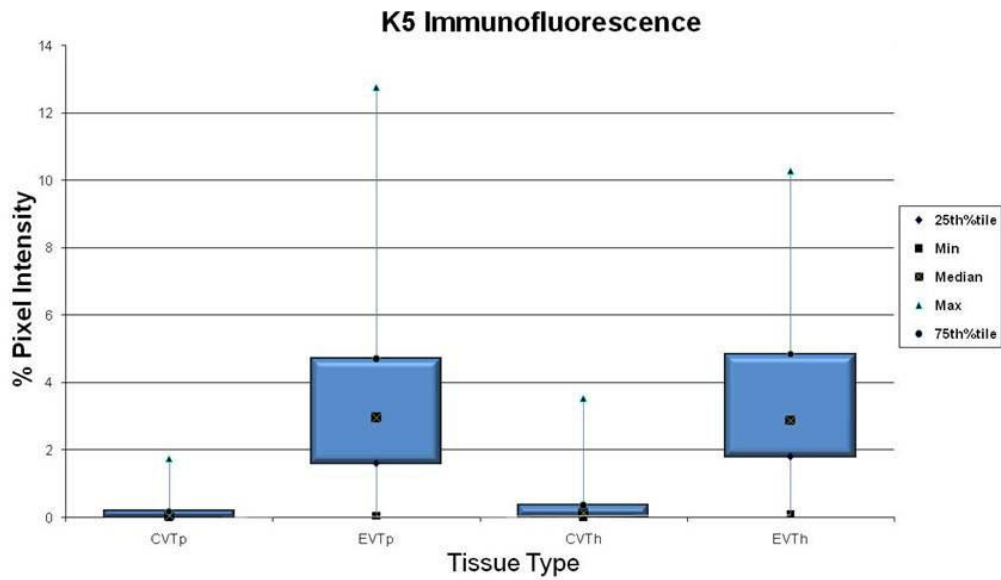
Comparing CVTp and EVTp [ Z = -7.478, p = 0.0001]\*\*\*

Comparing CVTh and EVTh [ Z = -7.693, p = 0.0001]\*\*\*

Two sample Wilcoxon rank-sum (Mann-Whitney) Test:

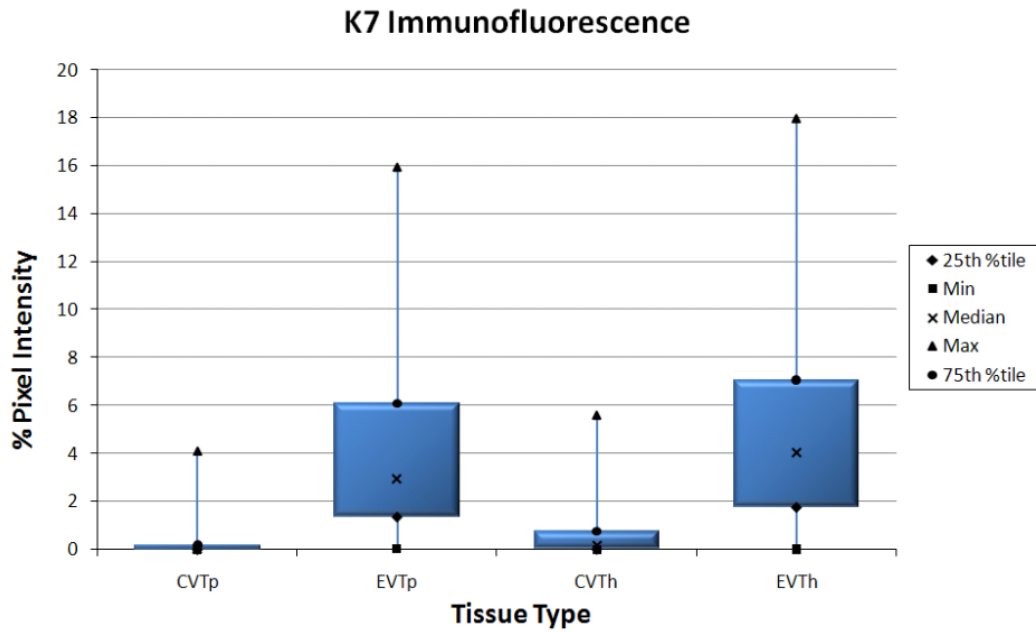
Comparing CVTp and CVTh [Z = -1.941, p = 0.0522]\* THRESHOLD

Comparing EVTp and EVTh [Z = -1.789, p = 0.0736 ]ns



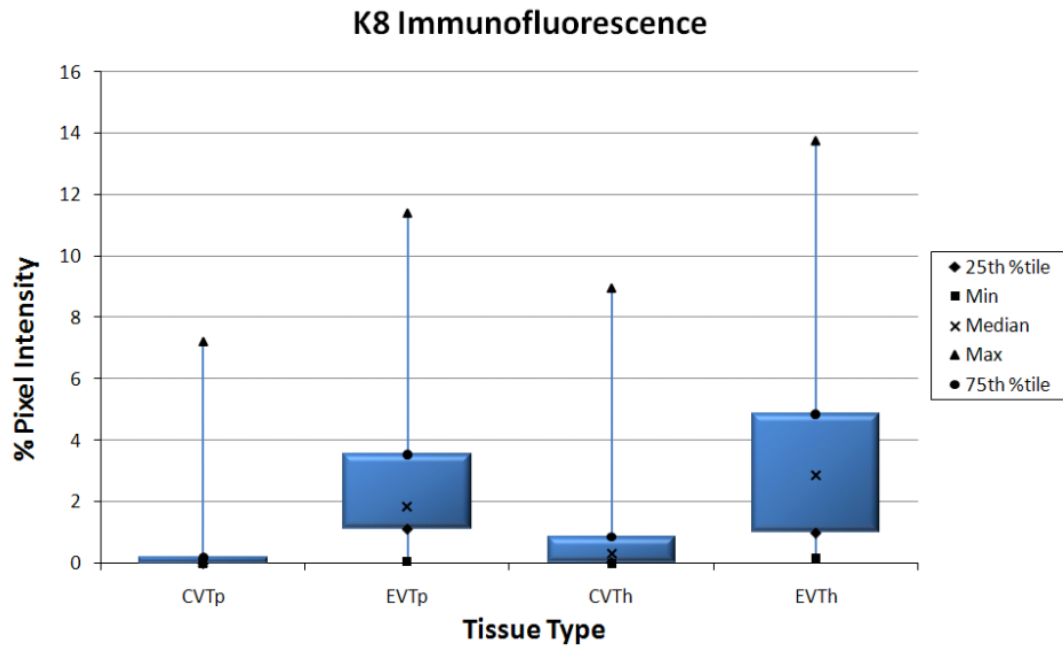
**Figure 3.12**

Boxplot showing the interquartile range of the CLSM immunofluorescence data using the anti-keratin 5 antibody on pre-eclamptic chorionic villous trophoblast (CVTp) and extravillous trophoblast (EVTp) and healthy chorionic villous trophoblast (CVTh) and extravillous trophoblast (EVTh). The minimum, median and maximum values are indicated by the key and the whisker shows the range.



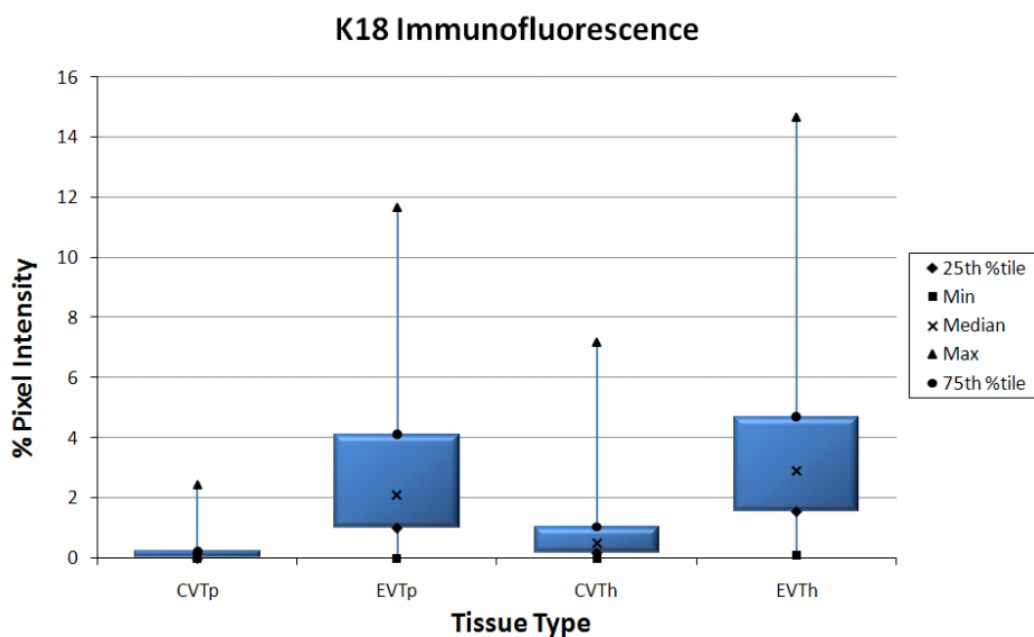
**Figure 3.13**

Boxplot showing the interquartile range of the CLSM immunofluorescence data using the anti-keratin 7 antibody on pre-eclamptic chorionic villous trophoblast (CVTp) and extravillous trophoblast (EVTp) and healthy chorionic villous trophoblast (CVTh) and extravillous trophoblast (EVTh). The minimum, median and maximum values are indicated by the key and the whisker shows the range.



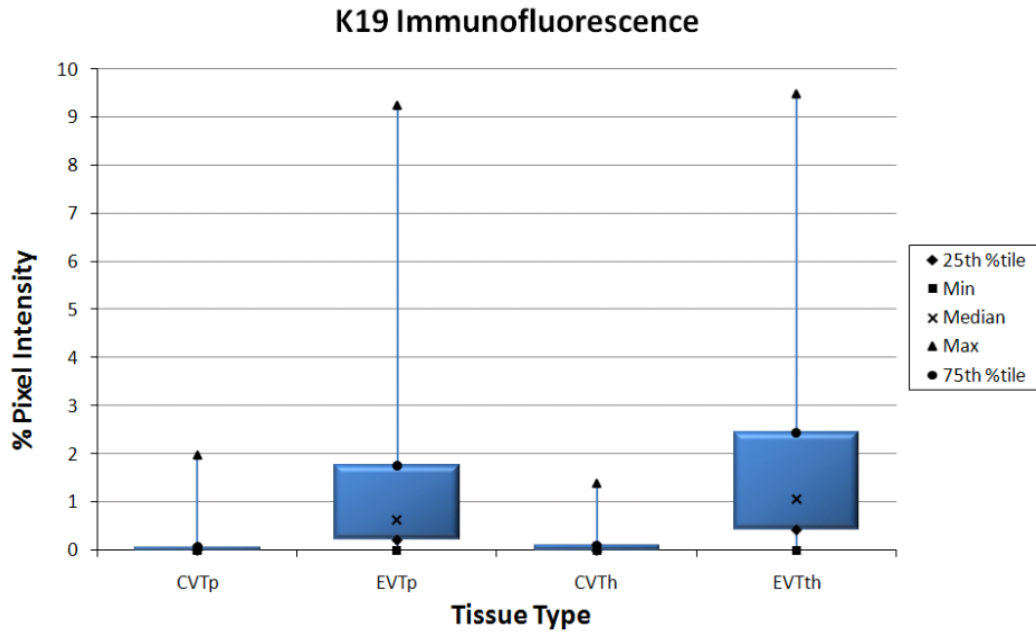
**Figure 3.14**

Boxplot showing the interquartile range of the CLSM immunofluorescence data using the anti-keratin 8 antibody on pre-eclamptic chorionic villous trophoblast (CVTp) and extravillous trophoblast (EVTp), also healthy chorionic villous trophoblast (CVTh) and extravillous trophoblast (EVTh). The minimum, median and maximum values are indicated by the key and the whisker shows the range.



**Figure 3.15**

Boxplot showing the interquartile range of the CLSM immunofluorescence data using the anti-keratin 18 antibody on pre-eclamptic chorionic villous trophoblast (CVTp) and extravillous trophoblast (EVTp), also healthy chorionic villous trophoblast (CVTh) and extravillous trophoblast (EVTh). The minimum, median and maximum values are indicated by the key and the whisker shows the range.

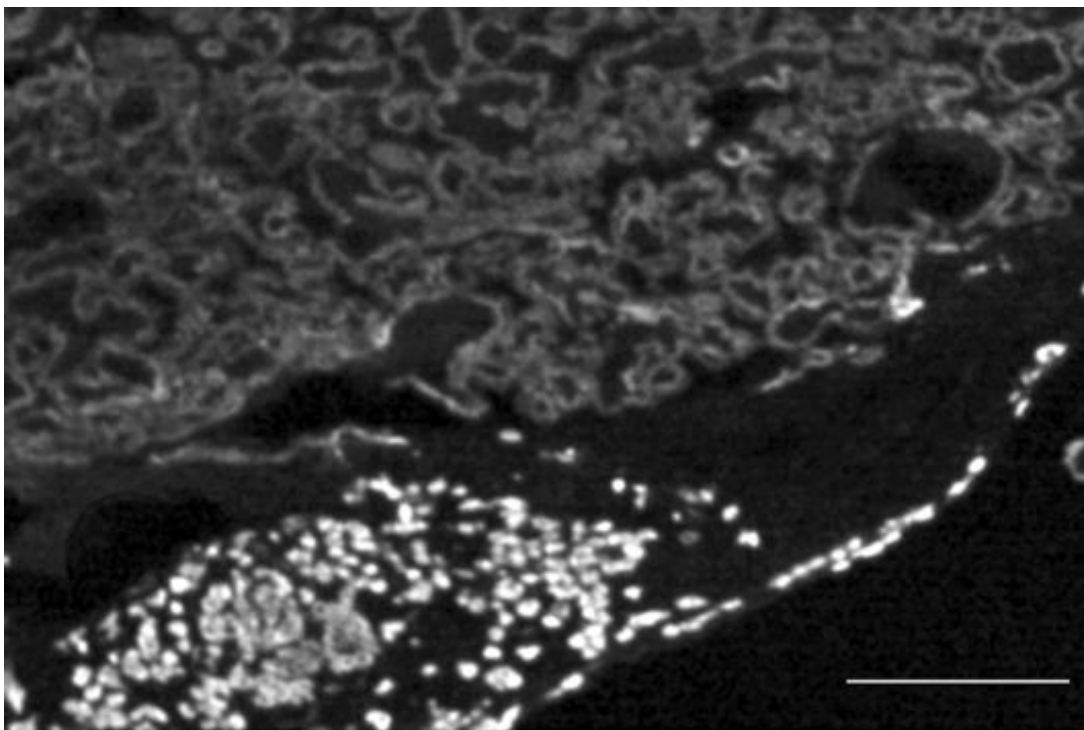


**Figure 3.16**

Boxplot showing the interquartile range of the CLSM immunofluorescence data using the anti-keratin 19 antibody on pre-eclamptic chorionic villous trophoblast (CVTp) and extravillous trophoblast (EVTp), also healthy chorionic villous trophoblast (CVTh) and extravillous trophoblast (EVTth). The minimum, median and maximum values are indicated by the key and the whisker shows the range.

### 3.2.2 Distribution of extravillous trophoblast in basal plate tissue at term

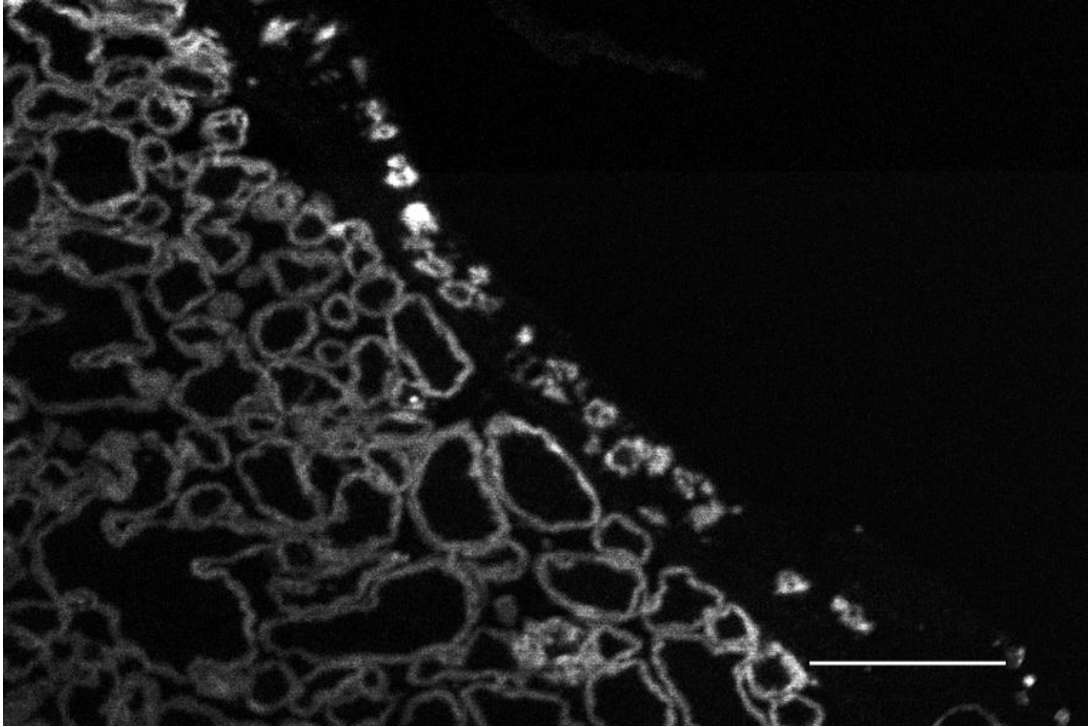
A feature of the anti-keratin immunofluorescence of the extravillous trophoblast cells, which stands out clearly are their uneven distribution. There are instances of clustering and linearization of the extravillous trophoblastic cells in the basal plate tissue (Figure 3.17A&B).



**Figure 3.17A**

Immunofluorescence of anti-keratin 7 showing a cluster of brightly immunofluorescent EVTs and a linear stretch of EVTs (lower right) in the basal plate tissue. Note the less immunoreactive CTs compared with the more immunoreactive EVTs. Scale bar = 100µm.





**Figure 3.17B**

Anti-keratin 5 immunofluorescence of the basal plate tissue showing a linear stretch of EVT's. Note the difference between the less immunoreactive chorionic villi on the left and the more immunoreactive EVT's forming the linear array in the basal plate. Scale bar = 250 $\mu$ m

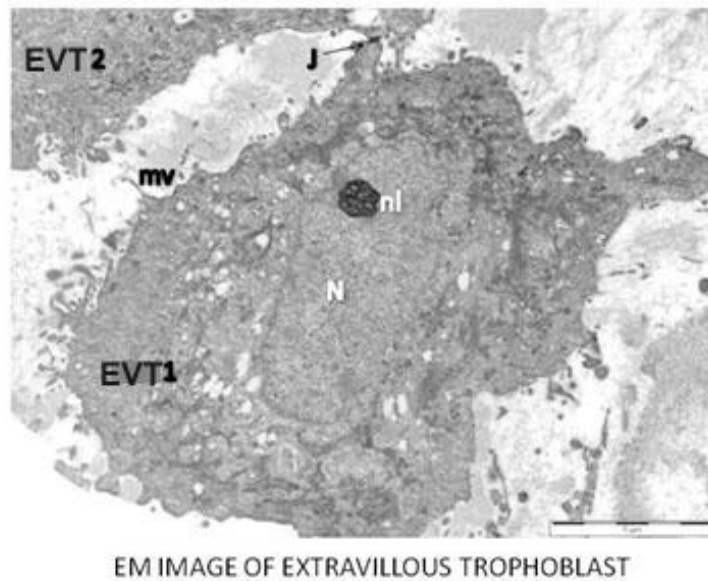
### **3.2.3 Summary of indirect-immunofluorescence confocal laser scanning microscopy**

It has been demonstrated that keratins (K7, K8, K18, and K19) applied individually on the same tissue samples and K5 antibody applied to independent samples were “upregulated” during the differentiation pathway from the villous to the extravillous trophoblast stage in a highly statistically significant manner.

However, keratins 1,2,3,4,6,9,10,12,13,14,15,16,17, 20 and 23 were not detected in the basal plate tissue at term in both healthy and pre-eclamptic placentae.

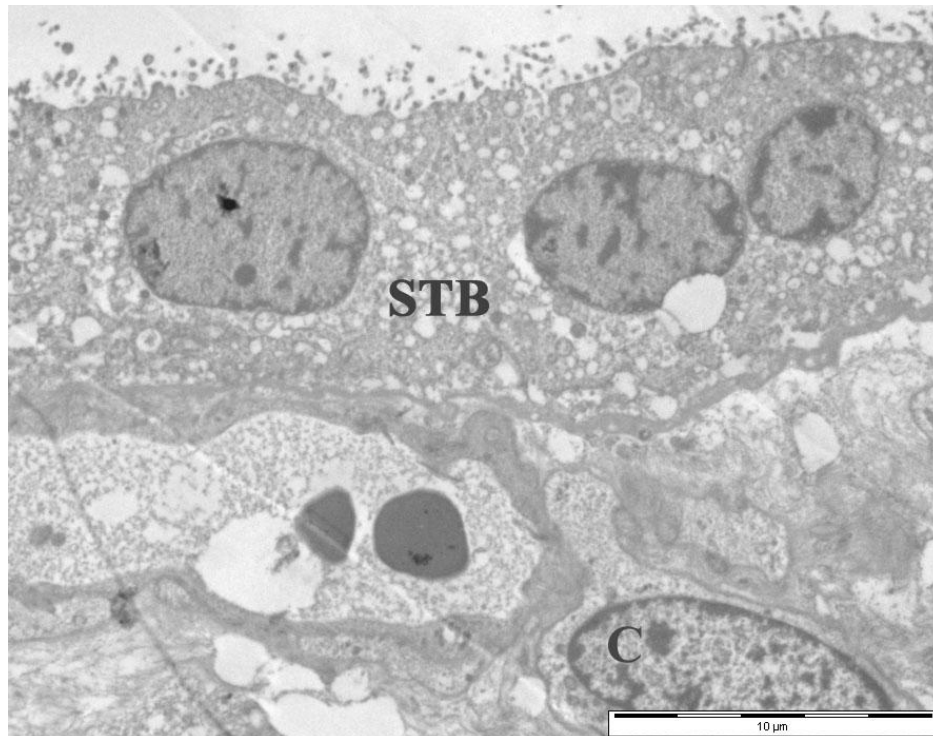
K4, 5, 6, 8, 10, 13, 14, 17, 18 and 19 were expressed in the amniotic epithelium with the exception of keratins 1, 2,3,7,9,12,15,16, 20 and 23 which were not detected.

### 3.3 IMMUNOGOLD ELECTRON MICROSCOPY RESULTS



**Figure 3.18**

Electron micrograph of extravillous trophoblastic cells EVT1 and EVT2 in the basal plate tissue. N = nucleus, nl = nucleolus, mv = microvilli and J = cell junction formed by the two EVT's. Scale bar = 5.0 $\mu$ m

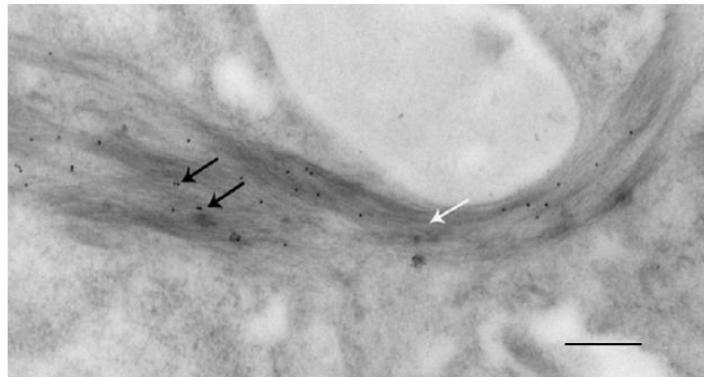


**Figure 3.19**

An electron micrograph of term human placental chorionic villous trophoblast showing a row of 3 syncytiotrophoblastic (STB) nuclei and a single cytotrophoblastic cell (C). Scale bar = 10.0μm

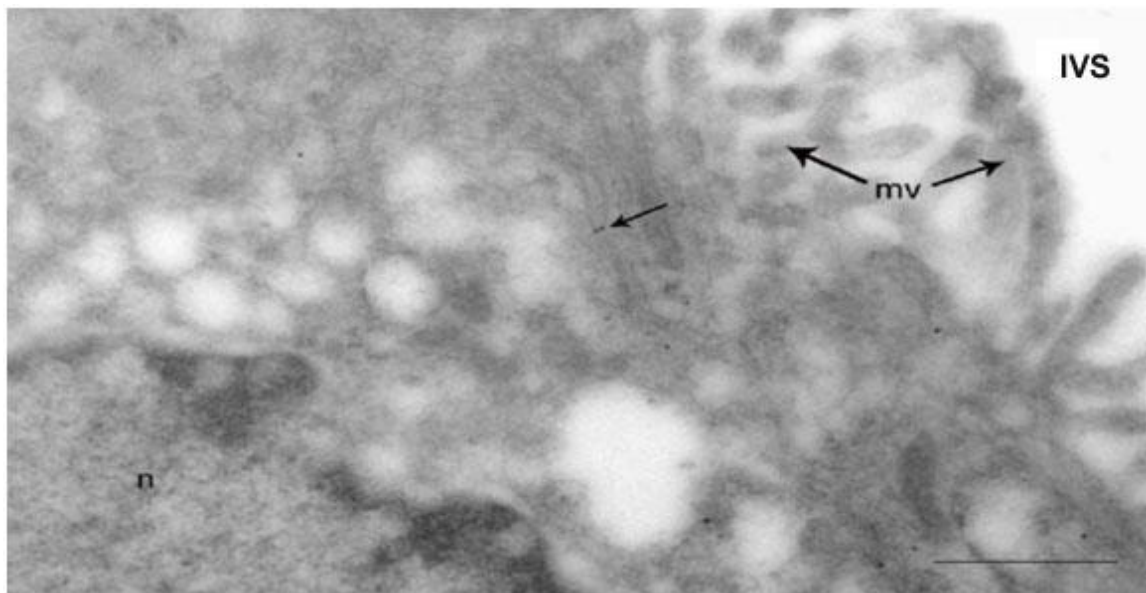
### 3.3.1 IMMUNOGOLD LABELLING OF KERATIN INTERMEDIATE FILAMENTS

Electron micrographs of trophoblast anti-keratin 7 and 18 immuno-gold labelling show clearly that this is predominantly overlying bundles of intermediate filaments. It does not occur over the nuclei, other cytoplasmic inclusions and cells of mesodermal origin (Figures 3.20-3.22).



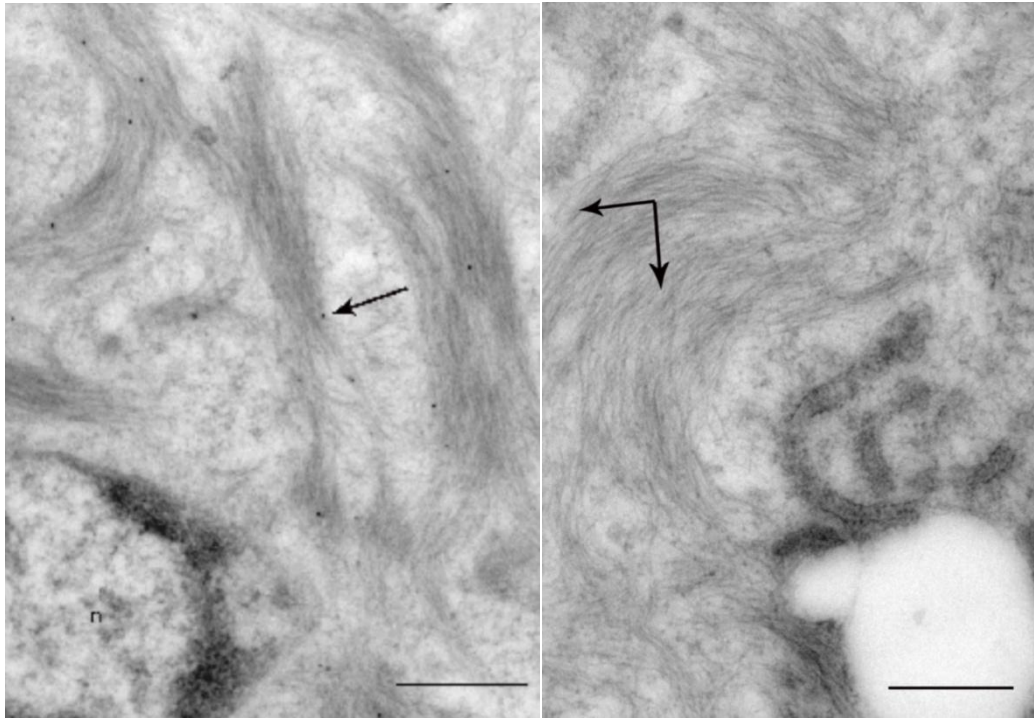
**Figure 3.20**

Transmission electron micrograph of intermediate filament bundles associated with anti-keratin 18 coated 10nm colloidal gold particles of an EVT cell. Gold particles (black arrows) are seen over the filament bundle (white arrow) but not the surrounding cytoplasm. Scale bar = 1.0 $\mu$ m



**Figure 3.21**

This transmission electron micrograph of chorionic villous trophoblast shows relatively few keratin fibres and correspondingly less anti-keratin 18 conjugated gold particles (arrow). Note that areas such as the nucleus (n), microvilli (mv) and intervillous space (IVS) are entirely unlabelled with gold particles. Scale bar = 1.0 $\mu$ m



**Figure 3.22A &B**

- A) The intermediate filaments of an EVT cell associated with anti-keratin 7 conjugated 10nm gold particles (arrow) on the left, became detectable only after epitope unmasking. Note that the nucleus (n) and non-intermediate filament containing cytoplasm are unlabelled. Scale bar = 1.0 $\mu$ m
- B) Keratin filaments (2 arrow head) on the right without gold particles were observed in this negative control section of extravillous trophoblast exposed to colloidal gold in the absence of first step antibody to keratin 7. Scale bar = 1.0 $\mu$ m

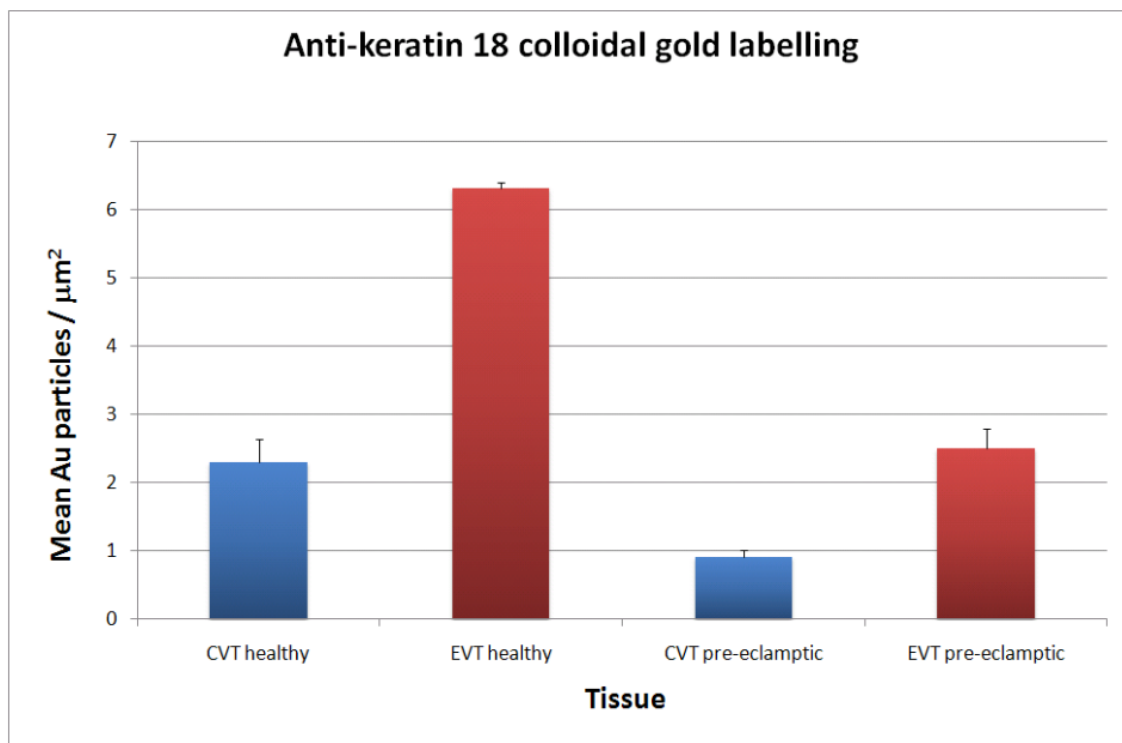
**TABLE 8: DESCRIPTIVE STATISTICS OF K18 IMMUNOGOLD LABELLING EXPERIMENT**

TISSUE	Observations (n)	Mean	Std.Err	Std.Dev	95% CI	
CVTh	11	2.289	0.349	1.157	1.5117	3.0663
CVTp	14	0.912	0.102	0.383	0.6909	1.1331
EVTh	14	6.301	0.850	3.182	4.4638	8.1382
EVTp	19	2.505	0.276	1.204	1.9247	3.0853

Table 8 Legend

Independent two sample t-test comparing CVTh and CVTp ( $t = 3.7876$ ,  $p < 0.0026$ )

Comparing EVTh and EVTp ( $t = 4.2453$ ,  $p < 0.0006$ ).



**Figure 3.23**

This bar chart indicates the relative greater immunoreactivity of extravillous trophoblast with anti-keratin 18 as compared with the chorionic villous trophoblast. There is a reduction of immunoreactivity in both tissues when the pregnancy is pre-eclamptic.



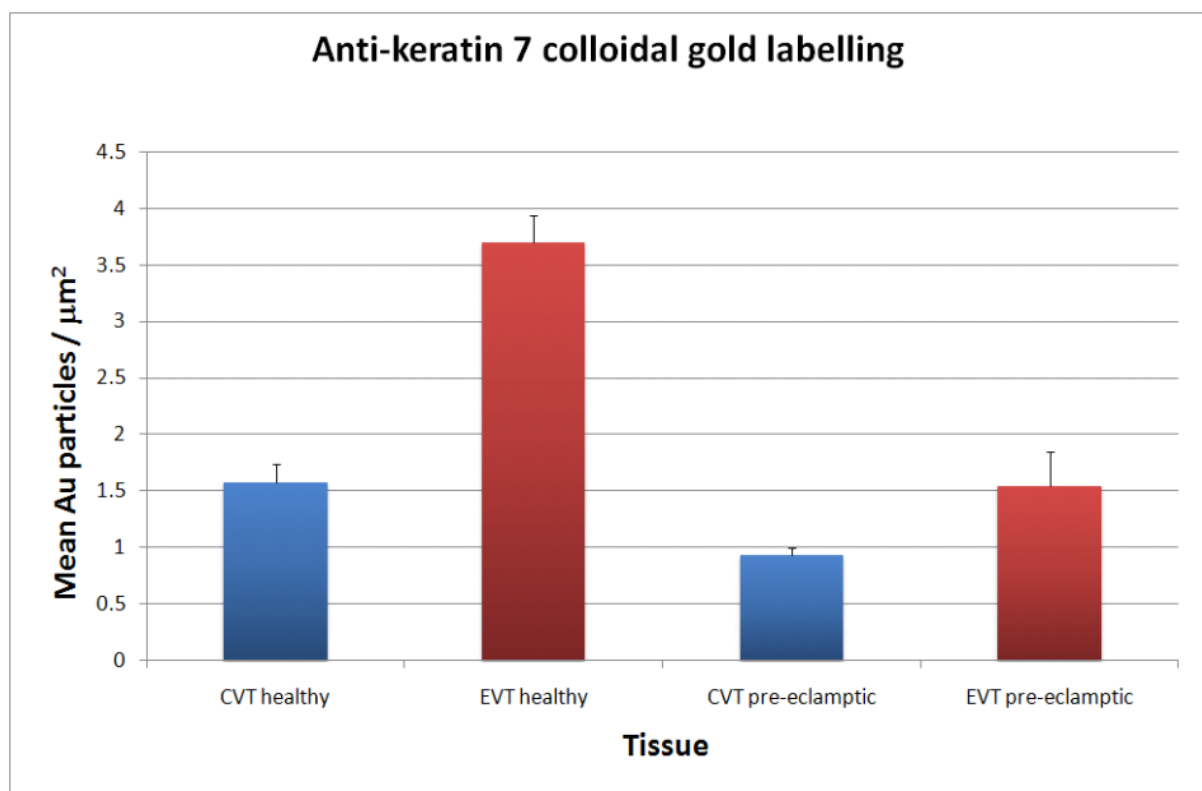
**Table 9: DESCRIPTIVE STATISTICS FOR K7 IMMUNOGOLD LABELLING EXPERIMENT**

TISSUE	Observations (n)	Mean	Std.Err	Std.Dev	95% CI	
CVTh	23	1.578	0.156	0.749	1.2542	1.9019
CVTp	14	0.926	0.075	0.280	0.7643	1.0877
EVTh	30	3.700	0.234	1.282	3.2213	4.1787
EVTp	21	1.545	0.298	1.368	1.9247	2.1677

Table 9 Legend

Independent two sample t-test comparing CVTh and CVTp ( $t = 3.7649$ ,  $p < 0.0007$ )

Comparing EVTh and EVTp ( $t = 5.6809$ ,  $p < 0.0001$ )

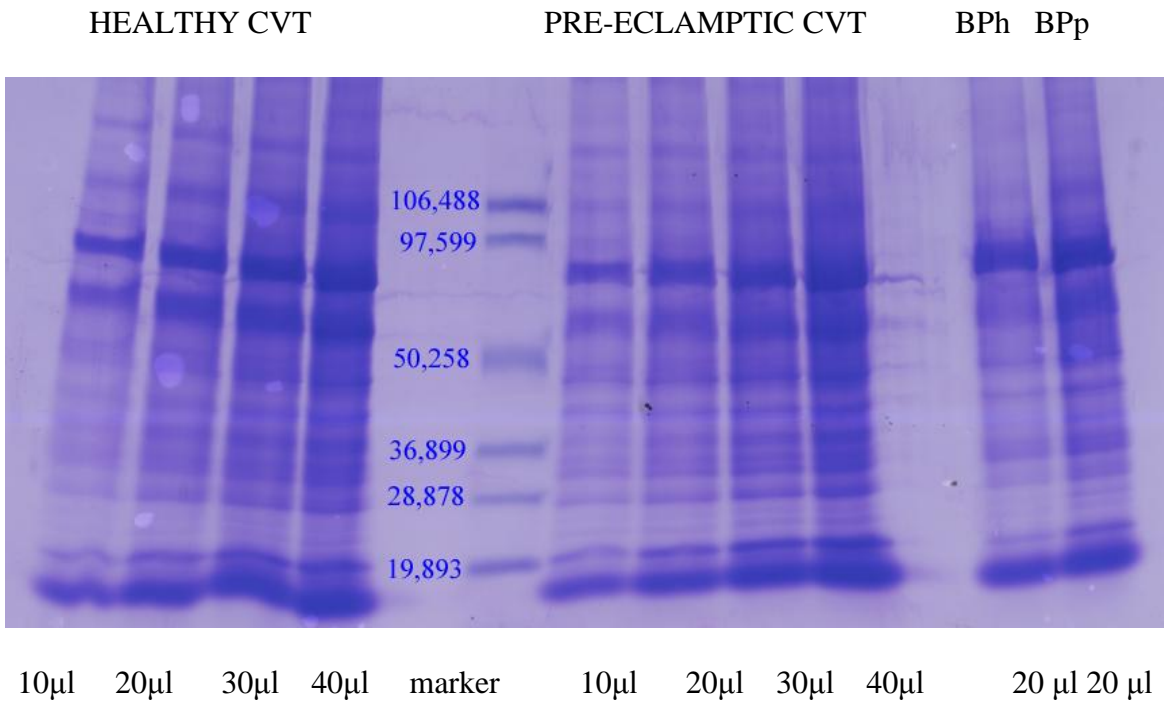


**Figure 3.24**

This bar chart indicates the relative greater immunoreactivity of extravillous trophoblast with anti-keratin 7 as compared with the chorionic villous trophoblast. There is a reduction of immunoreactivity in both tissues when the pregnancy is pre-eclamptic.

**3.4 VERIFICATION OF THE REACTIVITY OF KERATIN ANTIBODIES BY WESTERN BLOTTING**

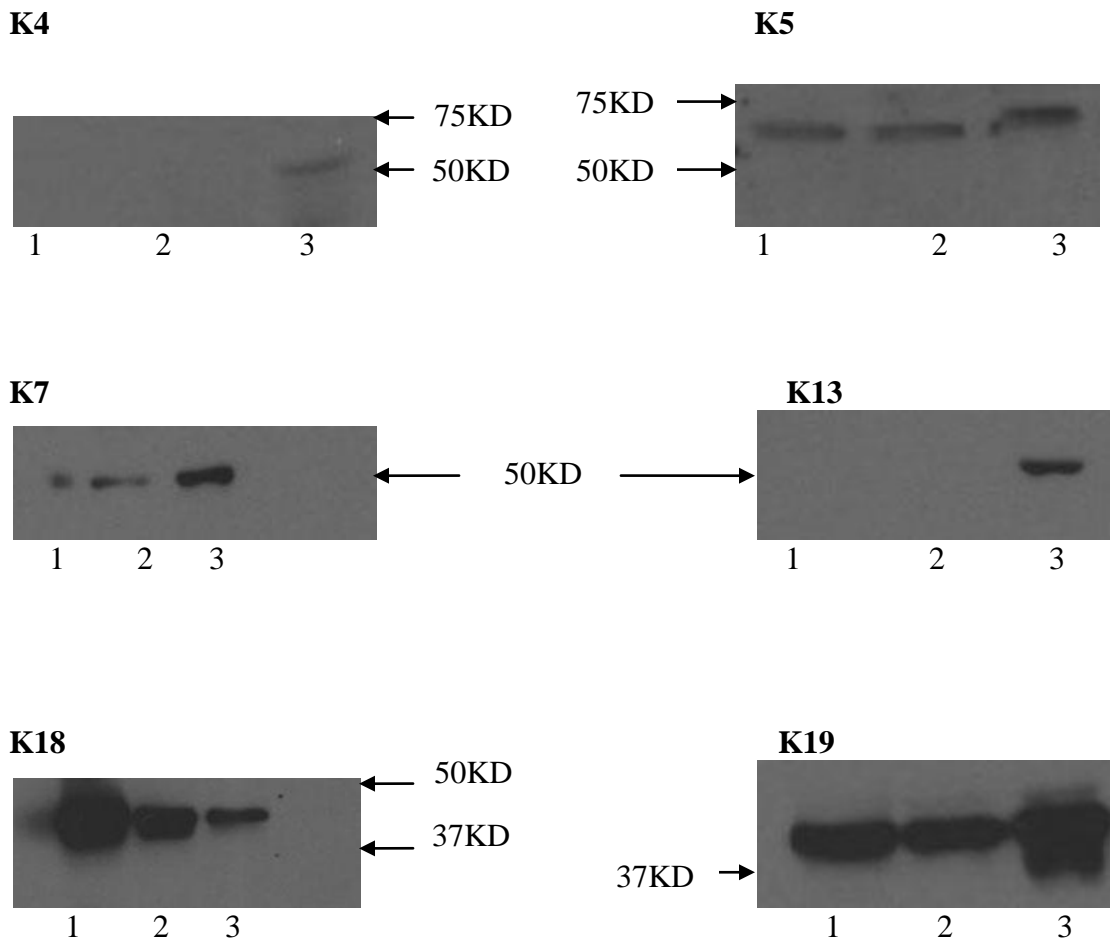
An SDS- PAGE separation of healthy, pre-eclamptic CVT and basal plate proteins under reducing condition, obtained from fine manual microdissection and titration to determine the appropriate amount to load into wells.



**Figure 3.25**

**Figure 3.26**

Immunoblots of some keratins expressed in CVT, basal plate and amniotic epithelium of the human term placenta. Lane 1 = CVT, lane 2 = basal plate, lane 3 = amnion

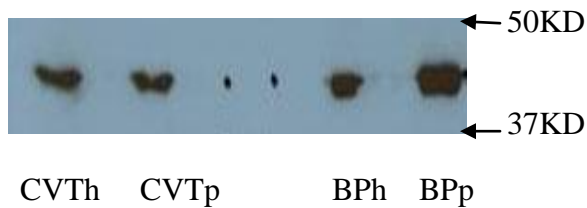


The K4 immunoblot shows K4 was absent from the CVT and basal plate tissues but present in the amnion. Compare this with K5 which is present in all three tissues.

K7 is expressed in all three tissues whereas K13 is only expressed in the amnion.

K18 and K19 are both expressed in all three tissues but it appears K18 is over expressed in the CVT whereas K19 is over expressed in the amnion.


Other anti-keratin antibodies tested such as K15 and K16 were not immunoreactive to CVT, basal plate or amnion sample lysates.



**Figure 3.27**

Immunoblot analysis of healthy chorionic villous trophoblast (CVTh), Pre-eclamptic chorionic villous trophoblast (CVTp), healthy basal plate (BPh) and pre-eclamptic basal plate (BPp) proteins using monoclonal anti-keratin 18 (K18).

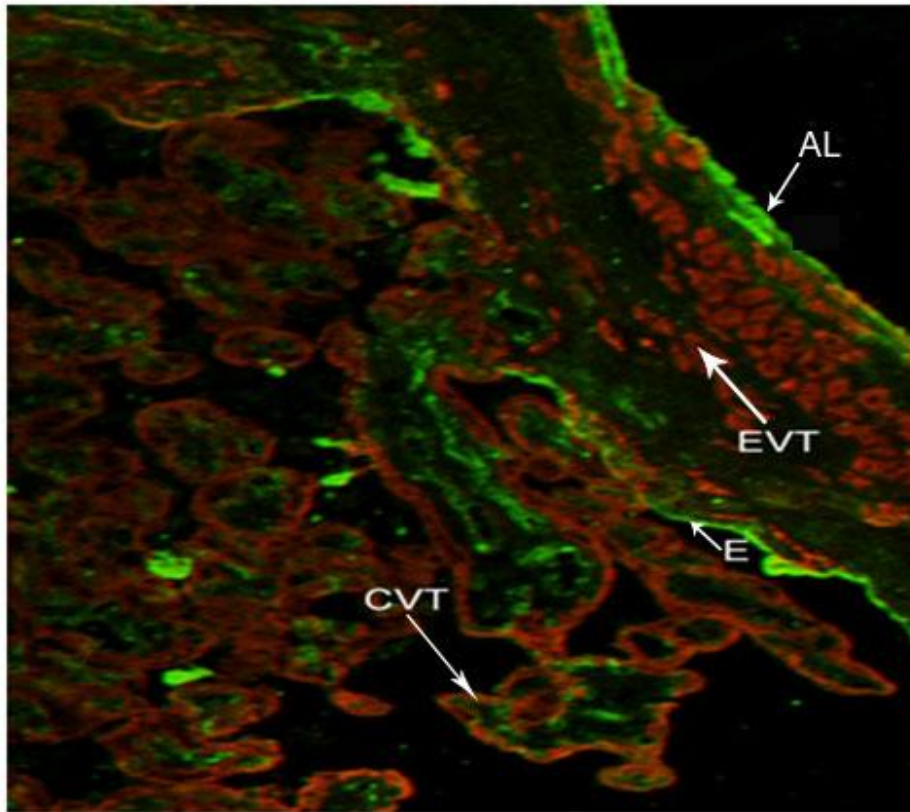
When equal amount of protein lysates from the chorionic villi and basal plate tissues were loaded from healthy and pre-eclamptic tissues, similar bands were obtained at the same molecular weight.



**Figure 3.28**

Immunoblot analysis of healthy chorionic villous trophoblast (CVTh) and Pre-eclamptic chorionic villous trophoblast (CVTp) proteins using monoclonal anti-keratin 19 (K19).

### 3.4.1 Dual immunofluorescence labelling technique of trophoblastic cells and endothelial cells

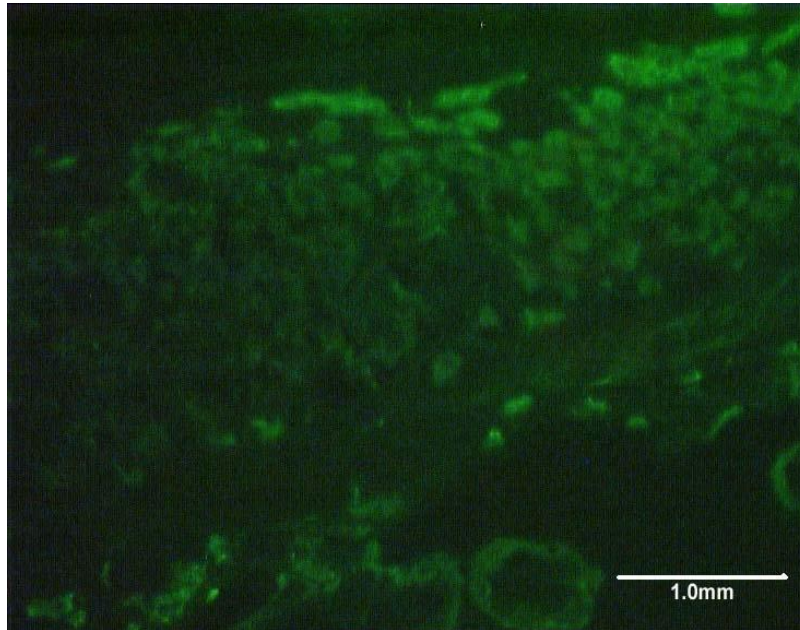


**Figure 3.29**

Dual immunostained term placental basal plate tissue. Trophoblast stained with CY3-conjugated sheep anti-mouse (RED) (1: 500) against keratin 18 antibody (1:1000) and endothelium labeled with FITC –conjugated goat anti-rabbit IgG(GREEN) (1: 100) against von-Willebrand factor (1: 400). EVT and CVT are extravillous and chorionic villous trophoblast respectively and basal plate lining cells E. The abscission layer (AL) is labelled with anti-von Willebrand immunofluorescence and hence shows endothelial characteristics.

The villous core which is lined by endothelium is immunoreactive for endothelial cell marker (green) whereas the CVT and EVT which are trophoblastic are reactive to trophoblast marker (Red). The basal plate lining cells (E) separating the intervillous space and the basal plate are interrupted at some points by keratin18 labeling (Red) supporting the observation by (Byrne *et al.*, 1998, 2001) that this layer is a mosaic comprising endothelium and trophoblast.

### 3.5 LASER CAPTURE MICRODISSECTION RESULTS

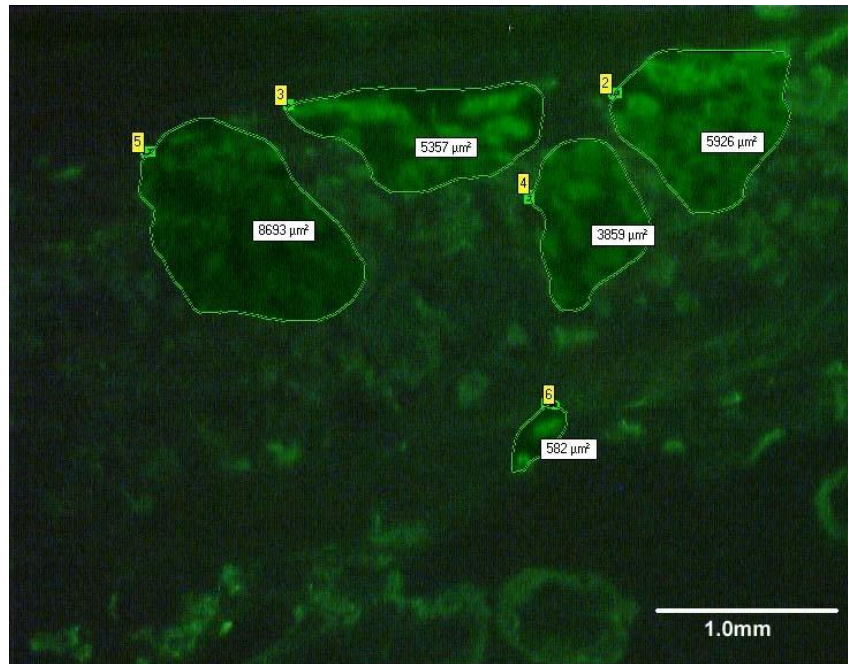


**Figure 3.30**

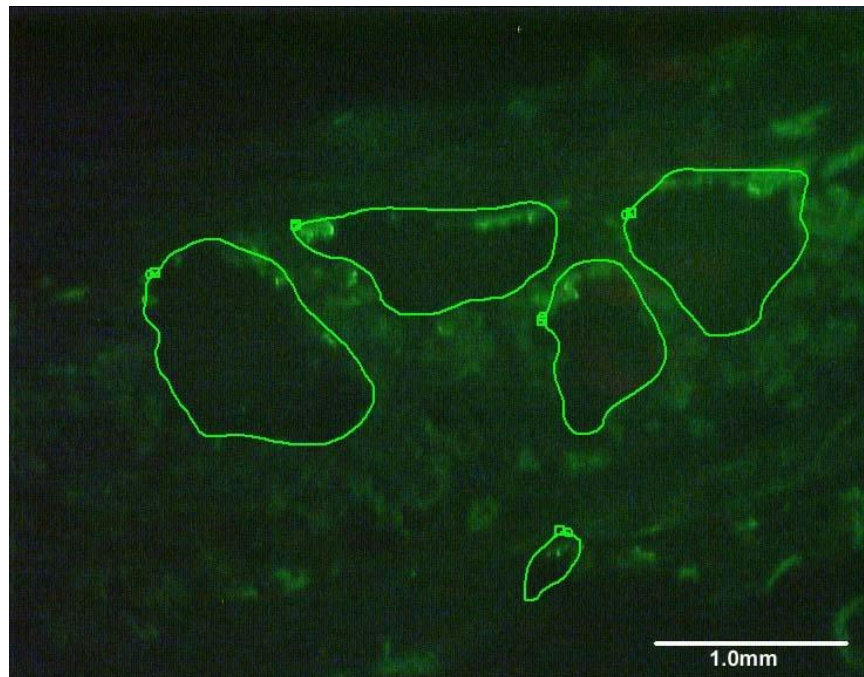
Term human placental basal plate tissue immunostained with FITC-labeled keratin 18 antibody before laser microdissection.

The villous and extravillous trophoblast cells are stained green whilst the villous core and intervillous space are not.

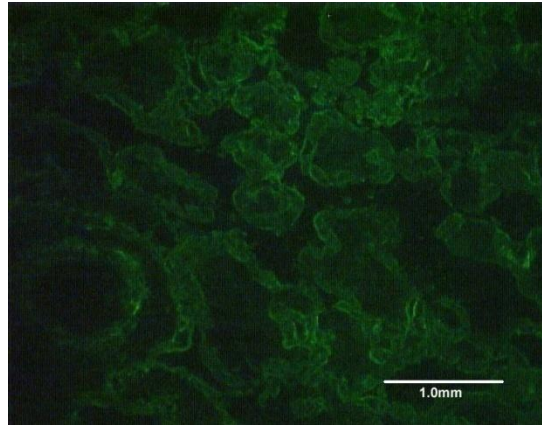





**Figure 3.31A** EVTs selected for laser microdissection circumscribed.



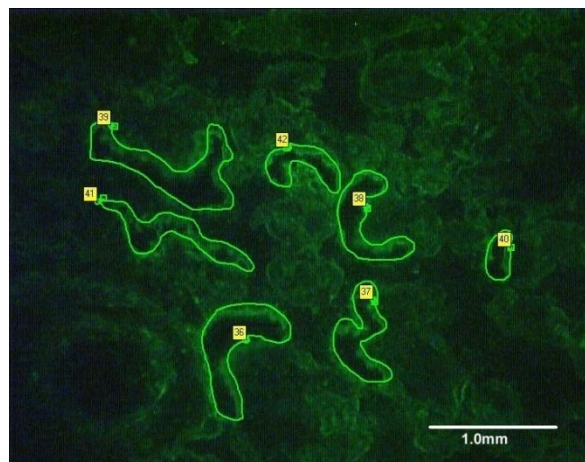
**Figure 3.31B**  
See empty spaces left behind after laser capture of EVTs.  
The cells were collected into a cap automatically.



**Figure 3.32A**  
Chorionic villous trophoblast of term human placenta immunostained with FITC-conjugated keratin 18 one step antibody.




**Figure 3.32B**  
Area of CVT selected for laser microdissection labelled (36-42).



**Figure 3.32C.** CVTs captured into cap. See the empty spaces



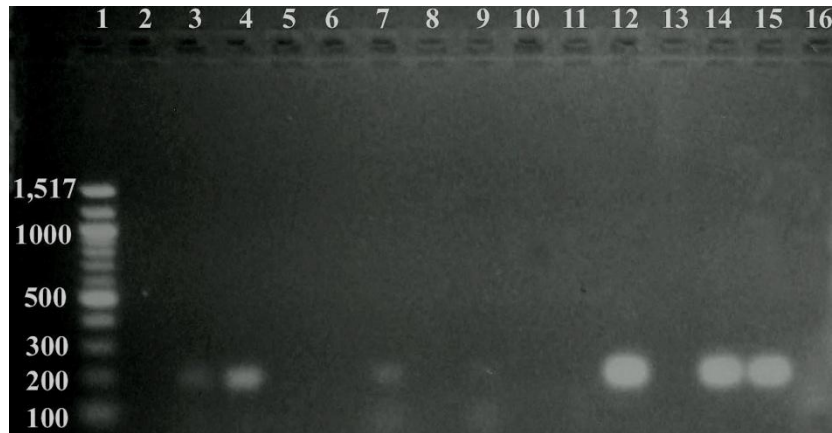


**Figure 3.33A**  
Empty cap before laser microdissection

**Figure 3.33B**  
Cap with some cells collected after laser  
microdissection

### 3.5.1 Agarose gel of PCR products

2% Agarose gel of PCR products of laser captured and manually dissected human placental basal plate samples.



**Figure 3.34**

Refer back to methods, Page 83

Lane 1 = Marker

Lane 2 = CVTho

Lane 3 = CVThi

Lane 4 = CVTpi

Lane 5 = CVTpo

Lane 6 = EVTho

Lane 7 = EVThi

Lane 8 = EVTpo

Lane 9 = EVTpi

Lane 10 = -ve (PCR water)

Lane 11 = Amo

Lane 12 = Ami (Amnion)

Lane 13 = CVTmdo

Lane 14 = CVTmdi

Lane 15 = BPmdi

Lane 16 = BPmdo

The inner primer sets (i) of lanes 3 and 4 and lanes 7 and 9 from laser microdissected samples compared with lanes 12, 14 and 15 which were manually dissected show differences in K7 gene expression by trophoblastic cells depending on how the cells were obtained. It appears the inner primer sets were more sensitive than the outer primer sets (o) except lane 9 which was less sensitive compared with lane 7.

## **4.0 CHAPTER FOUR: GENERAL DISCUSSIONS**

### **4.1 Confocal Laser Scanning Microscopy**

One of the most important findings of this study is the identification of the specific molecular species of keratins that are differentially expressed in the chorionic villous trophoblast and in the extravillous trophoblast of term placental basal plate tissues.

These keratins were K5, K7, K8, K18 and K19. This has improved our knowledge over that gained from previous experiments which had used an anti-pan-cytokeratin mixture of antibodies consisting of keratins 4, 5, 6, 8, 10, 13 and 18. The mixture showed a similar overall intensity and implied a similar differential expression but this could not be ascribed to particular molecular species (Ockleford *et al.*, 2004).

A further benefit of the present study in comparison to the work of Ockleford *et al.* (2004) is that not all of the keratin members in the pan-cytokeratin mixture were expressed in the trophoblast at term (those undetectable using individual molecule detection methods were 4, 6, 10 and 13).

Further it has been shown here that keratin 7 and keratin 19 which were not part of the ‘cocktail’ of antibodies in the pan-cytokeratin group were found to be individually expressed in the villous and in the extravillous trophoblast at term. As stated above, K4, K6, K10, and K13 among the pan-cytokeratin group were not expressed in the basal plate at term. This was notwithstanding the ability to detect expression of the self-same keratins using identical techniques in the amniotic epithelium. These observations constitute a powerful positive control in this study. Keratins 4, 6, 10, 13, 14, 17 were definitely not detected in the trophoblast at term and so could be used to distinguish trophoblast on one hand from amnion on the other (Table 2).

#### **4.1.2 Pattern of keratin expression in human placental basal plate tissue at term**

The pattern of expression of all the five keratins expressed in the basal plate tissue at term from the CLMS study were generally similar, where the keratins in the CVT were found to be dimmer or weakly expressed and very bright or upregulated in the EVT (figures 3.1 - 3.5). This pattern of expression of keratins was generally similar for the healthy placental basal plate tissue and that of the pre-eclamptics which is also consistent with the work of Ockleford *et al.* (2004) and Smith *et al.* (2004). See Figures 3.12 – 3.16, comparing the chorionic villi and the extravillous trophoblast in the basal plate at term.

The expression pattern of the chorionic villi is comparable with the pattern of expression in chorionic villi of human term placentae reported by Clark and Damjanov (1985) who used antibodies against K7, 8, 18, and 19. The present study further confirms the earlier suggestion that the trophoblast cells of the human placenta at term do express keratins typically found in many simple epithelia in the human body (Moll *et al.*, 1982; Tseng *et al.*, 1982; Osborn and Weber, 1983). This might imply that the trophoblast cells are truly simple epithelia in origin and therefore retain their keratins of origin even when they undergo differentiation.

It appears that the cyto- and the syncytio-trophoblast expression of keratins are similar, which probably suggests the differentiation of cytotrophoblastic cells into syncytiotrophoblast is not accompanied by changes in the keratin expression pattern.

It has been shown that K17 is expressed specifically in intramural cytotrophoblast in first trimester pregnancies (Pröll *et al.*, 1997) but K17 was not detectable in the basal plate at term in this study which indicates either a switching off of the gene towards the end of pregnancy or differences in the sensitivity of the detection methods used.

In this study, the general upregulation of all the keratins expressed in the EVT's as compared with villous trophoblast in both healthy and pre-eclamptic placental basal plate tissues at term is enigmatic.

A possible explanation could be that the EVT's in the basal plate appear to "stay put" at their final destination. Histologically, these cells according to Pröll *et al.*, (1997) are clearly different from "normal" villous cytotrophoblast in that they have lost their contact with the chorionic villus basal lamina and are surrounded by extracellular matrix. This may require upregulation of their strength giving cytoskeletal material which is mainly the keratins to remain anchored in their new environment, the basal plate. Since the basal plate also contains other cells such as decidual cells, maternal natural killer cells, fibroblast etc, it may be important for the EVT's to be cytoskeletally robust.

Not much is known about the keratin expression in the EVT's in other areas of the placenta apart from the basal plate tissue. In other words should we raise the question as to whether EVT's are homogeneous throughout the placenta and the fetal membranes in terms of their keratin expression at term?

#### **4.1.3 Banded pixel intensity of digital images**

When considering the results from chapter 3 section 3.2.1 (Figures 3.10A&B; 3.11A&B), the banding method used shows consistently a higher percentage pixel value in the EVT's compared with the CVT as demonstrated by K18 and K7 which are representatives of type I and type II keratins respectively but generally, the same pattern was seen in the remaining keratins expressed in the trophoblast at term in this study.

The statistical significant increase in the percentage median pixel intensity of keratin expression when quantified using the CLSM from the CVT to the EVT was found to be similar in both healthy and in the diseased state but interestingly was decreased or down regulated in the pre-eclampsics when the CVT's were compared (with the exception of

keratin 19 where significance reached a threshold) but there were no statistically significant differences between the EVTs in healthy and pre-eclamptic placentae at the CLSM level.

The digital image analysis using the COMOS software, gives a measure of regional protein expression but the degree to which immunofluorescence CLSM can be used as a quantitative method is debatable (Ockleford *et al.*, 2004). It indicates the pixel intensity of keratin immunofluorescence by highly immunofluorescent trophoblast cells in the basal plate tissue. The approach of Ockleford *et al.* (2004) was to pair data from within sections to maximise statistical power and to minimise the effects of inter-specimen variation. This was particularly thought to be attributable to variations between specimens and in specimen preparation. Instrumental errors in the accuracy and repeatability of the grey scale or fluorescence intensity accumulated over time using the CLSM were thought to be less significant. “Banding” the digital images is essentially a way of setting a high threshold to effectively baseline the highest values observed in the least immunofluorescent of the tissues to be compared. It also appears to eliminate the issue of background and non specific binding that may affect the mean brightness figures thereby obscuring differences in the keratin protein distribution over the CVT and EVT areas of a given basal plate tissue. In this study, comparisons were of paired percentage pixel intensity measurements of high intensity immunofluorescence obtained within the same section at the same observation session which Ockleford *et al.* (2004) believed to eliminate the majority of specimen preparation-related variability.

#### **4.1.4 Cluster and linear organisation of EVT's in basal plate**

Frequent observations in the basal plate tissue of both healthy and pre-eclamptic placentae are the clustering and scattering of EVT's and also the formation of linear arrangements of EVT's (Figure 3.17A & B). These phenomena are as yet unexplained and more work needs to be done in this area. The linear arrangements could possibly be a function of the origin of EVT's i.e. from an advancing epithelial front during the initial invasion process. Equally in the absence of relevant evidence the arrangement could reflect a residue of classical epithelial behaviour or the restriction of forward progress at a linear "barrier". The latter might indicate compositional differences in the matrix or reflect the activity of cells within the decidua.

#### **4.1.5 Significance of differential keratin expression in CVT's**

The immunofluorescence differences as measured by the percentage pixel intensity in all 5 keratins of the chorionic villous trophoblast comparing healthy and pre-eclamptics may be important because it may contribute to one of the mechanisms proposed to underlie the condition of pre-eclampsia.

This mechanism suggests that there is an increased deportation of trophoblast micro-particles into maternal circulation, which causes an increased vascular inflammatory reaction (Knight *et al.*, 1998; Johansen *et al.*, 1999; Sargent *et al.*, 2003; Goswami *et al.*, 2006) leading to raised blood pressure and proteinuria as a result of a body-wide endothelial cell damage in pre-eclamptic mothers.

The significant down regulation of CVT keratins in the pre-eclamptic placentae in this study may suggest that the trophoblast in the pre-eclamptics might be cytoskeletally weaker. It is therefore conceivable that any weakness in the major component of the epithelium as a

result of any external insult may lead to ‘flaking’ of the epithelial layer formed by the trophoblast. This may be so because it is known that keratin filaments are a key component of the apical syncytioskeleton maintaining the integrity of the term placental villous tree surface (Ockleford *et al.*, 1981a).

Trophoblast differentiation is reported to be accompanied and defined by alterations in the translation pattern for cytokeratin genes (Pröll *et al.*, 1997).

The exposure of the syncytiotrophoblast epithelium to maternal blood which occurs during perfusion of the placenta could be one source of mechanical stress to the epithelium. Another source of mechanical stress could be uterine contractions of labour and Braxton-Hicks contractions.

The selective weakening of the subset of trophoblast in contact with maternal blood, the chorionic villous trophoblast as compared with the extravillous trophoblast which is in contact with the maternal decidua is an observation that appears to support the proposed mechanism of trophoblast deportation of syncytiotrophoblast micro-particles which contain keratins. Therefore disruptions of the syncytioskeleton to a high degree as the case may be in pre-eclampsia may promote the “flaking” of the parts of the syncytium that are deported and thus might explain why the process is enhanced in the pre-eclampsia.

It may be interesting to examine the keratin content of deported trophoblast emboli in future studies. Already, there are reports of work done using keratin 18 and keratin 19 as potential serum markers in pre-eclampsia (Tempfer *et al.*, 2000; Hefler *et al.*, 2001).

It appears from this present study that keratin upregulation in the extravillous trophoblast and most importantly differential expression of the polypeptide in healthy and pre-eclampsia, may fit quite well into the continuum theory (Redman and Sargent 2000; 2005). The continuum theory of pre-eclampsia (Redman and Sargent, 2000) implies that any factor



that would increase the maternal systemic inflammatory response to pregnancy would predispose to pre-eclampsia. Some factors they suggested are a large placenta, an abnormal stimulus from a small placenta, or an excessive maternal sensitivity to such stimuli. The stimulus should originate in the placenta and must be released during all pregnancies and should be large when the placenta is oxidatively stressed.

This is because the phenomenon of keratin upregulation in the EVT<sub>s</sub> and more importantly differences in the expression of keratins in CVT<sub>s</sub> is not restricted to healthy placentae but also seen in pre-eclamptic placentae at term. On the basis of this work, it appears there may be a connection between keratin intermediate filament structures, oxidative stress and innate immune system that might be relevant to the pathology of pre-eclampsia.

#### **4.1.6 Oxidative stress, innate immunity and the signalling role of keratins**

Deficient spiral artery conversion in pre-eclampsia by the EVT<sub>s</sub> has been associated with reduced placental perfusion which could result in an increased risk of ischemia-reperfusion-insult to the placenta. This has been reported to be a powerful stimulus for the generation of oxidative stress (Hung *et al.*, 2001).

Burton *et al.* (2009b) recently reported that protein synthesis inhibition as a result of a stressed endoplasmic reticulum could result in reduced cell proliferation, leading to a small placental phenotype. A consequence of this would be the release of pro-inflammatory cytokines into the maternal circulation. The authors further reported the activation of signalling pathway for apoptosis in the trophoblast under the most severe stress condition.

Apoptosis is known to occur in epithelial cell lines deficient in K8 and K18 (Caulin *et al.*, 2000; Ku *et al.*, 2003) and there is also a report that K8 protects against Fas mediated apoptosis (Rasmussen *et al.*, 1999), may imply that less keratin as shown in this study for EVT<sub>s</sub> and CVT<sub>s</sub> in the pre-eclamptics might lead to increased apoptosis.

A possible link between oxidative stress and keratin expression is the damage that occurs when oxygen free radicals exceed the natural cellular protection by superoxide dismutase (SODs), catalase (CAT) and Glutathione peroxidase (GPX). Proteins, lipids and cellular DNA are known to be seriously damaged by such free-radical action (Jauniaux *et al.*, 2006). It is thus possible that the down regulation of keratins in both CVTs and the EVT's in the pre-eclamptic may be a result of oxidative stress early in pregnancy.

Damage to the intracellular keratin proteins could therefore result in shallow trophoblast invasion and placentation in pre-eclampsia (Zhou *et al.*, 1998; Caniggia *et al.*, 2000).

Oxidative stress has also been associated with the activation of the Lectin Complementary Pathway (LCP) reported to be mediated by Mannose Binding Lectin (MBL) found to bind to endothelial keratin 1 (Collard *et al.*, 2001). The authors found that oxidatively stressed endothelial HUVEC showed increased keratin mRNA expression which becomes a ligand for MBL to activate the LCP.

Although the pilot project to quantify K7 mRNA in this study did not yield repeatable results, data from the CLSM immunofluorescence and Immunogold study show an upregulation of keratins in the EVT's.

If we speculate that the endothelia in the placenta of the pre-eclamptic are oxidatively stressed then the keratins expressed may play a role in innate immunity. On the other hand, there is a report (Moffett and Hiby, 2007) of an important interaction between uterine natural killer (uNK) cells in the decidual stroma and invading cytotrophoblast by the interstitial pathway of invasion. According to these authors the invading cytotrophoblast are known to express a unique combination of Class 1 molecules of HLA-G, HLA-E and HLA-C. HLA-C is reported to be the dominant ligand for uNK cells. The receptors that bind to the different groups of HLA-C allotypes are called Killer cell immunoglobulin-like receptors (KIR) (Parham, 2004; Bashirova *et al.*, 2006). Maternal NK cells receptors variously bind to HLA-

C ligands on the fetal trophoblast cells both showing polymorphism with a defective combination in pre-eclampsia (Moffett and Hiby, 2007).

Reduced invasive potential of the EVTs is thought to result from a lower number of invading EVTs. The mechanisms are increased apoptosis and /or decreased proliferation (Huppertz *et al.*, 2009) as a result of a shift from low to high oxygen partial pressures during early development (Jauniaux *et al.*, 2003).

Gauster *et al.* (2009) proposed that invasion of the EVTs into the uteroplacental arteries may result from trophoblastic factors in combination with extrinsic factors of maternal uterus

I propose that one intrinsic factor, based on the results of this study, is the dysregulation of keratins in the trophoblast of pre-eclampsia. The possible signalling roles of keratins shown by various investigators appear to be important in this study.

The report that K8 is a plasminogen and tissue plasminogen activator receptor of endothelial cells, hepatocytes and breast cancer cells (Hembrough *et al.*, 1995; 1996) and also the demonstration that K18 is a binding site for thrombin-antithrombin complexes on the plasma membranes of rabbit hepatocytes (Wells *et al.*, 1997), together with the suggestion of the possible involvement of keratins in the transduction of signals and transport of nutrients in and out of the cell (Luna and Hitt, 1992) is attractive.

These findings may suggest a possible cross-talk between EVTs and other cells in the maternofetal interaction zone via the keratin intermediate filament proteins. Thus the downregulation of keratins in the trophoblastic cells of the pre-eclampsia demonstrated in this study may be one of the alterations that occur during signalling events of invasion alongside the down regulation or loss of E-Cadherin in the EVTs as they invade the maternal tissues (Damsky *et al.*, 1992).

Future work needs to be designed to look at keratin expression in placentae from first and second trimester stages of pregnancies in relation to the inflammatory response in pregnancy.

#### **4.1.7 Functional significance of upregulation of keratins in EVTs**

The functions of extravillous trophoblast are not fully understood. The fact that EVT do not form an even and complete layer in the basal plate renders a conventional epithelial function such as separation of two compartments or inter-compartment transport most unlikely. The possibilities that EVTs mediate invasion, attachment or signalling to promote the beneficial materno-fetal interaction become more likely.

The purpose of raised keratin content in EVT beyond that found in chorionic villus trophoblast in this present study remains enigmatic. This opens a new area of research for future investigation.

A possible explanation for the increased keratin expression in EVTs might be related to the finding that when simple epithelia which usually express K8 and K18 undergo malignant transformation K8 and K18 becomes strongly expressed (Markey *et al.*, 1991, Schaafsma *et al.*, 1990). Since EVTs are epithelial in origin, and EVTs do behave similarly to malignant cells in their invasive properties (Ohlsson, 1989), then it is logical that their expression of keratins may be stronger or upregulated for similar reasons. Ohlsson (1989) reported alterations in the expression of K8/K18 and related these to some functional modification of malignant phenotype, such as invasive capacity (Markey *et al.*, 1991). In a related experiment with mouse L-cells it was found that the invasive ability of the cells increased when the cells expressed K18 and K8 (Chu *et al.*, 1993). It has been reported also that the invasive front of mucosal squamous cell carcinomas show increased expression of K8 and K18 (Schaafsma *et al.*, 1993).

Other probable explanations of the increased keratin expression in the cytoplasm of EVT's might be for fluid impermeability, reinforcement of the basal plate mechanical integrity coupled with polarised extracellular matrix secretion. Whatever the function may be, it appears to persist until parturition. K8 and K18 have been reported to be the earliest keratins to be expressed in pre-implantation embryos (Jackson *et al.*, 1980), it is likely the upregulation of K8, 18, 7, 19 and 5 in the EVT's may play a role along-side other factors, in the invasiveness of EVT's in the basal plate tissue and these keratins perhaps have a different function in the villous trophoblast, a view that has been proposed also by Mulhauser *et al.* (1995).

It is shown here that the materno-fetal architecture resulting from an impaired invasion of the EVT's in the basal plate tissue in the pre-eclampsia is associated with a reduction in the anti-keratin immunofluorescence of keratins 5, 7, 8, 18 and 19 and supported by the reduced immunogold labelling of K18 and K7.

#### **4.2.0 DISCUSSION OF THE IMMUNO-ELECTRON MICROSCOPY STUDY**

Immunogold labelling was used as an independent quantification approach to the observation made using the CLSM.

The technique requires a fine optimisation of antigen preservation and tissue fixation for normal EM work. A similar differential gold labelling was seen in the CVT and EVT of both healthy and pre-eclamptic placentae, where keratin intermediate filament bundles in the CVT were less heavily labelled compared with the keratin filaments in the EVT but relatively lower counts were obtained when both CVT and EVT gold counts were compared with the pre-eclampsics (Table 8, Figure 3.23 and Table 9, Figure 3.24). Although with a smaller placental sample, the statistical significance levels obtained using immunogold labelling techniques place a further emphasis on the differential expression of keratins in the CVT compared with the EVT and more interestingly the highly statistical significant differences between the healthy CVT and the pre-eclamptic CVT.

This probably strengthens the proposed suggestion of weaker “syncytio-skeleton” (Ockleford *et al.*, 2004) in the pre-eclampsics. Although there were no statistical significant differences measureable between the EVTs of healthy and pre-eclamptic basal plate tissues at the CLSM level, experiments using K18 and K7 at the EM level showed that there appears to be a difference in the EVTs . There was a significant detectable down-regulation of keratins in the EVTs of pre-eclamptic placental basal plate tissue. It is hard to understand the reason for this significant difference since relatively fewer placental basal plate tissues were used (N= 4) for the EM work compared with (N = 40) for the CLSM and the smaller volumes of tissue studied in the EM. Further work needs to be done to interpret this observation. The labelling; a technically difficult method to achieve and of low efficiency, was however highly selective and the background counts were low (see Figures 3.20 – 3.22). This may have been important.

### 4.3 SPECIFIC KERATINS

K7, K8, K18, as well as K19 are typical keratins also found in simple epithelia (Moll *et al.*, 1982). K7 has been reported to be relatively trophoblast specific in first trimester tissues (Haigh *et al.*, 1999). Hence the expression of these keratins in the basal plate tissue at term is not surprising.

The finding of K5 in the trophoblast is remarkable, considering that K5 is usually absent in simple epithelia but present in most stratified epithelia (Moll *et al.*, 1982).

Keratin 5 (type II) is usually co-expressed with K14 (type I) but the absence of the latter keratin polypeptide along-side its expression pair in the basal plate tissue at term is unexpected. There is increasing evidence however, that certain keratins can replace each others *in vivo*, at least in the absence of additional stress. This has been reported to include K4 in the cornea of K5<sup>-/-</sup> mice, K19 in K18<sup>-/-</sup> mice, K8 in embryonic epidermis of K5<sup>-/-</sup> mice (Lu *et al.*, 2005; 2006; Magin *et al.*, 1998) and *in vitro* data reported by Hatzfeld and Franke (1985); Yamada *et al.* (2002) confirm the above assertion which probably suggest that the absence of K14 in the basal plate tissue along-side K5 at term might be a replacement for another member of the type I family. Paramio *et al.* (1999) also reported that during terminal differentiation, keratinocytes switch off K14 and start K10 expression, whereas in response to hyper proliferative stimuli, K16 replaces K10. It has also been reported that type II keratins are almost always expressed before their type I partners in differentiating epithelia (Stasiak *et al.*, 1989) and these could probably explain why K14 was undetected in the basal plate tissue.

Pröll *et al.* (1997) demonstrated that K17 is expressed specifically in intramural cytotrophoblast in first trimester pregnancies but K17 was not expressed in EVT's in the basal plate at term in this study which probably means there is a "switching off" of the gene at some time before the end of pregnancy.

The trophoblast is not initially at least a single layer of cells (simple) epithelium but rather it is a hybrid between simple and complex that becomes more simple as pregnancy progresses and the cytotrophoblast cells contact a smaller fraction of the basal lamina. The chorionic villous epithelium, as mentioned in the introduction, has not been adequately catered for in the conventional histological classification of epithelia.

#### **4.4 KERATINS AND THE EXTRACELLULAR MATRIX**

Some previous studies have pointed out that epithelial cell-extracellular matrix (ECM) interactions, as well as the composition of the ECM and the different amount of its various components, can have a specific influence in determining differentiated keratin expression (Mackey *et al.*, 1990; Kolega *et al.*, 1989; Kurpakus *et al.*, 1992).

Kurpakus *et al.*, (1992) demonstrated using an explants system, that the epithelial cells from bovine conjunctiva which expresses only traces of K3 *in situ*, when maintained on an intact extracellular matrix substrate derived from the cornea, the conjunctiva expressed K12 as determined by immunofluorescence. The cornea is reported to express only the keratin pair K3 and K12 (Schermer *et al.*, 1986).

On the other hand, Kurpakus and his co-workers demonstrated that when conjunctival cells were maintained on corneal substrate lacking basement membrane (BM), the cells failed to express K12. The study according to Kurpakus *et al.* (1992) supports the notion that corneal BM can induce morphogenetic changes in the overlying epithelial cells which results in the production of certain corneal specific keratin proteins.

This implies that certain exogenous factors or signals could regulate the up-or down regulation of specific keratin genes and their polypeptide products.

It has been shown that epithelial cells methylation of keratin genes may be involved in the control of transcription (Semat *et al.*, 1986; Oshima *et al.*, 1988).



Mackay *et al.* (1990) suggested a possibility that specific growth factors associated with the BM may play a role in the control of keratin gene expression in epithelial cells. A study demonstrated that K19 specifically binds to laminin (Dobashi *et al.*, 2000), suggesting an interaction between keratin and the extracellular matrix, confirming the report by Luna and Hitt (1992) of the possible involvement of keratins in the transduction of signals and transport of nutrients from inside to the outside of the cell

It is therefore possible that the EVTs in the basal plate tissue could be signalled to upregulate their keratin intermediate filament through some type of transduction of signals from the ECM. The elucidation of mechanisms involved in such hypothetical inductions requires further study. Structural components of the BM such as laminin, nidogen, or collagen IV may be important. The role of the ECM receptors for integrin family which are located along the region of epithelial cells which are in direct contact with the BM may be important.

A possible link between integrin switching of the extravillous trophoblast as they migrate deep into the basal plate (Aplin *et al.*, 1999, 2009) and keratin upregulation in the EVTs can be compared with the work of Ockleford *et al.* (1997) showing that keratins form the intracellular anchoring rootlets that comprise the sites of attachment of integrin containing hemidesmosomes in the amnion.

## 4.5 DISCUSSION ON IMMUNOBLOTS

The reactivity of the monoclonal antibodies used were verified using western blotting. SDS-PAGE separates and estimates the molecular weights of proteins with reference to standardised protein size marker. Although not all the keratin antibodies were tested in this way, those tested were within the known range of the molecular weights of keratin proteins 40-68KD. A limitation to this method was that a positive control from human adult tissue such as the skin, pancreas, trachea and cornea for example, would have been the ideal but the amnion was selected owing to its embryonic association with the placenta and its ready availability.

The immunoblots (Figure 3.26, 3.27 and 3.28) for K4 and K13 antibodies suggest that K4 and K13 are expressed in the amnion but not in the CVT and basal plate tissues whereas K5, K7, K18 and K19 are expressed in all three tissue samples at term. This confirms in part the observations made at the confocal fluorescent microscopy level (table 2).

K19 expression in both healthy and Pre-eclamptic CVT lysates were similar at approximately 40KD molecular weight. This suggests that there were no difference in expression of K19 in both healthy and in pre-eclamptic tissues. Similarly, K18 antibody expression in the healthy CVT (CVTh) and pre-eclamptic CVT (CVTp) shows similar banding at approximately the same molecular weight positions in the samples from the basal plate tissue as from the healthy (BPh) and pre-eclamptic (BPp).

#### **4.6 DISCUSSION OF LASER MICRODISSECTION EXPERIMENT**

This study was undertaken as a pilot project intended to show the possibility of cutting out cells of interest in the basal plate tissue using a laser microscope. It was anticipated that it would allow at the molecular level, quantitation of the differential expression of keratins in CVTs and EVTs in healthy and pre-eclamptic placental basal plate tissues at term. These could then be compared with results of the fluorescent and immuno-electron microscopic approaches. It was possible to cut out extravillous trophoblast cells and CVT cells from a basal plate tissue as shown in figures 3.31-3.32. Since the control of protein expression is known to be influenced at the level of mRNA, it was hoped to quantify the relative expression of keratin 7 messenger RNA in the CVT and EVT cells in both healthy and pre-eclamptic placental basal plate tissues.

Preliminary data obtained from K7 nested PCR quantification from repeated experiments yielded no repeatable results. However, PCR products used for Agarose gel electrophoresis appear to show that K7 message could potentially be ascertained using larger samples. This implied template RNA samples from the manually dissected basal plate tissue (BPmd), (CVTmd) and amnion were larger (20mg) than the laser microdissected cell-samples (500cells approximately) and the former appeared to show distinct bands with the inner primer sets with the 2% Agarose gel electrophoresis (Figure 3.34). Since the outer primer set PCR products were used as a template for the inner primer set, the inner primer sets of oligonucleotides were more sensitively detected. They targeted sequence nucleotides within the outer primer sets. The small number of samples obtained by laser microdissection could not be compared with samples obtained by manual microdissection. This is reflected in the low detection in the laser capture samples (see lanes 3 and 4; lanes 7 and 9; lanes 12, 14 and 15 of figure 3.34). DNA contamination and enzymatic inhibitions were probable sources of errors that might occur

during the quantification step as the Corbett Rotor-Gene equipment was highly sensitive. Future detailed study of this kind may be very useful especially targeting extravillous trophoblast cells by in situ hybridization and laser capturing these cells in healthy and pre-eclamptic placentae could unequivocally reveal clearer differences in the keratin content of these specialised cells.

#### **4.7 LIMITATIONS OF STUDY**

A minor hypothetical limitation of the western blot experiment is the use of amnion epithelium as a positive control in place of adult tissues that are known to express specific keratins such as the human eye lens which expresses K3 and K12 and human skin which expresses K1, K5, K10 and K14. It might have been important to have pre-defined positive and negative controls to ensure there was no antibody cross reactivity in the absence of the differences becoming apparent in the course of the amnion experiments. This is important because the undetected keratin species in all the sample tissues CVT, EVT and Amnion e.g. K1, K2, K3 (Table 2) will not be unequivocally confirmed without antigen blocking experiments.

In the immunogold experiment, the relatively small sample size might have affected the statistical significance which was greater than that for the more extensive CLSM work. This was counter-intuitive but not necessarily a limit as it could also have resulted from lower inherent backgrounds of the method.

The relatively small numbers of the laser microdissected CVT and EVT samples has set limits to the statistical power of the mRNA quantification. Owing to lack of time the bands obtained in the Agarose gel were not sequenced to determine the identity of the protein. This would have been a helpful adjunct to the data presented.

In the indirect immunofluorescent microscopy, the use of K7, 8, 18 and 19 antibody on one group of placenta samples and K5 antibody on a different group of placentas were not ideal.

It did not allow for direct comparison of all keratin antibodies expressed in the basal plate at term on tissues from the same individuals. Nevertheless these data are a significant advance over what has been available up to the present and are generally well-controlled using isotype antibodies.

#### **4.8 FUTURE WORK**

To determine whether EVTs are homogeneous throughout the placenta and in the fetal membranes with respect to their keratin expression would be a worthwhile development of the project. At present the finding of EVTs in the basal plate with similar morphology to chorion leave trophoblast and to EVTs in the chorionic plate is intriguing. Whether keratin expression patterns are identical or different it will enhance the knowledge of trophoblast differentiation and suggest where strata of the placental disc are equivalent to strata in the amniochorion.

Investigation of the clustering and pseudo-epithelial linear organisation of EVTs in the basal plate would allow us to define whether EVT clusters are related positionally to the site of anchoring villus attachment or to particular depths of the basal plate (placental bed).

In view of the fact that circulating keratin has been suggested as a trigger for endothelial pathology in pre-eclampsia it would be helpful to define the keratins present in deported trophoblast emboli in maternal blood and to determine which native keratins are to be found in maternal peripheral blood to help define their origin more accurately.

The upregulation of keratin expression in both healthy and pre-eclamptic EVTs described here is still an enigma. The reasons for this might be investigated by gene knock-down experiments in cultures and co-cultures. The developmental sequence of the events that have led to upregulation of EVT keratin are also currently undefined and will require longitudinal study of tissue from all three trimesters to clarify. Resolving whether the regulation is an implantation or placentation related event or an “age-related” change confined to near term

will restrict the likely functions and indicate to what physiological circumstances the upregulation is linked.

This study although did not look at the chronology of keratin expression over the course of placental development (i.e. in first and second trimesters tissues); such investigations could inform the current understanding of the pathophysiological significance of keratin downregulation.

Following the molecular expression description and development of techniques given here, an interesting opportunity has arisen to apply laser microdissection and *in situ* hybridization with RT-PCR to specifically target EVTs in the basal plate tissue so as to determine which keratins are upregulated and down-regulated in healthy and pre-eclamptic mothers.

## **5.0 CONCLUSION**

In conclusion, the analysis of keratins to the single molecule level has shown that the observations previously made using anti-pancytokeratin antibody, are reflected in the patterned expression of several but not all keratins tested. It is amongst the five molecules K5, 7, 8, 18, and 19 within the chorionic villi, that the overall changes in the levels of keratins are to be accounted for. Keratin abundance could correlate with excess trophoblast deportation described previously in pre-eclamptic pregnancy.

**6.0****Appendix 1**

TABLE 1: List of keratin antibodies used in the study.

Anti-keratin	source	clone	Primary dilution	Secondary dilution	Isotype
K1	<sup>1</sup> Santa Cruz Biotechnology, Inc	LHK1, # sc-53249	1:50	1:100	IgG <sub>2a</sub>
K2	Santa Cruz Biotechnology, Inc	AE3, # sc-57004	1:20	1:100	IgG <sub>1</sub>
K3	Santa Cruz Biotechnology, Inc	Q-14, # sc-49181	1:50	1: 100	IgG
K4	<sup>2</sup> Sigma-Aldrich, Missouri, USA	6B10, # C5176	1: 20	1:50	IgG <sub>1</sub>
K5	Santa Cruz Biotechnology, Inc	RCK103, # sc-32721	1: 50	1: 100	IgG <sub>1</sub>
K6	<sup>3</sup> Serotec	LHK6B, MCA 1869	1: 20	1: 50	IgG <sub>2a</sub>
K7	Sigma-Aldrich, Missouri, USA	LDS-68, #C6417	1: 150	1: 50	IgG <sub>1</sub>
K8	Sigma-Aldrich, Missouri, USA	M20, #C5301	1: 400	1: 50	IgG <sub>1</sub>
K9	<sup>4</sup> American Research products, Inc. <sup>TM</sup>	Ks 9.70 & Ks 9.216	1: 20	1: 100	IgG <sub>1</sub> + IgG <sub>3</sub>
K10	Serotec	MCA 1871T, #070905	1: 40	1: 50	
K12	Santa Cruz Biotechnology, Inc	L-20, sc-17099	1: 50	1: 100	IgG
K13	Sigma-Aldrich, Missouri, USA	KS-1A3, #C0791	1: 20	1: 50	IgG <sub>1</sub>
K14	Sigma-Aldrich, Missouri, USA	CKB1, #C8791	1: 50	1: 50	IgM
K15	Santa Cruz Biotechnology, Inc	LHK15, sc-47697	1: 50	1: 100	IgG
K16	Santa Cruz Biotechnology, Inc	LL025, sc-53255	1: 50	1: 100	IgG
K17	Sigma-Aldrich, Missouri, USA	CK-E3, #C9179	1: 50	1: 50	IgG <sub>2b</sub>
K18	Sigma-Aldrich, Missouri, USA	CY-90, #F4772	1: 1000	1: 60	IgG <sub>1</sub>

K19	Sigma-Aldrich, Missouri, USA	A53-B/A2	1: 50	1: 60	IgG <sub>2a</sub>
K20	Santa CruzBiotechnology,Inc	Q2,#8c-58730	1: 20	1: 100	IgG1
K23	Santa CruzBiotechnology,Inc	14L-3,sc- 100927	1:50	1:50	IgG <sub>2a</sub>

1 = Santa Cruz Biotechnology, Inc. Santa Cruz, CA. 95060 USA

2 = Sigma-Aldrich, p.o.box 14508, St. Louis, MO.USA

3 = SeroTec, MorphoSys UK Ltd, Kidlington, OX5 1GE, UK.

4 = American Research products, Inc. Belmont, MA. 02478 USA.



## Appendix 2a

### DATA FOR HEALTHY AND PRE-ECLAMPTIC MOTHERS IN THE STUDY (using K7,8,18,19 Antibodies)

#### HEALTHY

CODE	GA/Wks	Bwt./Kg	Highest systolic/diastolic BP(mmHg)	Urine Protein/random or 24hour in g/l	Maternal Age
PC1	40	2.62	131/81	2+	19yrs
PC2	40	3.6	136/76	1+	30yrs
PC3	41	3.22	111/74	0	27yrs
PC8	31	1.98	130/68	0	21yrs
PC7	41	4.138	142/90	2+	35yrs
PC9	39+4	2.849	120/65	0	19yrs
PC10	37+5	2.721	130/80	0	22yrs
PC11	40	3.48	120/78	0	28yrs
PC13	40	3.162	126/76	0	30yrs
PC12	39	3.218	112/68	0	24yrs
<b>means±1SD</b>	<b>38.92±2.94</b>	<b>3.10±0.59</b>	<b>125.8±10.03/75.6±7.40</b>		<b>25.5±5.36yrs</b>
<b>Range</b>	<b>(31-40)</b>	<b>(1.98-4.14)</b>	<b>(111-142/65-90)</b>		<b>(19yrs-35yrs)</b>

## Appendix2b

### PRE-ECLAMPTIC

CODE	GA/Wks	Bwt./Kg	Highest systolic/diastolic BP(mmHg)	Urine Protein/random or 24hour in g/l	Maternal Age
PE15	37+5	2.72	155/104	3+/0.55g/l	31yrs
PE10	40+2	3.033	151/109	3+	28yrs
PE4	39+1	3.146	145/101	2+	27yrs
PE19	37+4	2.636	157/100	1.80g/24h 3+	23yrs
PE20	38+3	2.863	163/103	1.93g/l 5.19g/l	22yrs
PE14	37+1	2.409	155/106	0.61g/24h	30yrs
PE8	39+5	3.4	146/105	3+	17yrs
PE7	38+4	3.09	149/100	3+/1.72g/l	31yrs
PE17	38+5	2.976	151/93	3+	30yrs
PE23	39+3	4.11	154/96	3+ 1.76g/L	26yrs
<b>means±1SD</b>	<b>38.65±1.00</b>	<b>3.04±0.47</b>	<b>152.6±5.37/101.4±4.76</b>		<b>26.5±4.60yrs</b>
<b>Range</b>	<b>(37+1- 40+2)</b>	<b>(2.41-4.11)</b>	<b>(145-163/93-109)</b>		<b>(17yrs-31yrs)</b>

## Appendix2c

### DATA FOR HEALTHY AND PRE-ECLAMPTIC MOTHERS IN THE STUDY(using K5 Antibody)

#### HEALTHY

CODE	GA/Wks	Bwt./Kg	Highest systolic/diastolic BP(mmHg)	Urine Protein/random or 24hour in g/l	Maternal Age
PC001	38+6	3.04	124/71	1+	37yrs
PC002	40+6	2.92	120/75	0	23yrs
PC003	41+3	3.28	121/81	0	33yrs
PC005	39+6	3.22	138/85	0	20yrs
PC006	39+6	2.98	117/73	0	28yrs
PC007	39+3	4.34	126/85	0	26yrs
PC008	41+1	2.9	117/70	0	21yrs
PC009	40+2	3.16	122/72	0	18yrs
PC010	40+4	3.34	122/64	NAD	27yrs
PC011	41+1	4.06	135/78	1+	23yrs
<b>means±1SD</b>	<b>40.34±0.84</b>	<b>3.32±0.49</b>	<b>124.2±7.08/75.4±6.81</b>		<b>25.6±5.92yrs</b>
Range	(38+6-41+3)	(2.9-4.34)	(117-138/64-85)		(18-37)

## Appendix2d

## PRE-ECLAMPTIC

CODE	GA/Wks	Bwt./Kg	Highest systolic/diastolic BP(mmHg)	Urine Protein/random or 24hour in g/l	Maternal Age
PE001	38+1	2.976	151/108	1+/0.6g/l	30yrs
PE002	40	3.9	147/101	1+ 0.19/l or 13mg/mmol	29yrs
PE003	38+3	2.863	163/103	1.93g/l 5.19g/l	22yrs
PE004	38+1	3.72	149/99	2+	29yrs
PE005	38+1	2.72	164/100	2+	21yrs
PE006	40+6	3.66	143/100	2+	21yrs
PE007	39+1	2.99	163/108	2+	23yrs
PE008	39+4	4.24	164/116	3+	31yrs
PE009	38+1	2.976	151/108	1+/0.6g/l	30yrs
PE010	39+3	4.11	154/96	3+ 1.76g/L	26yrs
<b>means±1SD</b>	<b>39.00±0.96</b>	<b>3.41±0.57</b>	<b>154.9±7.94/103.9±5.59</b>		<b>26.2±4.08yrs</b>
Range	(38+1-40+6)	(2.72-4.24)	(143-164/96-116)		(21yrs-31yrs)

### Appendix 3

#### SDS PAGE COMPOSITION

	Dense Acrylamide (20%)	Light Acrylamide (5%)	Stacking Acrylamide (4%)
Resolving Buffer	2.5ml	2.5ml	
Stacking Buffer			2.5ml
40% Acrylamide	5ml	1.25ml	1ml
Water	2.25ml	6.25ml	6.50ml
Glycerol	0.25ml		
TEMED	10µl	10µl	12µl
APS	32 µl	32µl	40 µl

## **Appendix 4**

### **Immunohistochemistry**

Fixative

1:1 acetone-methanol v/v

Washing solution / diluent for antibodies

20% FCS = (4ml of TBS-T with 1ml FCS)

(TBS-T: 20mM Tris, 150mM NaCl with 0.1% v/v Tween-20, pH 7.6)

### **Immunogold labelling for Electron microscopy**

Fixative

4% w/v paraformaldehyde

0.1% v/v glutaraldehyde in PBS

pH = 7.4

4% paraformaldehyde means 4g (solid) depolymerised in hot, slightly alkaline water. The glutaraldehyde comes as a 25% stock solution, so for each 100ml of fix, you need 400 microlitres.

### **Blocking solution**

PBSGAT (PBS solution with Goat serum, Bovine Serum Albumin and Tween-20 solution)

5% v/v non-immune Goat serum, 1% w/v BSA and 1% Tween-20 in PBS

1% toluidine blue was made from 1g solid dissolved in 2% w/v borax (disodium tetraborate).

## **SDS - PAGE**

### **Running Buffer**

6g Tris base,

28.8g glycine,

2g sodium dodecyl sulphate made up to 2 litres with distilled water.

### **Acrylamide stock solution**

40g Acrylamide

1.067g N,N'-methyl bis-acrylamide make up to 100ml with distilled water.

### **Staining the gel**

10% v/v acetic acid,

45% v/v of industrial methylated spirit (IMS),

0.08% w/v Coomassie brilliant blue R-250

### **Destaining solution**

(10% acetic acid in deionised water with 5% IMS made up to 1 litre)

### **Semi-Dry transfer Buffer**

[3g of Tris-Base, 14.25g of Glycine and 10% methanol made up to 1 litre]

### **Blocking Solution ("Milk")**

5g of Marvel (non-fat milk powder)

9g glucose

1g bovine serum albumen (BSA)

5ml glycerol

95ml of TBS-T.

## **LASER CAPTURE MICRODISSECTION**

### **10x TAE** (Tris-acetate-EthyleneDiamineTetraAcetic acid)

242g Tris base

57.1 ml glacial Acetic acid

37.2g Na<sub>2</sub>EDTA.2H<sub>2</sub>O made up to 1L with distilled water

**1x TAE** = 100ml of **10x TAE** solution made up to 1L with distilled water

3g Agarose powder

pH = 8.0

DNA loading buffer (6x)



## Appendix 5a

### K5 Percentage Pixel Immunofluorescence Intensity Measurements

Obs. No	CVTp	EVTP	CVTh	EVTh
1	0	1.87	0.19	1.58
2	0.15	3.77	0.08	1.51
3	0	3.56	0.15	0.09
4	0.11	7.07	0	1.62
5	0.55	2.91	0.03	3.01
6	0	2.21	0	1.7
7	0	6.35	0	2.31
8	0	0.93	0	2.96
9	0.08	10.91	0	2.1
10	0.11	6.97	0.25	0.88
11	0.02	1	0	2.8
12	0.09	5.4	0	0.56
13	0.05	1.97	0	0.4
14	0.03	8.24	0.01	0.61
15	0.03	0.36	0	0.17
16	0	3.38	0	1.26
17	0	0.28	0.15	1.34
18	0	1.18	0	0.91
19	0.03	1.3	0.01	0.59
20	0.3	1.55	0	1.06
21	0.11	1.71	0	2.85
22	0.62	2.2	0.1	0.61
23	0.11	3.89	0.01	3.24
24	0.05	3.72	0	1.86
25	0.02	1.71	0	2.22
26	0.24	2.48	0.11	4.44
27	0.09	0.51	0.21	2.78
28	0.4	2.39	0	2.38
29	0.19	3.25	0	3.65
30	0.29	2.64	0.09	1.36
31	0.79	3.1	0.17	2.03
32	0.48	4.91	0	0.59
33	0.02	2.9	0	1.67
34	0	2.8	0	1
35	0.03	4.41	0.17	1.67
36	0.01	3.49	0	1.89
37	0.01	6.25	0.39	2.48
38	0	2.21	0.06	4.97

39	0.15	5.29	0.31	7.68
40	0.56	4.86	0.41	4.63
41	0	1.86	0.47	3.33
42	0.92	4.01	1.38	6.32
43	0.05	5.63	0.18	2.32
44	0.04	1.38	0.09	1.78
45	0.18	2.58	0.06	0.75
46	1.74	3.97	0	2.33
47	0.09	3.69	0	3.2
48	0	1.31	0.54	3.27
49	0	8.8	0.25	5.14
50	0	3.27	0.04	4.03
51	0.03	12.77	0.72	9.43
52	0	1.66	1.13	9.22
53	0.01	6.23	0.12	10.29
54	0	1.35	0.02	8.89
55	0.08	5.41	0.08	3.83
56	0.02	4.68	0.15	2.75
57	0	3.09	0.23	1.61
58	1.36	2.71	0	2.33
59	1.16	2.78	0.28	4.08
60	0.21	0.92	0.21	2.38
61	0	0.05	0	1.37
62	0.06	0.89	0.02	1.94
63	0	0.33	0.04	1.57
64	0	0.15	0.14	1.75
65	0.2	2.15	0.02	0.81
66	0	0.74	0.35	7.64
67	0	0.99	0.86	4.66
68	0.3	2.82	0.05	4.9
69	0.1	0.67	0.52	6.07
70	0	0.78	0.05	6.21
71	0.12	0.98	0	4.32
72	0.08	0.32	0.04	4.42
73	0.05	0.06	0	9.85
74	0.03	0.43	0.09	2.71
75	0.16	2.16	0.29	6.53
76	0.08	1.85	0	6.95
77	0.2	3.34	0.2	1.81
78	0.2	6.65	0.14	5.22
79	0.17	2.18	0.45	4.2
80	0.05	3.05	0.07	6.91

81	0.52	10.19	0.7	2.76
82	0	7.39	0.06	0.92
83	0.01	8.5	0.03	2.76
84	0	7.1	0.05	4.73
85	0	3.32	0.05	2.71
86	0.04	1.74	0.25	2.67
87	0	1.36	0.66	4.49
88	0	1.3	0.14	5.55
89	0	3.42	0.44	0.23
90	0	4.59	1.18	5.67
91	0	7.44	0.3	1.99
92	0	6.47	0.31	5.76
93	0.02	5.22	0.38	2.51
94	0.06	6.26	0.44	5.64
95	0.08	4.74	3.02	5.06
96	0.19	5.21	0.17	8.55
97	0.15	7.73	0.07	3.85
98	0.32	4.05	0.02	2.91
99	0.51	1.17	0.25	3.32
100	0.32	3.65	0.5	3.39
101	0.15	2.35	0.15	3.09
102	0.24	3.83	1.76	6.49
103	0.03	3.08	2.43	2.72
104	0.28	4.56	1.05	5.85
105	0.3	4.38	0.48	2.64
106	0.46	3.84	0.01	4.3
107	0.15	7.91	0.27	1.83
108	0.1	2.33	0.44	3.13
109	0.24	0.72	0.16	0.94
110	0.16	2.76	1.84	4.84
111	0.5	1.73	0.31	3.22
112	0.15	3.03	0	2.31
113			3.53	9.01
114			0.91	5.41
115			0.05	1.8
116			1.84	2.47
117			0.8	7.62
118			0.65	3.73
119			0.08	8.44
120			0.06	2.21
121			0.47	3.61
122			0.12	4.95

123			0.09	4.23
124			0.19	3.13
125			0.39	6.71
126			0.23	5.67
127			0.37	5
128			0.28	2.54
129			0.18	1.89
130			1.02	4.06
131			0.14	4.09
132			0	4.76
133			0	7.07
134			0.59	6.29
135			2.44	3.59
136			0.67	4.57
137			0.03	2.22
138			0.15	5.91
139			0.31	2.52
140			0.19	0.68
141			0	1.94
142			0.02	3.7
143			0.35	4.12
144			0.97	6.01
145			0.3	0.36
146			0.15	0.33
147			0.53	1.53
148			0.02	2.57
149			0.07	1.43
150			0.07	0.35

## Appendix 5b

### K7 Percentage Pixel Immunofluorescence Intensity Measurements

Obs. No.	CVTp	EVTp	CVTh	EVTh
1	0.79	8.86	0.45	5.18
2	0.02	2.98	0.12	3.59
3	0.56	7.76	0.12	4.29
4	0.55	12.1	0.01	9.45
5	0	1.71	0.07	7.89
6	0	7.14	0.13	11.5
7	0.01	3.08	0.88	12.29
8	0.07	5.37	0.61	8.57
9	0	6.24	0.5	6.76
10	0.03	7.85	0.8	9.39
11	0.04	6.95	1.54	3.81
12	0.21	9.85	1.99	0.91
13	0	1.24	0.02	2.42
14	0.01	0.71	0	1.23
15	0.15	0.99	0.03	4.79
16	0	1.41	0	4.51
17	0.03	5.76	0.97	5.07
18	0.37	7.91	0.6	17.97
19	0.05	1.13	0.06	3.55
20	0.02	1.57	1.25	7.76
21	0.03	3.37	0.23	5.77
22	0.1	1.91	0.89	6.57
23	0	0.32	1.69	0.94
24	0	1.84	1.84	2.84
25	0.06	1.01	0	5.74
26	0.02	0.56	0.03	10.04
27	0.12	4.26	0.09	9.23
28	0.04	7.48	0.12	11.9
29	0.12	1.38	3.41	12.23
30	2.01	6.85	5.6	13.64
31	1.78	7.47	0.17	9.98
32	4.1	7.82	0.42	16
33	0.03	5.91	0.08	0.83
34	0.16	8.21	0.41	0.78
35	2.58	9.01	2.66	10.92
36	1.56	12.98	0.81	3.11
37	0.24	6.66	1.13	3.24
38	0	12.01	0.68	1.88

39	0.2	9.88	0.07	1.8
40	0.14	15.94	0.7	4.43
41	0.01	3.24	0.35	6.39
42	0.05	2.69	0.34	2.03
43	0.18	8.68	0.8	5.9
44	0.96	2.47	1.18	4.85
45	2.4	8.42	0	3.2
46	1.66	3.35	3.5	2.63
47	0.3	3.68	1.04	4.79
48	0.05	4.6	1.46	7.64
49	0.02	5.03	0.29	10.6
50	0.04	7.56	0.27	7.37
51	0	2.02	0.01	3.85
52	0	3.32	0	7.91
53	0.12	4.94	0.12	8.73
54	0.5	1.03	0	13.38
55	0	5.08	0.16	4.58
56	0.01	5.83	0.45	5.12
57	0.19	2.11	0.94	4.06
58	0	1.34	0.01	4.63
59	0.01	1.43	0	3.89
60	0.01	2.12	0.27	1.72
61	0.15	1.88	0	4.44
62	0.46	2.98	0.12	1.41
63	0.23	4.45	0	4.94
64	0	2.52	0.32	4.45
65	0	3.18	0.05	0.44
66	0.28	4.18	0.64	6.17
67	0.06	9.77	0.63	5.82
68	0.14	0.73	1.77	9.47
69	0	2.2	0.82	5.5
70	0.02	5	1.03	10.98
71	0	2.03	0	0.53
72	0.05	3.49	0	0.27
73	0	2.61	0.02	2.1
74	0.02	0.03	0.09	1.83
75	0.04	0.59	0	0.93
76	0.14	0.31	0.56	1.94
77	0.24	0.48	0.02	1.19
78	0.18	0.24	0.02	1.94
79	0	1.92	0	3.03
80	0	1.46	0	1.66

81	0	2.07	0	0.41
82	0.03	0.26	0	0.55
83	0	0.69	0	0.01
84	0.04	1.28	0	0.17
85	0	1.27	0.06	0.2
86	0.02	3.53	0.08	1.62
87	0.01	2.04	0.05	0.91
88	0.01	0.91	0	0.73
89	0	0.6	0	3.27
90	0.06	1.66	0	0.68
91	0.3	2.93	0.62	2.54
92	0	1.83	0.28	0.87
93	0.02	0.77	0.44	2.17
94	0	1	1.11	0.74
95	0	0.91	0.52	3.36

## Appendix 5c

### K8 Percentage Pixel Immunofluorescence Intensity Measurements

Obs. No	CVTp	EVTp	CVTh	EVTh
1	3.16	5.12	0.43	1.75
2	3.4	3.55	0.18	0.25
3	7.22	5.08	0.03	0.89
4	1.08	3.32	0	0.51
5	0.52	3.22	0.18	0.47
6	2.29	5.1	0.84	0.82
7	1.97	9.94	0	0.17
8	1.2	5.26	0	0.47
9	0	3.76	0	0.67
10	0	5.91	0	0.64
11	0.05	0.97	0.45	2.71
12	0.06	0.74	0.91	1.51
13	0.03	1.69	0.08	1.68
14	0.43	2.89	0.21	2.05
15	0	0.79	1.03	2.83
16	0	2.67	0.88	2.99
17	0	1.42	0.19	4
18	0	1.13	0.13	0.94
19	0.03	0.59	0.18	0.82
20	0	1.18	0.04	0.58
21	0	1.16	0.32	3.7
22	0.21	2.03	0.42	3.01
23	0	3.68	0	0.61
24	0.2	1.15	0.19	5.27
25	2.4	6.48	0.28	9.98
26	2.41	6.94	0.76	41.4
27	2.12	8.35	0.7	9.23
28	0.61	6.36	2.7	2.38
29	0.19	5.96	0.29	2.33
30	0.09	1.46	3.46	3.97
31	0.14	2.82	3.71	5.59
32	0.1	1.74	4.96	3.64
33	0.01	3.34	1.02	4.5
34	0.54	2.62	0.54	3.75
35	1.09	2.8	0.06	3.17
36	1.06	8.6	0.3	3.7
37	0.15	5.28	8.05	8.86
38	0.1	4.07	8.96	4.92



39	0.15	1.46	1.01	4.96
40	0.47	4.59	0.41	5.85
41	0	1.83	0.55	1.94
42	0	1.19	0.01	7.69
43	0	1.82	0.05	2.85
44	0	2.45	0.32	2.67
45	0	1.32	0.88	11.41
46	0.14	7.71	0.38	1.55
47	0.58	1.36	1.12	4.08
48	0.17	11.4	0.33	1.02
49	0.02	2.79	0.59	1.93
50	0.03	2.25	1.26	3.23
51	0.09	4.52	0.18	5.09
52	0.56	3.21	0.03	3.33
53	0.02	1.23	0	0.36
54	0.08	1.57	0.29	3.74
55	0.01	1.09	0.58	4.71
56	0	2.59	1.98	0.71
57	0.02	2.51	0.95	3.22
58	0.17	7.51	0.05	5.97
59	0.05	1.87	0	3.86
60	0.14	1.68	0	5.85
61	0.09	2.81	0.87	7.94
62	0.06	2.68	5.36	9.99
63	0.02	3.94	3.26	10.68
64	0.61	1.71	2.23	11.34
65	1.01	1.56	2.05	13.75
66	0	3.26	1.66	3.29
67	0	0.68	0	0.54
68	0.02	0.18	0	0.67
69	0	1.17	0.03	0.39
70	0	0.18	0	0.74
71	0	0.3	0.02	1.42
72	0	1.86	0	0.94
73	0.06	0.06	0.01	0.35
74	0	1.39	0	1
75	0	0.14	0	1.4
76	0	0.24	0	0.85
77	0.03	0.26	0	1.05
78	0.05	0.42	0.07	1.35
79	0.04	0.59	0	1.29
80	0	0.89	0.4	3.88

81	0	0.92	0.59	2.88
82	0.02	0.75	0.01	5.7
83	0	0.41	0.21	7.61
84	0.03	0.36	0.35	8.8
85	0.02	0.68	0.45	3.78
86	0.01	1.99	0.55	2.76
87	0	0.29	1.34	5.21
88	0.01	2.23	0.44	4.86
89	0.03	1.34	0.98	2.83

## Appendix 5d

### K18 Percentage Pixel Immunofluorescence Intensity Measurements

Obs. No.	CVTp	EVTp	CVTh	EVTh
1	1.47	4.88	2.17	4.33
2	0.88	2.22	5.05	2.59
3	0.04	1.42	0.23	0.88
4	0.01	2.03	0.1	2.16
5	0.02	1.87	0.84	1.06
6	0.09	2.41	0.13	0.16
7	0.02	0.12	0.09	0.6
8	1.09	1.63	3.05	1.92
9	0	0.94	0.05	4.27
10	0.41	1.29	1.13	1.64
11	0	1.27	0.36	0.7
12	0.2	0.03	0.58	0.66
13	0	2.88	0.73	1.51
14	0	2.49	0.84	3.2
15	0.04	4.62	1.84	11.06
16	0.02	5.56	1.91	2.69
17	0.01	0.59	0.75	2.69
18	0.09	0.53	0.76	3.65
19	0	2.01	0	2.29
20	0	1.83	0.02	1.95
21	0	1.81	0.5	3.24
22	0.01	6.94	1.77	2.4
23	1.27	4.65	4.65	18.2
24	1.03	2.73	1.73	8.63
25	1.13	8.36	0.1	1.79
26	0.35	5.8	0.06	1.25
27	1.35	4.15	5.98	6.73
28	0.06	0.77	7.18	14.66
29	0.02	7.22	1.02	12.39
30	0.15	3.05	0.03	19.41
31	0.36	5.95	0.68	5.13
32	0.21	3.65	3.55	4.7
33	0	0.46	1.12	1.61
34	0	10.22	4.63	3.05
35	0.41	7.79	1.17	5.08
36	0	3.36	3.21	4.88
37	0.26	7.52	0.32	3.71
38	0.16	2.29	0.41	5.58

39	0.07	2.66	0.38	3.58
40	0	1.86	3.39	2.62
41	0.27	4.29	0.4	2.92
42	0.15	3.03	0.66	8.23
43	0.09	0.29	0.39	0.76
44	0	0.48	0	0.89
45	0.01	0.69	0.76	3.94
46	0.06	0.46	0.64	2.18
47	0.05	4.12	0.03	3.82
48	0.33	1.57	0	0.99
49	0.15	0.64	0.01	2.16
50	0.01	0.88	0.34	0.61
51	0	1.71	0.06	3.33
52	0.03	0	0.12	3.05
53	0.09	2.94	0.5	4.52
54	0.21	3.49	0.86	9.62
55	0.79	11.08	0.96	7.42
56	0.02	2.27	0.59	4.13
57	0.03	2.87	0.47	6.13
58	0.87	2	0.77	1.7
59	0.13	5.13	0.81	5.2
60	0.07	9.89	0.24	2.32
61	0.03	11.66	0.3	2.29
62	0.21	1.62	0.29	2.9
63	0.21	5.88	0.31	1.21
64	0.23	5.15	6.85	8.29
65	0.21	2.19	0.41	6.99
66	0.08	2	0.12	2.58
67	0	2.53	0.09	1.78
68	0.23	2.65	0.03	2.95
69	0.18	0.11	0.08	0.58
70	0.05	1.92	0.32	0.44
71	0.3	1	1.13	7.63
72	0.01	0.37	2.67	4.12
73	0.01	2.04	0.18	3.51
74	0.11	0.38	0.75	7.77
75	0.14	0.95	0.74	7.74
76	0.01	0.03	1.05	2.62
77	0.65	0.87	0.09	3.04
78	0.08	0.08	0.86	1.54
79	0.14	2.03	0.44	0.71
80	0.04	3.38	1.78	1.36

81	0.03	3.61	0.12	0.14
82	0	4.82	0.45	0.11
83	0.41	1.66	0.18	1.19
84	0.42	1.45	0.41	3.17
85	2.44	2.11	0.26	1.09

## Appendix 5e

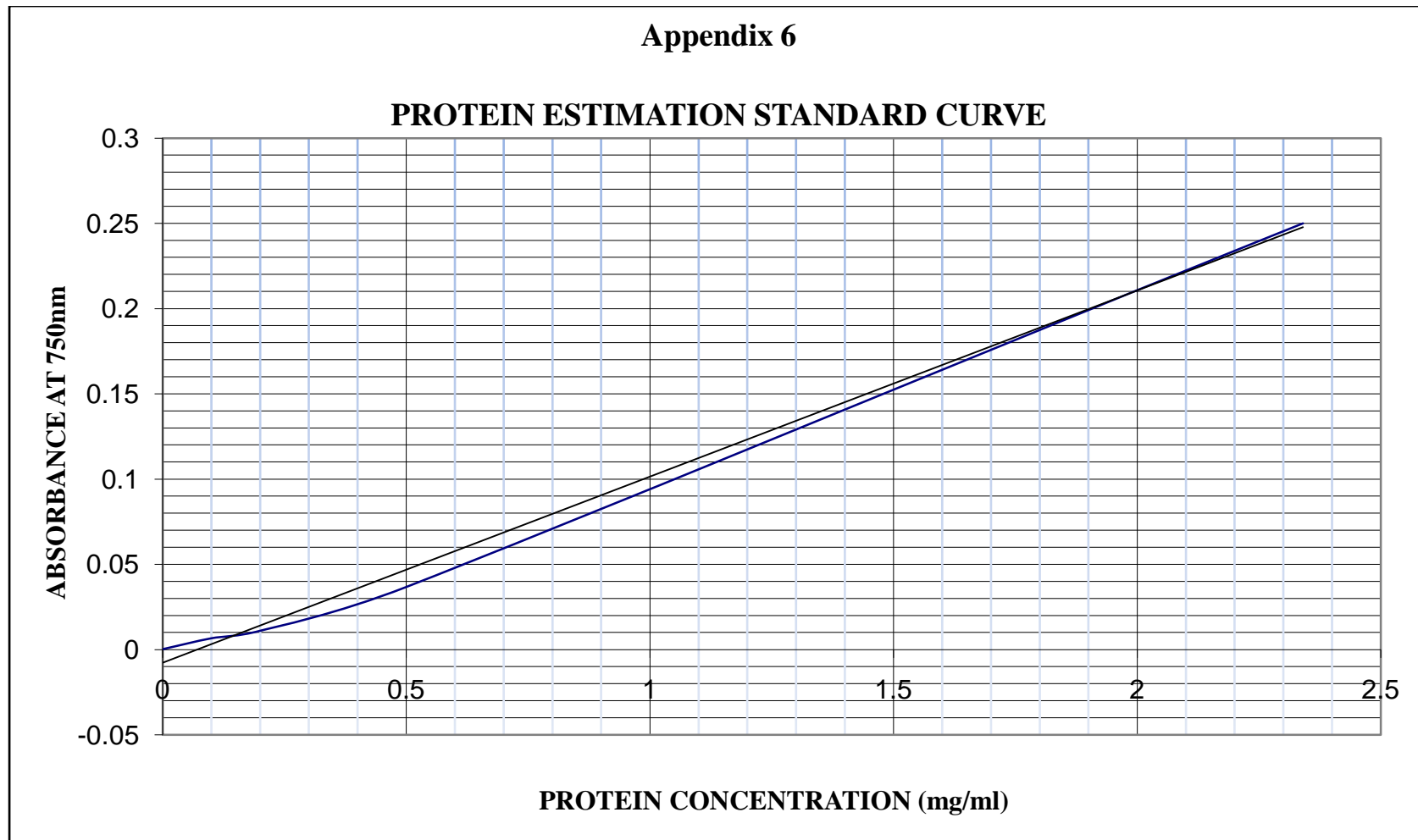
### K19 Percentage Pixel Immunofluorescence Intensity Measurements

Obs.No.	CVTp	EVTp	CVTh	EVTh
1	0.02	0.09	0	0.75
2	0.01	0.03	0	0.87
3	0	0.15	0	0.77
4	0	0.14	0	0.34
5	0.11	0.31	0.05	0.29
6	0.02	1.45	0.08	0.26
7	0.2	0.32	0.14	0.23
8	0.33	0.18	0	0.37
9	0	0.5	0	0.5
10	0	0.34	0.09	0.68
11	0.02	0.79	0.09	2.34
12	0.05	0.45	0	2.99
13	0.27	1.36	0.05	2.93
14	0	0.43	0.45	7.86
15	0	1.02	0.17	1.71
16	0	2.59	0.48	1.34
17	0	1.19	0.44	1.96
18	0.02	0.88	1.38	2.11
19	0.01	0.48	0	0.91
20	0.06	0.11	0	0.6
21	0.05	1.32	0.04	7.88
22	0.01	3.4	0.04	4.81
23	0.01	0.34	0.05	6.03
24	0	0.92	0	5.21
25	0.01	1.8	0.31	5.15
26	0.01	0.71	0.05	2.83
27	0.15	0.52	0	1.11
28	1.97	0.41	0.09	8.91
29	0.14	1.73	0	6.45
30	0.05	4.12	0	4.55
31	0.04	4.22	0	3.19
32	0.01	4.6	0	0.68
33	0	6.84	0.02	1.09
34	0.27	5.22	0.09	2.88
35	0.44	9.26	0	1.86
36	0.24	6.12	0.05	2.32
37	0.25	5.72	0	1.94
38	0.01	4.55	0.15	1.35

39	0.01	1.21	0.07	1.3
40	0	1.7	0.02	2.73
41	0	0.35	0.22	0.97
42	0	1.29	0	1.64
43	0.03	0.4	0.01	1.34
44	0	5.24	0	5.39
45	0	5.56	0	4.77
46	0	2.83	0	1.06
47	0	5.68	0.03	1.07
48	0	3.44	0.01	0.34
49	0.03	0.38	0.01	0.94
50	0.01	0.27	0	0
51	0.01	0.01	0.64	0.44
52	0.07	0.05	0.01	0.13
53	0.05	0.06	0.06	0.4
54	0	0.02	0	0.2
55	0	0.11	0	0.02
56	0	0.42	0.02	1.32
57	0	0.2	0.09	0.55
58	0.18	3.17	0.36	0.88
59	0.08	2.06	0.76	0.24
60	0	7.03	0.7	19.5
61	0	0.12	0.01	0.11
62	0	0.04	0	0.1
63	0	0.03	0.05	0.58
64	0	0.13	0.01	1.71
65	0.03	0.01	0.03	0.21
66	0	0	0.09	0.28
67	0.07	0.15	0.03	0.48
68	0.21	0.53	0.06	0.26
69	0.21	0.22	0.05	0.25
70	0.01	0.15	0.12	0.53
71	0.15	1.03	0.11	0.53
72	0.06	1.28	0.07	1.15
73	0.02	0.43	0.32	0.27
74	0.02	2.85	0.51	3.11
75	0.03	1.06	0.54	7.29
76	0	0.57	0.04	0.47
77	0.08	0.99	0.06	2.56
78	0.06	1.05	0.09	0.89
79	0	0.62	0.11	0.5
80	0	1.02	0.04	1.34

81	0.13	1.01	0.33	2.11
82	0.06	0.44	0	0.3
83	0	0.07	0.25	0.24





Legend: Blue line is based on measurements and black line is the fitted straight line.

## 7.0 BIBLIOGRAPHY

**Aaserud, M., Lewin, S., Paulsen, E.J., Dahlgren, A.T., Trommald, M., Duley, L., Zwarenstein, M. and Oxman, A.D.,** 2005. Translating research into policy and practice in developing countries: a case study of magnesium sulphate for pre-eclampsia. *BMC Health Serv. Res.*, **5**, 68.

**ACOG Committee on Obstetric Practice:** 2002. ACOG practice bulletin-Diagnosis and Management of pre-eclampsia and Eclampsia. *Int.Gynaecol Obstet*, **77**, 67-75.

**Aladjem, S.,** 1968. An index of syncytial growth in normal and complicated pregnancies. *Am.J.Obstet Gynecol*, **101**, 704-708.

**Alberts, B., Johnson, A., Lewis, J., Raff, M., Roberts, K and Walter, P,** 2002. *Molecular Biology of The Cell*. 4th ed. New York, USA: Garland Science.

**Aly, A.S., Khandelwal, M., Zhao, J., Mehmet, A.H., Sammel, M.D. and Parry, S.,** 2004. Neutrophils are stimulated by syncytiotrophoblast microvillous membranes to generate superoxide radicals in women with preeclampsia. *American Journal of Obstetrics and Gynecology*, **190**, 252-258.

**Aplin, J.D.,** 1993. Expression of integrin alpha-6 beta-4 in human trophoblast and its loss from extravillous cells. *Placenta*, **14**, 203-215.

**Aplin, J.D.,** 1991. Implantation, trophoblast differentiation and haemochorial placentation: mechanistic evidence in vivo and in vitro. *J. Cell Sci.*, **99**, 681-692.

**Aplin, J.D., Haigh, T., Lacey, H., Chen, C.P. and Jones, C.J.,** 2000. Tissue interactions in the control of trophoblast invasion. *J Reprod Fertil Suppl.*, **55**, 57-64.

- Aplin, J.D., Haigh, T., Jones, C.J., Church, H.J. and Vicovac, L.,** 1999. Development of cytotrophoblast columns from explanted first-trimester human placental villi: role of fibronectin and integrin  $\alpha 5 \beta 1$ . *Biol.Reprod.*, **60**, 828-838.
- Aplin, J.D., Jones, C.J.P. and Harris, L.K.,** 2009. Adhesion Molecules in Human Trophoblast – A Review. I. Villous Trophoblast. *Placenta*, **30**, 293-298.
- Arechavaleta-velasco, F., Ma, Y., Zhang, J., McGrath, C.M. and Parry, S.,** 2006. Adeno-Associated Virus-2 (AAV-2) causes trophoblast dysfunction, and placental AAV-2 infection is associated with preeclampsia. *Am. J. Pathol.*, **168**, 1951-1959.
- Babawale, M.O., Mobberley, M.A., Ryder, T.A., Elder, M.G. and Sullivan, M.H.F.,** 2002. Ultrastructure of the early human fetomaternal interface co-cultured in vitro. Article. *Human Reproduction*, **17**, 1351-1357.
- Ball, E., Bulmer, J.N., Ayis, S., Lyall, S. and Robson, S.C.,** 2006. Late sporadic miscarriage is associated with abnormalities in spiral artery transformation and trophoblast invasion. *J. Pathol*, **208**, 535-542.
- Baribault, H., Price, J., Miyai, K. and Oshima, R.G.,** 1993. Mid-gestational lethality in mice lacking K8. *Gene Dev.*, **7**, 1191-1202.
- Barker, D.J.P., Bull, A.R., Osmond, C. and Simmonds, S.J.,** 1990. Fetal and placental size and risk of hypertension in adult life. *BMJ*, **301**, 259-262.
- Bashirova, A.A., Martin, M.P., McVicar, D.W. and Carrington, M.** 2006. The killer Immunoglobulin-like receptor gene cluster: tuning the genome for defense. *Annu Rev. Genomics Hum Genet*, **7**: 277-300.

- Bauer, M.K., Harding, J.E., Bassett, N.S., Breier, B.H., Oliver, M.H., Gallaher, B.H., Evans, P.C., Woodall, S.M., Gluckman, P.D.,** 1998. Fetal growth and placental function. *Mol Cell Endocrinol*, **140**, 115-120.
- Beck, A.J. and Beck, F.,** 1967. The origin of intra-arterial cells in the pregnant uterus of the macaque (*Macaca mulatta*). *Anat Rec.*, **158**, 111-113.
- Beilin, L.,** 1994. Aspirin and pre-eclampsia. *BMJ*, **308**, 1250-1251.
- Benirschke, K. and Kaufmann, P.,** 2000. *Pathology of the human placenta*. 4th ed. New York, USA: Springer.
- Benirschke, K., Kaufmann, P., and Baergen, R.,** 2006. *Pathology of the Human placenta*. 5TH ed. New York, USA: Springer.
- Benyo, D.F., Miles, T.M. and Conrad, K.P.,** 1997. Hypoxia stimulates cytokine production by villous explants from human placenta. *J.Clin Endocrinol Metab.*, **82**, 1582-1588.
- Bergstrom, S., Povey, G., Songane, F. and Ching, C.,** 1992. Seasonal incidence of eclampsia, its relationship to meteorological data in Mozambique. *J. Perinat Med*, **20**, 153-158.
- Bills, V.L., Varet, J., Millar, A., Harper, S.J., Soothill, P.W. and Bates, D.O.,** 2009. Failure to upregulate VEGF165b in maternal plasma is a first trimester predictive marker for pre-eclampsia. *Clinical science*, **116**, 265-272.
- Bissell, M.J., Hall, H.G. and Parry, G.,** 1982. How does the extracellular matrix direct gene expression? *Journal of Theoretical Biology*, **99**, 31-68.

- Blankenship, K. and King, B.F.**, 1993. Developmental changes in the cell columns and trophoblast shell of the macaque placenta: an immunohistochemical study localizing type IV collagen, laminin, fibronectin and cytokeratins. *Cell Tissue Res.*, **274**, 457-466.
- Blaschitz, A., Weiss, U., Dohr, G. and Desoye, G.**, 2000. Antibody reaction patterns in first trimester placenta: implications for trophoblast isolation and purity screening. *Placenta*, **21**, 733-741.
- Blumenberg, M., Connolly, D.M. and Freedberg, I.M.**, 1992. Regulation of keratin gene expression: The role of the nuclear receptors for Retinoic acid, Thyroid Hormone, and Vitamin D3. *J. Invest. Dermatol*, **98**, 42S-49S.
- Bonifas, J.M., Rothman, A.L. and Epstein, E.H.**, 1991. Epidermolysis bullosa simplex evidence in two families for keratin gene abnormalities. *Science*, **254**, 1202-1205.
- Bonner, R.F., Emmert-Buck, M., Cole, K., Potida, T., Chuaqui, R., Goldstain, S. and Liotta, L.A.**, 1997. Laser Capture Microdissection: Molecular Analysis of Tissue. *Science*, **278**, 1481-1483.
- Bornslaeger, E.A., Corcoran, C.M., Stappenbeck, T.S. and Green, K.J.**, 1996. Breaking the connection: displacement of the desmosomal plaque protein desmoplakin from cell-cell interfaces disrupts anchorage of intermediate filament bundles and alters intercellular junction assembly. *J. Cell Biol*, **134**, 985-1001.
- Borzychowski, A.M., Sargent, I.L. and Redman, C.W.**, 2006. Inflammation and pre-eclampsia. *Seminars in Fetal & Neonatal Medicine*, **11**, 309-316.
- Bosch, F.X., Leube, R.E., Achtstatter, T., Moll, R. and Franke, W.W.**, 1988. Expression of Simple epithelial type Cytokeratins in stratified epithelia as detected by immunolocalization and hybridization in Situ. *J. Cell Biol*, **106**, 1635-1648.

- Boulanger, C.M.**, 1999. Secondary endothelial dysfunction: hypertension and heart failure. *J. Moll cell cardiol*, **31**, 39-49.
- Bou-Resli, M.N., Al-Zaid, N.S. and Ibrahim, M.E.A.**, 1981. Full-term and prematurely ruptured fetal membranes. *Cell Tissue Res.*, **220**, 263-278.
- Bower, H.**, 1998. Studies reject aspirin for prevention of pre-eclampsia. *BMJ*, **316**, 881h.
- Boyd, J.D and Hamilton, W.J.**, 1970. *The Human Placenta*. Cambridge, UK.: W.Heffer and Sons.
- Boyd, P.A., Brown, R.A. and Stewart, W.J.**, 1980. Quantitative structural differences within the normal term human placenta: A pilot study. *Placenta*, **1**, 337-344.
- Bright, N.A. and Ockleford, C.D.**, 1995. Cytotrophoblast cells: a barrier to maternofetal transmission of passive immunity? *J Histochem Cytochem*, **9**, 933-944.
- Brosens, I., Robertson, W.B and Dixon, H.G.**, 1972. The role of the spiral arteries in the pathogenesis of preeclampsia. *Obstet Gynecol Annu.*, **1**, 177-191.
- Brosens, I., Robertson, W.B and Dixon, H.G.**, 1967. The physiological response of the vessels of the placental bed to normal pregnancy. *J. Path. Bact.*, **93**, 569-579.
- Brosens, J.J., Pijnenborg, R. and Brosens, I.A.**, 2002. The myometrial junctional zone spiral arteries in normal and abnormal pregnancies: a review of the literature. *Am J.Obstet. Gynecol.*, **187**, 1416-1423.
- Bulmer, J.N. and Johnson, P.M.**, 1985. Antigen expression by trophoblast populations in the human placenta and their immunobiological relevance. *Placenta*, **6**, 127-140.
- Burrows, T.D., King, A. and Loke, Y.W.**, 1994. Expression of adhesion molecules by endovascular trophoblast and decidual endothelial cells- implication for vascular invasion during placentation. *Placenta*, **15**, 21-33.

**Burton, G.J. and Jauniaux, E.,** 1995. Sonographic, stereological and Doppler flow velocimetric assessments of placental maturity. *Br. J Obstet Gynaecol*, **102**, 818-825.

**Burton, G.J. and Jones, C.J.P.,** 2009a. Syncytial knots, sprouts, apoptosis, and trophoblast deportation from the human placenta. *Taiwan J Obstet Gynecol.*, **48**, 28-37.

**Burton, G.J., Yung, H.-., Cindrova-Davies, T. and Charnock-Jones, D.S.,** 2009b. Placental Endoplasmic Reticulum Stress and Oxidative Stress in the Pathophysiology of Unexplained Intrauterine Growth Restriction and Early Onset Preeclampsia. *Placenta*, **30**, 43-48.

**Burton, G.J., Hempstock, J. and Jauniaux, E.,** 2003. Oxygen, early embryonic metabolism and free radical-mediated embryopathies. *Reproductive BioMedicine Online*, **6**, 84-96.

**Burton, G.J., Hempstock, J. and Jauniaux, E.,** 2001. Nutrition of the Human Fetus during the First Trimester—A Review. *Placenta*, **22**, S70-S77.

**Burton, G.J., Jauniaux, E. and Watson, A.L.,** 1999. Maternal arterial connections to the placental intervillous space during the first trimester of human pregnancy: The Boyd Collection revisited. *Am. J.Obstet. Gynecol.*, **181**, 718-724.

**Byrne, S., Cheent, A., Dimond, J., Fisher, G and Ockleford, C.D,** 2001. Immunocytochemical Localisation of Caveolin-1 in human term extraembryonic membranes: implications for the complexity of the materno-fatal junction. *Placenta*, **22**, 499-510.

- Byrne, S., Cheent, A., Dimond, J., Fisher, G and Ockleford, C.D,** 1998. Immunocytochemical localisation of Caveolin-1 in human term extraembryonic membranes using confocal laser scanning microscopy. *J. Anat.*, **193**, 312-313.
- Byrne, S., Ahenkorah, J., Hottor, B., Lockwood, C. and Ockleford, C.D.,** 2007. Immuno-electron microscopic localisation of caveolin 1 in human placenta. *Immunobiology*, **212**, 39-46.
- Caniggia, I., Winter, J., Lye, S.J. and Post, M.,** 2000. Oxygen and placental development during the first trimester: implications for the pathophysiology of pre-eclampsia. *Placenta*, **21 Suppl A**, S25-S30.
- Carter, J.E.,** 1964. Morphologic evidence from syncytial formation from the cytotrophoblastic cells. *J. Obstet Gynecol*, **23**, 647-656.
- Caulin, C., Ware, C.F., Magin, T.M. and Oshima, R.G.,** 2000. Keratin-dependent, epithelial resistance to tumor necrosis factor-induced apoptosis. *J. Cell Biol*, **149**, 17-22.
- Chan, S., Kachilele, S., McCab, C.J., Tannahill, L.A., Boelaert, K., Gittoes, N.J., Visser, T.J., Franklyn, J.A. and Kilby, M.D.,** 2002. Early expression of thyroid hormone deiodinases and receptors in human fetal cerebral cortex. *Developmental Brain Research*, **138**, 109-116.
- Chan, S., Murray, P.G., Franklyn, J.A., McCabe, C.J. and Kilby, M.D.,** 2004. The use of laser capture microdissection (LCM) and quantitative polymerase chain reaction to define thyroid hormone receptor expression in human 'term' placenta. *Placenta*, **25**, 758-762.



- Chen, Q., Stone, P., Ching, L-M. and Chamley, L.,** 2009. A role for interleukin-6 in spreading endothelial cell activation after phagocytosis of necrotic trophoblastic material: implications for the pathogenesis of pre-eclampsia. *Journal of pathology*, **217**, 122-130.
- Chen, Q., Stone, P.R., McCowan, L.M. and Chamley, L.W.,** 2006. Phagocytosis of necrotic but not apoptotic trophoblasts induces endothelial cell activation. *Hypertension*, **47**, 116-121.
- Chu, Y-W., Runyan, R.B., Oshima, R.G. and Hendrix, M.J.C.,** 1993. Expression of complete keratin filaments in mouse L cells augments cell migration and invasion. *Proc. Natl. Acad. Sci. USA*, **90**, 4261-4265.
- Chu, S., Wilkins, T., Sargent, I and Redman, C,** 1991. Trophoblast deportation in pre-eclampsia pregnancy. *Br. J. Obstet Gynaecol*, **98**, 973-979.
- Clark, B.A., Halvorson, L., Sachs, B. and Epstein, F.H,** 1992. Plasma endothelin level in preeclampsia: elevation and correlation with uric acid level and renal impairment. *Am. J. Obstet Gynecol.*, **166**, 962-968.
- Clark, R.K. and Damjanov, I,** 1985. Intermediate filaments of human trophoblast and choriocarcinoma cell lines. *Virchows Arch A. Pathol Anat Histopathol*, **407**, 203-208.
- Cockell, A.P., Learmont, J.G., Smarason, A.K., Redman, C.W., Sargent, I.L. and Poston, L.,** 1997. Human placental syncytiotrophoblast microvillous membranes impair maternal vascular endothelial function. *Br. J. Obstet Gynaecol*, **104**, 235-240.
- Collard, C.D., Montalto, M.C., Reenstra, W.R., Buras, J.A. and Stahl, G.L.,** 2001. Endothelial oxidative stress activates the lectin complimentary pathway: role of cytokeratin 1. *Am. J. Pathol.*, **159**, 1045-1054.

- Collin, C., Moll, R., Kubicka, S., Ouhayoun, J.P and Franke, W.W., 1992a.** Characterization of human cytokeratin 2, an epidermal cytoskeletal protein synthesized late during differentiation. *Exp. Cell Res*, **1**, 132-141.
- Collin, C., Ouhayoun, J.P., Grund, C. and Franke, W.W., 1992b.** Suprabasal marker proteins distinguishing keratinizing squamous epithelium and epidermis are different. *Differentiation*, **51**, 137-148.
- Conde-Agudelo, A. and Blelizan, J.M., 2000.** Risk factor for pre-eclampsia in a large cohort of Latin American and Caribbean women. *Br. J. Obstet Gynaecol*, **107**, 75-83.
- Cooper, D., Schermer, A. and Sun, T-T., 1985.** Biology of disease classification of human epithelia and their neoplasms using monoclonal antibodies to keratins: strategies, applications and limitations. *Lab. Invest.*, **52**, 243-256.
- Coulombe, P.A., and Omary, M.B., 2002.** "Hard and "Soft" principles defining the structure, function and regulation of keratin intermediate filaments. *Curr. Opin. Cell Biol*, **14**, 110-122.
- Coulombe, P.A., Hutton, M.E., Letai, A., Hebert, A., Paller, A.S. and Fuchs, E., 1991.** Point mutations in human keratin 14 genes of epidermolysis bullosa simplex patients: genetic and functional analysis. *Cell*, **66**, 1301-1311.
- Cowin, P. and Garrod, D.R., 1983.** Antibodies to epithelial desmosomes show wide tissue and species cross-reactivity. *Nature*, **302**, 148-150.
- Crewther, W.G., Dowling, L.M., Steinert, P.M. and Parry, D.A.D., 1983.** Structure of intermediate filaments. *International Journal of Biological Macromolecules*, **5**, 267-274.
- Crocker, I., 2007.** Gabor Than Award Lecture 2006: Pre-Eclampsia and Villous Trophoblast Turnover: Perspectives and Possibilities. *Placenta*, **28**, S4-S13.

**Crowther, C.A.**, 1985. Eclampsia at Harare maternity hospital. *S. Afr. Med J*, **68**, 927-929.

**Damsky, C.H., Sutherland, A. and Fisher, S.J.**, 1993. Extramatrix 5: adhesive interactions in early mammalian embryogenesis, implantation, and placentation. *FASEB Journal*, **7**, 1320-1329.

**Damsky, C.H., Fitzgerald, M.L. and Fisher, S.J.**, 1992. Distribution patterns of extracellular matrix components and adhesion receptors are intricately modulated during first trimester cytotrophoblast differentiation along invasive pathway, in vivo. *J.Clin.Invest.*, **89**, 210-222.

**Daya, D. and Sabet, L.**, 1991. The use of cytokeratin as a sensitive and reliable marker for trophoblast tissue. *Am. J Clin Pathol*, **95**, 137-141.

**Dearden, L. and Ockleford, C.D.**, 1983. Structure of human trophoblast: correlation with function. In Loke, Y.W. & Whyte, A., ed, *Biology of Trophoblast*. Amsterdam: Elsevier. 69-110.

**Dekker, G.**, 2002. The partner's role in the etiology of preeclampsia. *J Reprod. Immunol*, **57**, 203-215.

**Dekker, G. and Robillard, P.Y.**, 2007. Pre-eclampsia: Is the immune maladaptation hypothesis still standing? An epidemiological update. *J. Reprod. Immunol*, **76**, 8-16.

**Dekker, G. and Sibai, B.**, 2001. Primary, secondary and tertiary prevention of pre-eclampsia. *The Lancet*, **357**, 209-215.

**Dekker, G.A. and Sibai, B.M.**, 1998. Etiology and pathogenesis of pre-eclampsia: current concepts. *Am J.Obstet. Gynecol.*, **17**, 1359-1375.

- Dobashi, N., Fujita, J., Murota, M., Ohtsuki, Y., Bandoh, S., Ueda, Y., Dohmoto, K., Hojo, S., Nishioka, M., Ishida, T. and Takahara, J.,** 2000. Binding of recombinant human cytokeratin 19 to Laminin: A possible role in interaction between intermediate filament derived from epithelial cells and extracellular matrixes. *Cell structure and function*, **25**, 171-175.
- Douglas, K and Redman, C.,** 1994. Eclampsia in the United Kingdom. *BMJ*, **309**, 1395-1400.
- Duckett, K and Harrington, D.,** 2005. Risk factors for pre-eclampsia at antenatal booking: Systematic review of controlled studies. *BMJ*, **330**, 565-571.
- Duley, L.,** 2003. Pre-eclampsia and the hypertensive disorders of pregnancy. *British Medical Bulletin.*, **67**, 161-176.
- Duley, L.,** 1999. Aspirin for preventing and treating pre-eclampsia. *BMJ*, **318**, 751-752.
- Duley, L.,** 1992. Maternal mortality associated with hypertensive disorders of pregnancy in Africa, Asia, Latin America and the Caribbean. *Br. J. Obstet Gynaecol*, **99**, 547-553.
- Duley, L., Henderson-Smart, D., Knight, M. and King, J.,** 2001. Antiplatelet drugs for prevention of pre-eclampsia and its consequences: systematic review. *Br. Med. J.*, **322**, 329-333.
- Einarsson, J.I., Sangi-Haghpeykar, H. and Gardner, M.O.,** 2003. Sperm exposure and development of preeclampsia. *Obstet. Gynecol.*, **188**, 1241-1243.
- Emmert-Buck, M.R., Bonner, R.F., Smith, P.D., Chuaqui, R.F., Zhuang, Z., Goldstein, S.R., Weiss, R.A. and Liotta, L.A.,** 1996. Laser Capture Microdissection. *Science*, **274**, 998-1001.

- Enders, A.C.**, 1965. Formation of syncytium from cytotrophoblast in human placenta. *Obstet.Gynecol.*, **25**, 378-386.
- England, L. and Zhang, J.**, 2007. Smoking and the risk of preeclampsia: a systematic review. *Front Biosci.*, **12**, 2471-2483.
- Feinberg, R.F., Kliman, H.J and Lockwood, C.J.**, 1991. Is oncofetal fibronectin a trophoblast glue for human implantation? *Am. J. Pathol.*, **138**, 537-543.
- Ferrara, N.**, 2004. Vascular endothelial growth factor: basic science and clinical progress. *Endocr. Rev.*, 581-611.
- Fisher, C., Blumenberg, M. and Tomic-Canic, M.**, 1995. Retinoic receptors and keratinocytes. *Crit Rev Oral Biol Med*, **6**, 284-301.
- Fisher, S.J., Cui, T.Y., Zhang, L., Hartman, L., Grahl, K., Guo-Yang, Z., Tarpey, J. and Damsky, C.H.**, 1989. Adhesive and degradative properties of human placental cytotrophoblast cells in vitro. *J.Cell Biol*, **109**, 891.
- Fisher, S.J., Leitch, M.S., Kantor, M.S., Basbaum, C.B. and Kramer, R.H**, 1985. Degradation of extracellular matrix by the trophoblastic cells of first-trimester human placentas. *J.Cell Biochem*, **27**, 31.
- Formigli, L., Papucci, L., Tani, A., Schiavone, N., Tempestini, A, Orlandini, G.E., Capaccioli, S and Orlandini, S.Z.**, 2000. Aponecrosis: morphological and biochemical exploration of a syncretic process of cell death sharing apoptosis and necrosis. *J. Cell Physiol*, **182**, 41-49.
- Frank, H.G., Malekzadeh, F., Kertschanska, S., Crescimanno, C., Castelluci, M., Lang, I., Desoye, G. and Kaufmann, P.**, 1994. Immunohistochemistry of two different types of placental fibrinoid. *Acta Anat.*, **150**, 55-68.

**Franke, W.W., Schiller, D.L., Hatzfeld, M. and Winter, S.,** 1983. Protein complexes of intermediate filaments: melting of cytokeratin complexes in urea reveals different polypeptide separation characteristics. *Proc. Natl. Acad. Sci. USA*, **80**, 7113-7117.

**Franke, W.W., Schiller, D.L., Hatzfeld, M., Magin, T.M., Jorcano, J.L., Mitnacht, S., Schmid, E., Cohlberg, J.A. and Quinlan, R.A.,** 1984. Cytokeratins: complex formation, biosynthesis, and interactions with desmosomes. In A.J. Levine, G.F. Vande Woude, W.C. Topp, and J.D. Watson, ed, *Cancer Cell*. Cold Spring Harbor, N.Y: Cold Spring Harbor Laboratory. 177-190.

**Franke, W.W., Winter, S., Grund, C., Schmid, E., Schiller, D.L. and Jarasch, E.D,** 1981. Isolation and characterization of desmosome-associated tonofilaments from rat intestinal brush border. *J.Cell Biol*, **90**, 116-127.

**Freedberg, I.M., Tomic-Canic, M., Komine, M. and Blumenberg, M.,** 2001. Keratins and keratinocytes activation cycle. *J. Invest. Dermatol*, **116**, 633-640.

**Freire-de-Lima, C.G., Xiao, Y.Q., Gardia, S.J., Bratton, D.L., Schiemann, W.P and Henson, P.M.,** 2006. Apoptotic cells, through transforming growth factor-beta, coordinately induce anti inflammatory and suppress pro-inflammatory eicosanoid and NO synthesis in murine macrophages. *J Biol chem*, **281**, 38376-38384.

**Friedman, S.A., Schiff, E., Emeis, J.J., Dekker, G.A. and Sabai, B.M.,** 1995. Biochemical corroboration of endothelial involvement in severe pre-eclampsia. *Am.J.Obstet. Gynecol.*, **172**, 202-203.

**Fuch, E. and Weber, K.,** 1994. Intermediate filament: structure, dynamics, function and disease. *Annu Rev Biochem.*, **63**, 345-382.

- Fuch, E., Grace, M.P., Kim, H.K. and Marchuk, D.,** 1984. The transformed phenotype. In A.J. Levine, G.F. Vande Woude, W.C. Topp, and J.D. Watson, ed, *Cancer Cells*. Cold Spring Harbor, N.Y: Cold Spring Harbour Laboratory. 161-167.
- Fuch, E.V., Cooppock, S.M., Green, H. and Cleveland, D.W.,** 1981. Two distinct classes of keratin genes and their evolutionary significance. *Cell*, **27**, 75-84.
- Fuchs, E. and Cleveland, D.W.,** 1998. A structural scaffolding of intermediate filaments in Health and Disease. *Science*, **279**, 514-519.
- Gant, N.F., Daley, G.L., Chand, S., Whalley, P.J. and MacDonald, P.C.,** 1973. A study of angiotensin II presor response throughout primigravid pregnancy. *J. Clin. Invest.*, **52**, 2682-2689.
- Gant, N.F., Whalley, P.J. Everett, R.B., Worley, R.J. and MacDonald, P.C.,** 1987. Control of vascular reactivity in pregnancy. *Am. J. Kidney Dis.*, **9**, 303-307.
- Garnica, A.D and Chan, W.Y.,** 1996. The role of the placenta in fetal nutrition and growth. *J.AM Coll Nutri.*, **15**, 197-198.
- Gaunt, M. and Ockleford, C.D.,** 1986. Microinjection of human placenta, II: biological application. *Placenta*, **7**, 325-331.
- Gauster, M., Moser, G., Orendi, K. and Huppertz, B.,** 2009. Factors involved in regulating trophoblast fusion: potential role in the development of pre-eclampsia. *Placenta*, **30**, Suppl A. S49-S54.
- Geiger, B., Schmid, E. and Franke, W.W.,** 1983. Spatial distribution of proteins specific for desmosomes and adherens junctions in epithelial cells demonstrated by double immunofluorescence microscopy. *Differentiation*, **23**, 189-205.

**Geisler, N. and Weber, K.,** 1983. Amino acid sequence data on glial filament acidic protein (GFA): Implications for the subdivision of intermediate filaments into epithelial and non-epithelial members. *EMBO (Eur. Mol. Biol. Organ.) J*, **2**, 2059-2063.

**Geisler, N. and Weber, K.,** 1982. The amino acid sequence of chicken muscle desmin provides a common structural model for intermediate filament proteins. *EMBO J*, **1**, 1649-1656.

**Germain, S.J., Sacks, G.P., Soorana, S.R., Sargent, I.L. and Redman, C.W.,** 2007. Systemic Inflammatory Priming in Normal Pregnancy and Preeclampsia: The Role of Circulating Syncytiotrophoblast Microparticles. *The Journal of Immunology*, **178**, 5949-5956.

**Gerretsen, G., Huisjes, H.J. and Elema, J.D.,** 1981. Morphological changes of spiral arteries in the placental bed in reaction to pre-eclampsia and fetal growth retardation. *Br. J Obstet Gynaecol*, **88**, 876-881.

**Goldman-Wohl, D.S., Ariel, L., Greenfield, C., Hanoch, J. and Yagel, S.,** 2000. HLA-G expression in extravillous trophoblasts is an intrinsic property of cell differentiation: a lesson learned from ectopic pregnancies. *Mol Hum Reprod.*, **6**, 535-540.

**Goswami, C.D., Tannetta, D.S., Magee, L.A., Fuchisawa, A., Redman, C.W.G., Sargent, I.L. and Von Dadelszen, P.,** 2006. Excess syncytiotrophoblast microparticle shedding is a feature of early-onset pre-eclampsia, but not normotensive intrauterine growth restriction. *Placenta*, **27**, 56-61.

**Gulmezoglu, A.M and Duley, L.,** 1998. Anticonvulsants for women with eclampsia and pre-eclampsia: a survey of obstetricians in the UK and Ireland. *BMJ*, **316**, 975-976.



- Gupta, A.K., Rusterholz, C., Holzgreve, W. and Hahn, S.,** 2005. Syncytiotrophoblast microparticles do not induce apoptosis in peripheral T lymphocytes but differ in their activity depending on the mode of preparation. *J. Reprod. Immunol*, **68**, 15-26.
- Haigh, T., Chen, C., Jones, C.J. and Aplin, J.D.,** 1999. Studies of mesenchymal cells from 1st trimester human placenta: expression of cytokeratin outside the trophoblast lineage. *Placenta*, **20**, 615-625.
- Harada, H., Tamai, Y., Ishikawa, T., Sauer, B., Takaku, K., Oshima, M. and Taketo, M.M.,** 1999. Intestinal polyposis in mice with dominant stable mutation of the beta-catenin gene. *EMBO J.*, **18**, 5931-5942.
- Harris, L.K., Jones, C.J.P. and Aplin, J.D.,** 2009. Adhesion Molecules in Human Trophoblast – A Review. II. Extravillous Trophoblast. *Placenta*, **30**, 299-304.
- Hatzfeld, M. and Franke, W.W.,** 1985. Pair formation and promiscuity of cytokeratins: Formation in vitro of heterotypic complexes and intermediate-sized filaments by homologous and heterologous recombinations of purified polypeptides. *J. Cell Biol*, **101**, 1826-1841.
- Hatzfeld, M. and Weber, K.,** 1990. The coiled coil of in vitro assembled keratin filaments is a heterodimer of type I and type II keratins: use of site-specific mutagenesis and recombinant protein expression. *J. Cell Biol*, **110**, 1199-1210.
- Hefler, L.A., Tempfer, C.B., Bancher-Todesca, D., Schatten, C., Husslein, P., Heinze, G. and Gregg, A.R.,** 2001. Placental expression and serum levels of cytokeratin-18 are increased in women with preeclampsia. *J.Soc.Gynecol.Investig.*, **8**, 169-173.

**Hembrough, T.A., Kralovich, K.R., Li, L. and Gonias, S.L.,** 1996. Cell-surface cytokeratin 8 is the major plasminogen receptor on breast cancer cells and is required for the accelerated activation of cell-associated plasminogen by tissue-type plasminogen activator. *Biochem J*, **317**, 763-769.

**Hembrough, T.A., Vasudevan, J. Allietta, M.M., Glass II, W.F. and Gonias, S.L.,** 1995. A cytokeratin 8-like protein with plasminogen-binding activity is present on the external surfaces of hepatocytes HepG2 cells and breast carcinoma cell lines. *J. Cell Sci.*, **108**, 1071-1082.

**Hesse, M., Franz, T., Tamai, Y., Taketo, M. and Magin, M.T.,** 2000. Targeted deletion of keratin 1 and 19 leads to trophoblast fragility and early embryonic lethality. *EMBO J*, **19**, 5060-5070.

**Hesse, M., Magin, M.T. and Weber, K.,** 2001. Genes for intermediate filament proteins and the draft sequence of the human genome: novel keratin genes a surprisingly high number of pseudogenes related to keratins 8 and 18. *J.Cell Sci.*, **114**, 2569-2575.

**Hesse, M., Zimek, A., Weber, K. and Magin, M.T.,** 2004. Comprehensive analysis of keratin gene clusters in humans and rodents. *Eur.J.Cell Biol*, **83**, 19-26.

**Hsu, C.D., Iriye, B., Johnson, T.R., Witter, F.R., Hong, S.F. and Chan, D.W.,** 1993. Elevated circulating thrombomodulin in severe pre-eclampsia. *Am.J.Obstet. Gynecol.*, **169**, 148-149.

**Hubel, C.A., Roberts, J.M., Taylor, R.N, Musci, T.J., Rogers, G.M and McLaughlin, M.K.,** 1989. Lipid peroxidation in pregnancy: New perspectives in pathological pregnancies. *Am J Pathol*, **159**, 1031-1043.

- Hung, T-H., Skepper, J.N. and Burton, G.J.,** 2001. In vitro ischemia-reperfusion injury in term human placenta as a model for oxidative stress in pathological pregnancies. *Am J Pathol*, **159**, 1031-1043.
- Hung, T-H., Skepper, J.N., Charnock-Jones, D.S. and Burton, G.J.,** 2002. Hypoxia/reoxygenation. A potent inducer of apoptotic changes in the human placenta and possible etiological factor in preeclampsia. *Circulation Research*, **90**, 1274-1281.
- Huppertz, B., Kertschanska, S., Frank, H.G., Gaus, G., Funayama, H and Kaufmann, P.,** 1996. Extracellular matrix components of the placental extravillous trophoblast: Immunocytochemistry and ultrastructural distribution. *Histochem. Cell Biol*, **106**, 291-301.
- Huppertz, B.,** 2008. Placental origin of preeclampsia: challenging the current hypothesis. *Hypertension.*, **51**, 970-975.
- Huppertz, B., Frank, H.G., Kingdom, J.C.P., Reister, F. and Kaufmann, P.,** 1998. Villous cytotrophoblast regulation of the syncytial apoptotic cascade in the human placenta. *Histochem. Cell Biol*, **110**, 497-508.
- Huppertz, B., Kingdom, J., Caniggia, I., Desoye, G., Black, S., Korr, H. and Kaufmann, P.,** 2003. Hypoxia favours necrotic versus apoptotic shedding of placental Syncytiotrophoblast into the Maternal Circulation. *Placenta*, **24**, 181-190.
- Hustin, J.,** 1992. The maternotrophoblastic interface: Uteroplacental blood flow. In Barnea, ER., Hustin, J., and Jauniaux, E., ed, *The first twelve weeks of gestation*. Berlin, Germany: Springer-Verlag. 97-110.

- Hutton, E., Paladini, R.D., Yu, Q.C., Yen, M., Coulombe, P.A. and Fuchs, E., 1998.** Functional differences between keratins of stratified and simple epithelia. *J. Cell Biol*, **143**, 487-499.
- Irgens, H., Reisater, L., Irgens, L., Lie, R. and Roberts, J., 2001.** Long term mortality of mothers and fathers after pre-eclampsia: population based cohort study Pre-eclampsia and cardiovascular disease later in life: who is at risk? *BMJ*, **323**, 1213-1217.
- Jackson, B.W., Grund, C., Schmid, E., Burki, K., Franke, W.W. and Illmensee, K., 1980.** Formation of cytoskeletal elements during mouse embryogenesis. Intermediate filaments of the cytokeratin type and desmosomes in preimplantation embryo. *Differentiation*, **17**, 161-179.
- Jaquemar, D., Kupriyanov, S., Wankell, M. Avis, J., Benirschke, K., Baribault, H. and Oshima, R.G, 2003.** Keratin 8 protection of placenta barrier function. *J. Cell Biol*, **161**, 749-756.
- Jauniaux, E., Gulbris, B. and Burton, G.J., 2003.** The human first trimester gestational sac limits rather than facilitates oxygen transfer to the foetus- a Review. *Placenta*, **24Suppl A**, S86-S93.
- Jauniaux, E., Poston, L. and Burton, G.J., 2006.** Placenta-related disease of pregnancy: involvement of oxidative stress and implications in human evolution. *Human Reproductive Update*, **12**, 747-755.
- Jauniaux, E., Watson, A.L., Hempstock, J., Bao, Y-P., Skepper, J.N. and Burton, G.J, 2000.** Onset of maternal arterial blood flow and placental oxidative stress: a possible factor in human early pregnancy failure. *Am J Pathol*, **157**, 2111-2122.

- Johansen, M., Redman, C.W.G., Wilkins, T. and Sargent, I.L.,** 1999. Trophoblast Deportation in Human Pregnancy—its Relevance for Pre-eclampsia. *Placenta*, **20**, 531-539.
- Jones, C.J. and Fox, H.,** 1991. Ultrastructure of the human placenta. *Electron Microsc. Rev.*, **4**, 129-178.
- Jones, C.J.P. and Fox, H.,** 1980. An ultrastructural and ultrahistochemical study of the human placenta in maternal pre-eclampsia. *Placenta*, **1**, 61-76.
- Jones, C.J.P., Harris, L.K., Whittingham, J., Aplin, J.D. and Mayhew, T.M.,** 2008. A Re-appraisal of the Morphophenotype and Basal Lamina Coverage of Cytotrophoblasts in Human Term Placenta. *Placenta*, **29**, 215-219.
- Kaltenbach, F.J. and Sachs, W.,** 1979. The uptake of tritiated thymidine in human fetal membranes during the last third of pregnancy. *Z. Geburtshilfe Perinatol*, **183**, 285-295.
- Kemp, B., Kertschanska, S., Kadyrov, M., Rath, W., Kaufmann, P. and Huppertz, B.,** 2002. Invasive depth of extravillous trophoblast correlates with cellular phenotype- a comparison of intra- and extrauterine implantation sites. *Histochem. Cell Biol*, **117**, 401-414.
- Khan, K.S., Wojdyla, D., Say, L., Gulmezoglu, A.M., Van Look, P.F.,** 2006. WHO analysis of causes of maternal death: a systematic review. *Lancet*, **367**, 1066-1074.
- Khong, T.Y., Lane, E.B. and Robertson, W.B.,** 1986. An immunocytochemical study of fetal cells at the maternofetal placental interface using monoclonal antibodies to keratin, vimentin and desmin. *Cell & Tissue Research*, **246**, 189-195.
- Kim, S., Wong, P. and Coulombe, P.A.,** 2006. A keratin cytoskeletal protein regulates protein synthesis and epithelial growth. *Nature*, **441**, 362-365.

- King, A. and Loke, Y.W.**, 1988. Differential expression of blood-group-related carbohydrate antigens by trophoblast subpopulations. *Placenta*, **9**, 513-521.
- Klonoff-Cohen, H.S., Savitz, D.A., Cefalo, R.C. and McCann, M.F.**, 1989. An epidemiologic study of contraception and pre-eclampsia. *J. Am. Med. Assoc.*, **262**, 3143-3147.
- Klymkowsky, M.W.**, 1995. Intermediate filaments: new proteins, some answers, more questions. *Curr. Opin. Cell Biol*, **7**, 46-54.
- Knight, M on behalf of UKOSS.**, 2007. Eclampsia in the United Kingdom 2005. *BJOG*, **114**, 1072-1078.
- Knight, M., Redman, C.W.G., Linton, E.A. and Sargent, I.L.**, 1998. Shedding of syncytiotrophoblast microvilli into the maternal circulation in pre-eclamptic pregnancies. *Br. J Obstet Gynaecol*, **105**, 632-640.
- Knox, K. and Carrigan, D.**, 2009. *Detection of HHV-6, EBV and HTLV-2 Genomic DNAs*. [online]. Available at: [http://www.wisconsinlab.com/nested\\_pcr.htm](http://www.wisconsinlab.com/nested_pcr.htm) [accessed 03/13 2009].
- Koelman, C.A., Coumans, A.B.C., Nijman, H.W., Doxiadis, I.I.N., Dekker, G.A. and Class, F.H.J.**, 2000. Correlation between oral sex and low incidence of pre-eclampsia in subsequent pregnancy. *Am J. Epidemiol*, **151**, 57-62.
- Kolega, J., Manabe, M. and Sun, T.T.**, 1989. Basement membrane heterogeneity and variation in corneal epithelial differentiation. *Differentiation*, **42**, 54-63.
- Krysko, D.V., D'Herde, K. and Vandenabeele, P.**, 2006. Clearance of apoptotic and necrotic cells and its immunological consequences. *Apoptosis*, **11**, 1709-1726.

- Ku, N.O., Gish, R., Wright, T.L. and Omary, M.B,** 2001. Keratin 8 mutations in patients with crptogenic liver disease. *New Eng. J. Med.*, **344**, 1580-1587.
- Ku, N.O., Soetikno, R.M. and Omary, M.B,** 2003. Keratin mutation in transgenic mice predisposes to fas but not TNF-induced apoptosis and massive liver injury. *Hepatology*, **37**, 1006-1014.
- Kurpakus, M.A., Stock, E.L. and Jones, J.C.R.,** 1992. The role of the basement membrane in differential expression of keratin proteins in epithelial cells. *Developmental Biology*, **150**, 243-255.
- Laemmli, U.K.,** 1970. Cleavage of structural proteins during the assembly of the head of bacteriophage T4. *Nature*, **227**, 680-684.
- Lala, P.K. and Graham, C.H.,** 1990. Mechanism of trophoblast invasiveness and their control: the role of proteases and protease inhibitors. *Cancer Metastasis Rev.*, **9**, 369-379.
- Lala, P.K. Hamilton, G.S. and Athanassiades, A.,** 1998. Role of growth factors and other placental signals in extravillous trophoblast cell function. *Trophoblast Research*, **12**, 327-339.
- Lampinen, K.H., Ronnback, M., Kaaja, R.J and Groop, P.H.,** 2006. Impaired vascular dilatation in women with history of pre-eclampsia. *Journal of Hypertension*, 751-756.
- Lane, E.B and McLean, W.H.,** 2004. Keratins and skin disorders. *J. Pathol*, **204**, 355-366.
- Lane, E.B., Rugg, E.L., Navsaria, H., Leigh, I.M., Heagerty, A.H., Ishida-Yamamoto, A. and Eady, R.A,** 1992. A mutation in the conserved helix termination peptide of keratin 5 in hereditary skin blistering. *Nature*, **356**, 244-246.

**Langer, A., Villar, J., Tell, K., Kim, T., Kennedy, S., 2008.** Reducing eclampsia-related deaths- a call to action. *Lancet*, **371**, 705-706.

**Lash, G.E., Otun, H.A., Innes, B.A., Kirkley, M., De Oliveira, L., Searle, R.F., Robson, S.C. and Bulmer, J.N., 2006.** Interferon- $\gamma$  inhibits extravillous trophoblast cell invasion by a mechanism that involves both changes in apoptosis and protease levels. *FASEB J.*, **20**, 2512-2518.

**Le Bouteiller, P., Pizzato, N., Barakonyi, A. and Solier, C, 2003.** HLA-G, Pre-eclampsia, Immunity and vascular events. *J Reprod. Immunol*, **59**, 219-234.

**Levine, R.J., Lam, C., Qian, C., Yu, K.F., Maynard, S.E., Sachs, B.P., Sibai, B.M., Epstein, F.H., Romero, R., Thadhani, R. and S. Karumanchi, S.A., 2006.** Soluble endoglin and other circulating antiangiogenic factors in pre-eclampsia. *N. Engl. Med.*, **355**, 992-1005.

**Levine, R.T., Maynard, S.E., Qian, C., Lim, K.H., England, L.J., Yu, K.F., Schisterman, E.F., Thadhani, R., Sachs, B.P., Epstein, F.H., Sibai, B.M., Sukhatme, V.P. and Karumanchi, S.A., 2004.** Circulating angiogenic factors and the risk of preeclampsia. *N. Engl. J Med.*, **350**, 672-683.

**Lim, K.H., Damsky, C.H. and Fisher, S.J., 1995.** Basic fibroblast growth factor and heparin stimulating integrin- $\alpha$ -1 expression by cytotrophoblast. *J.Soc.Gynecol.Invest.*, **2**, 287.

**Linder, S., 2007.** Cytokeratin markers come of age. *Tumour Biol*, **28**, 189-195.

**Linder, S., Havelka, A.M., Ueno, T., Shoshan, M.C., 2004.** Determining tumour apoptosis and necrosis in patient serum using cytokeratin 18 as a biomarker. *Cancer Lett*, **21**, 1-9.



- Lo, Y. M., Leeung, T.N., Sargent, I.L., Zhang, J., Lau, T.K., Haines, C.J and Redman, C.W.G,** 1999. Quantitative abnormalities of fetal DNA in maternal serum in pre-eclampsia. *Clin. Chem*, **45**, 184-188.
- Loke, Y.W. and King, A.,** 1995. *Human Implantation: cell biology and immunology*. Cambridge: Cambridge University Press.
- Lu, H., Hesse, M., Peters, B. and Magin, T.M.,** 2005. Type II keratins precede type I keratins during early embryonic development. *European Journal of Cell Biology*, **84**, 709-718.
- Lu, H., Zimek, A., Chen, J., Hesse, M., Büssow, H., Weber, K. and Magin, T.M.,** 2006. Keratin 5 knockout mice reveal plasticity of keratin expression in the corneal epithelium. *European Journal of Cell Biology*, **85**, 803-811.
- Luna, E.J and Hitt, A.L,** 1992. Cytoskeleton plasma membrane interaction. *Science*, **258**, 955-964.
- Lyall, F., Young, A. and Green, I.A.,** 1995. Nitric oxide concentrations are increased in the fetoplacental circulation in pre-eclampsia. *Am J.Obstet. Gynecol.*, **173**, 714-718.
- Mackay, A.P., Berg, C.J. and Atrash, H.K.,** 2001. Pregnancy-related mortality from preeclampsia and eclampsia. *Obstet Gynecol*, **97**, 533-538.
- Mackey, A.M., Tracy, R.P. and Craighead, J.E.,** 1990. Cytokeratin expression in rat mesothelial cells in vitro is controlled by the extracellular matrix. *J. Cell Sci.*, **95**, 97-107.
- Madretsma, G.S., Donze, G.J., van Dijk, A.P., Tak, C.J., Wilson, J.H. and Zijlstra, F.J.,** 1996. Nicotine inhibits the in vitro production of interleukin 2 and tumour necrosis factor-alpha by human mononuclear cells. *Immunopharmacology*, **35**, 47-51.

**Magin, T.M., Schroder, R., Leitgeb, S., Wanniger, F., Zatloukal, K., Grund, C. and Melton, D.W.,** 1998. Lessons from keratin 18 knockout mice: formation of novel keratin filaments, secondary loss of keratin 7 and accumulation of liver- specific keratin 8-positive aggregates. *J. Cell Biol*, **140**, 1441-1451.

**Maldonado-Estrada, J., Menu, E., Roques, P., Barré-Sinoussi, F. and Chaouat, G.,** 2004. Evaluation of Cytokeratin 7 as an accurate intracellular marker with which to assess the purity of human placental villous trophoblast cells by flow cytometry. *Journal of Immunological Methods*, **286**, 21-34.

**Markey, A.C., Lane, E.B., Churchill, Z.J., MacDonald, D.M. and Leigh, I.M.,** 1991. Expression of simple epithelial keratins 8 and 18 in epidermal neoplasm. *J. Invest. Dermatol*, **97**, 763-770.

**Marti, J.J. and Herrmann, U.,** 1977. Immunogestosis: a new etiologic concept of "essential" EPH gestosis, with special consideration of the primigravid patient. *Am. J. Obstet. Gynecol.*, **128**, 489-493.

**Mayhew, T.M.,** 2009. Quantifying Immunogold Localization Patterns on Electron Microscopic Thin Sections of Placenta: Recent Developments. *Placenta*, **30**, 565-570.

**Mayhew, T.M.,** 2007. Quantitative immunoelectron microscopy: alternative ways of assessing subcellular patterns of gold labelling. *Methods Mol Biol*, **369**, 309-329.

**Mayhew, T.M. Griffiths, G., and Lucocq, J.M.,** 2004. Applications of an efficient method for comparing immunogold labelling patterns in the same sets of compartments in different groups of cells. *Histochem. Cell Biol*, **122**, 171-177.

**Mayhew, T.M., Leach, L., McGee, R., Ismail, W.W., Myklebust, R. and Lammiman, M.J.,** 1999. Proliferation and apoptosis in villous trophoblast at 13-41 weeks of gestation

(including observations on annulate lamellae and nuclear pore complexes). *Placenta*, **20**, 407-422.

**Maynard, S.E., Min, J-Y., Merchan, J., Lim, K-H., Li, J., Mondal, S., Libermann, T.A., Morgan, J.P., Sellke, F.W., Stillman, I.E., Epstein, F.H., Sukhatme, V.P. and Karumanchi, A.**, 2003. Excess placental soluble fms-like tyrosine kinase (sFlt1) may contribute to endothelial dysfunction, hypertension, and proteinuria in pre-eclampsia. *Journal of Clinical Investigation.*, **111**, 649-658.

**McKeeman, G.C., Ardill, J.E., Caldwell, C.M., Hunter, A.J. and McClure, N.**, 2004. Soluble vascular endothelial growth factor receptor-1 (sFlt-1) is increased throughout gestation in patients who have preeclampsia develop. *Am J.Obstet. Gynecol.*, **191**, 1240-1246.

**Meekins, J.W., Pijnenborg, R., Hanssens, M., McFadyen, I.R. and van Asshe, A.**, 1994. A study of placental bed spiral arteries and trophoblast invasion in normal and severe preeclamptic pregnancies. *Br. J. Obstet Gynaecol*, **101**, 669-674.

**Meng, J.J., Bornslaeger, E.A., Green, K.J., Steinert, P.M. and Ip, W.**, 1997. Two-hybrid analysis reveals fundamental differences in direct interactions between desmoplakin and cell type-specific intermediate filaments. *J Biol chem*, **272**, 21495-21503.

**Metz, J. and Weihe, E.**, 1980. Intercellular junctions in full term human placenta. II. Cytotrophoblast cells and blood vessels. *Anat. Embrol (Berl)*, **158**, 167-178.

**Metz, J., Weihe, E. and Heinrich, D.**, 1979. Intercellular junctions in full term human placenta. I. Syncytiotrophoblastic layer. *Anat. Embrol (Berl)*, **158**, 41-50.

**Mills, J.L., Dersimonian, R., Raymond, E., Morrow, J.D., Roberts II, L.J., Clemens, J.C., Catalano, P., Sibai, B., Curet, L.B. and Levine, R.J.,** 1999. Prostacyclin and thromboxane changes predating clinical onset of preeclampsia: a multicenter prospective study. *JAMA*, **282**, 356-362.

**Moffett, A. and Hiby, S.E.,** 2007. How Does the Maternal Immune System Contribute to the Development of Pre-eclampsia? *Placenta*, **28**, S51-S56.

**Moll, R., Divo, M. and Langbein, L.,** 2008. The human keratins: biology and pathology. *Histochem. Cell Biol*, **129**, 705-733.

**Moll, R., Franke, W.W., Schiller, D.L., Geiger, B. and Krepler, R.,** 1982. The catalog of human cytokeratins: patterns of expression in normal epithelia, tumors and cultured cells. *Cell*, **31**, 11-24.

**Moll, R., Lowe, A., Laufer, J. and Franke, W.W.,** 1992. Cytokeratin 20 in human carcinomas. A new histodiagnostic marker detected by monoclonal antibodies. *Am. J. Pathol*, **140**, 427-447.

**Moll, R., Schiller, D.L. and Franke, W.W.,** 1990. Identification of protein IT of the intestinal cytoskeleton as a novel type I cytokeratin with unusual properties and expression patterns. *J. Cell Biol*, **111**, 567-580.

**Mori, M., Ishikawa, G., Luo, S.S., Mishima, T., Goto, T., Robinson, J.M., Matsubara, S., Takeshita, T., Kataoka, H. and Takizawa, T.,** 2007. The cytotrophoblast layer of human chorionic villi becomes thinner but maintains its structural integrity during gestation. *Biol.Reprod.*, **76**, 164-172.

- Mueller, H. and Franke, W.W.,** 1983. Biochemical and immunological characterization of desmoplakins I and II, the major polypeptides of desmosomal plaque. *J.Mol.Biol*, **163**, 647-671.
- Muhlhauser, J., Crescimanno, C., Kasper, M., Zaccheo, D. and Castlucci, M.,** 1995. Differentiation of Human Trophoblast Population Involves Alterations in Cytokeratin Patterns. *Journal of Histochemistry and Cytochemistry*, **43**, 579-589.
- Mutter, W.P. and Karumanchi, S.A.,** 2008. Molecular mechanisms of preeclampsia. *Microvascular Research*, **75**, 1-8.
- Myatt, L., Rosenfield, R.B., Eis, A.L.W., Brockman, D.E., Greer, I. and Lyall, F.,** 1996. Nitrotyrosine residue in placenta. Evidence of peroxynitrite formation and action. *Hypertension.*, **28**, 488-493.
- Ness, R.B. and Roberts, J.M.,** 1996. Heterogeneous causes constituting the single syndrome of preeclampsia, a hypothesis and its implications. *Am. J.Obstet. Gynecol.*, **175**, 1365-1370.
- Ness, R.B., Markovic, N., Harger, G. and Day, R.,** 2004. Barrier Methods, Length of Preconception Intercourse, and Preeclampsia. *Hypertension in Pregnancy*, **23**, 227-235.
- Neudeck, H., Oei, S.L., Stiemer, B., Hopp, H. and Graf, R.,** 1997. Binding of antibodies against high and low molecular weight cytokeratin proteins in the human placenta with special reference to infarcts, proliferation and differentiation processes. *Histochem. J.*, **29**, 419-430.
- Norwitz, E.R., Schust, D.J. and Fisher, S.J.,** 2001. Implantation and the survival of early pregnancy. *N Engl Med.*, **345**, 1400-1408.

- Nova, A., Sibai, B.M., Barton, J.R., Mercer, B.M and Mitchell, M.D,** 1991. Maternal plasma level of endothelin is increased in pre-eclampsia. *American Journal of Obstetrics & Gynecology*, **165**, 724-727.
- Ockleford, C.D., Dearden, L. and Badley, R.A.,** 1984. syncytioskeletons in choriocarcinoma in culture. *J. Cell Sci.*, **66**, 1-20.
- Ockleford, C.D., Mongan, L.C. and Hubbard, A.R.D.,** 1997. Techniques of advanced light microscopy and their application to morphological analysis of human extra-embryonic membranes. *Microscopy Research & Technique*, **38**, 153-164.
- Ockleford, C.D., Wakely, J. and Badley, R.A.,** 1981a. Morphogenesis of human placental chorionic villi: cytoskeletal, syncytioskeletal and extracellular matrix proteins. *Proc. R. Soc.Lond. B.*, **212**, 305-316.
- Ockleford, C.D., Wakely, J. and Badley, R.A. and Virtanen, I,** 1981b. Intermediate filament proteins in human placenta. *Cell Biol. Int Rep.*, **5**, 762.
- Ockleford, C.D., Bradbury, F.M. and Indans, I.,** 1990. Localisation of cytoskeletal proteins in chorionic villi. In L. Cedar, E. Alsat, J.C. Challier, G. Chaouat, A. Malassine, ed, *Placenta communications: biochemical, morphological and cellular aspects*. Paris: Colloque INSERM/John Libbey Eurotex Ltd. 239-250.
- Ockleford, C.D., Smith, R.K., Byrne, S., Sanders, R. and Bosio, P.,** 2004. Confocal laser scanning microscope study of cytokeratin immunofluorescence differences between villous and extravillous trophoblast: cytokeratin downregulation in pre-eclampsia. *Microscopy Research & Technique*, **64**, 43-53.
- Ohlsson, R.,** 1989. Growth factors, protooncogenes and human placental development. *Cell Differ Dev*, **28**, 1.

- Oriolo, A.S., Wald, F.A., Ramsauer, V.P. and Salas, P.J.,** 2007. Intermediate filaments: a role in epithelial polarity. *Exp. Cell Res*, **313**, 2255-2264.
- Osborn, M. and Weber, K.,** 1983. Biology of disease: tumor diagnosis by intermediate filament typing: a novel tool for surgical pathology. *Lab. Invest.*, **48**, 372-394.
- Oshima, R.G.,** 2002. Apoptosis and keratin intermediate filaments. *Cell Death Differentiation*, **9**, 486-492.
- Oshima, R.G., Trevor, K., Shevinsky, L.H., Ryder, O.A. and Cecena, G.,** 1988. Identification of the gene encoding the Endo B murine cytokeratin and its methylated, stable inactive state in mouse none epithelial cells. *Gene Dev.*, **2**, 505-516.
- Paddock, S.W.,**ed, 1999. *Methods in Molecular Biology: Confocal Microscopy Methods and Protocol*. Totowa, New Jersey: Humana Press.
- Paladini, R.D., Takahashi, K., Bravo, N.S. and Coulombe, P.A.,** 1996. Onset of re-epithelialization after skin injury correlates with a reorganization of keratin filaments in wound edge keratinocytes defining a role for keratin 16. *J. Cell Biol*, **132**, 381-397.
- Paramio, J.M., Casanova, M.L., Segrelle, C., Mitnacht, S., Lane, E.B. and Jorcano, J.L.,** 1999. Modulation of cell proliferation by cytokeratin K10 and K16. *Mol Cell Biol*, **19**, 3086-3094.
- Parham, P.** 2004. Killer cell immunoglobulin-like receptor diversity: balancing signals in the natural killer cell response. *Immunol Lett*, **29**, 11-13
- Parry, D.A., Strelkov, S.V., Burkhard, P., Aebi, U. and Herrmann, H.,** 2007. Towards a molecular description of intermediate filament structure and assembly. *Exp. Cell Res*, **313**, 2204-2216.

- Pijnenborg, R., Antony, J., Davey, D.A., Rees, A., Tiltman, A., Vercruysse, L. and van Assche, A.,** 1991. Placental bed spiral arteries in the hypertensive disorders of pregnancy. *Br. J Obstet Gynaecol*, **98**, 642-655.
- Pijnenborg, R., Bland, J.M., Robertson, W.B. and Brosens, I.,** 1983. Uteroplacental arterial changes related to interstitial trophoblast migration in early human pregnancy. *Placenta*, **4**, 397-413.
- Pijnenborg, R., Dixon, G., Robertson, W.B. and Brosens, I.,** 1980. Trophoblastic invasion of human decidua from 8 to 18 weeks of pregnancy. *Placenta*, **1**, 3-19.
- Pijnenborg, R., McLaughlin, P.J., Vercruysse, L., Hanssens, M., Johnson, P.M., Keith, J.C. and VanAssche, F.A.,** 1998. Immunolocalization of tumour necrosis factor- $\alpha$  (TNF- $\alpha$ ) in the placental bed of normotensive and hypertensive human pregnancies. *Placenta*, **19**, 231-239.
- Pijnenborg, R., Vercruysse, L. and Hanssens, M.,** 2006. The Uterine Spiral Arteries In Human Pregnancy: Facts and Controversies. *Placenta*, **27**, 939-958.
- Piredda, L., Amendola, L., Colizzi, V., Davies, P.J., Farace, M.G., Fraziano, M., Gentile, V., Uray, I., Piacentini, M. and Fesus, L.,** 1997. Lack of "tissue" transglutaminase protein cross-linking leads to leakage of macromolecules from dying cells: relationship to development of autoimmunity in MRLIpr/Ipr mice. *Cell Death Differ*, **4**, 463-472.
- Pitelka, D.R., Taggart, B.M. and Hamamoto, S.T.,** 1983. Effect of extracellular calcium depletion on membrane topography and occluding junctions of mammary epithelial cells in culture. *J. Cell Biol*, **96**, 613-624.



- Poranen, A.K., Ekblad, U., Uotila, P. and Ahotuba, M.,** 1996. Lipid peroxidation and antioxidants in normal and preeclamptic pregnancies. *Placenta*, **17**, 401-405.
- Pötgens, A.J.G., Gaus, G., Frank, H.G. and Kaufmann, P.,** 2001. Characterization of Trophoblast Cell Isolations by a Modified Flow Cytometry Assay. *Placenta*, **22**, 251-255.
- Pröll, J., Blaschitz, A., Hartmann, M., Thalhamer, J. and Dohr, G.,** 1997. Cytokeratin 17 as an immunohistochemical marker for intramural cytotrophoblast in human first trimester uteroplacental arteries. *Cell Tissue Res.*, **288**, 335-343.
- Quinlan, R.A., Cohlberg, J.A., Schiller, D.L., Hatzfeld, M., and Franke, W.W,** 1984. Heterotypic tetramer (A2D2) complexes of non-epidermal keratins isolated from cytoskeletons of rat hepatocytes and hepatoma cells. *J.Mol.Biol*, **178**, 365-388.
- Quinlan, R.A., Schiller, D.L., Hatzfeld, M., Achtstatter, T., Moll, R., Jorcano, J.L., Magin, T.M and Franke, W.W,** 1985. Pattern of expression and organization of cytokeratin intermediate filaments. In E. Wang, D. Fischman, R. K. H Liem, and T-T. Sun, ed, *Intermediate Filaments*. New York: The New York Academy of Sciences. New York. 282-306.
- Rasmussen, C.A., Pace, J.L., Banerjee, S., Phillips, T.A. and Hunt, J.S.,** 1999. Trophoblastic cell lines generated from tumour necrosis factor receptor-deficient mice reveal specific functions for the two tumour necrosis factor receptors. *Placenta*, **20**, 213-222.
- RCOG,** 2004. *The confidential Enquiry into Maternal deaths in the United Kingdom. Why mothers die: 2000-2002 report*. London: RCOG Press.
- Reddy, A., Zhong, X.Y., Rusterholz, C., Hahn, S., Holzgreve, W., Redman, C.W.G. and Sargent, I.L.,** 2008. The Effect of Labour and Placental Separation on the Shedding

of Syncytiotrophoblast Microparticles, Cell-free DNA and mRNA in Normal Pregnancy and Pre-eclampsia. *Placenta*, **29**, 942-949.

**Redman, C.W. and Sargent, I.L.**, 2005. Latest advances in understanding preeclampsia. *Science*, **308**, 1592-1594.

**Redman, C.W.G. and Sargent, I.L.**, 2000. Placental Debris, Oxidative stress and Pre-eclampsia. *Placenta*, **21**, 597-602.

**Redman, C.W.G., Sacks, G.P. and Sargent, I.L.**, 1999. Pre-eclampsia, an excessive maternal inflammatory response to pregnancy. *Am.J.Obstet Gynecol*, **180**, 499-506.

**Redman, C.W.G.**, 1991. Current topic. Pre-eclampsia and the placenta. *Placenta*, **12**, 301-308.

**Reister, F., Frank, H.G., Heyl, W., Kosanke, G., Huppertz, B., Schröder, W., Kaufmann, P. and Rath, W.**, 1999. The Distribution of Macrophages in Spiral Arteries of the Placental Bed in Pre-eclampsia Differs from that in Healthy Patients. *Placenta*, **20**, 229-233.

**Rentzsch, B., Todiras, M., Iliescu, R., Popova, E., Campos, L.A., Oliveira, M.L., Baltatu, O.C., Santos, R.A. and Bader, M.**, 2008. Transgenic Angiotensin-converting enzyme 2 over expression in vessels of SHRSP rats reduces blood pressure and improves endothelial function. *Hypertension.*, **52**, 967-973.

**Roberts, J. and Cooper, D.**, 2001. Pathogenesis and genetics of pre-eclampsia. *The Lancet*, **357**, 53-56.

**Roberts, J. and Redman, C.W.**, 1993. Pre-eclampsia: more than pregnancy-induced hypertension. *Lancet*, **341**, 1447-1454.

- Roberts, J.M.**, 1995. Magnesium for preeclampsia and eclampsia. *N. Engl. J Med.*, **333**, 250-251.
- Roberts, J.M., Taylor, R.N., Musci, T.J., Rodgers, G.M., Hubel, C.A., and McLaughlin, M.K.**, 1989. Preeclampsia and endothelial cell disorder. *Am J.Obstet. Gynecol.*, **161**, 1200-1204.
- Roberts, J.M., Taylor, R.N. and Goldfien, A.**, 1991. A clinical and biochemical evidence of endothelial dysfunction in pregnancy syndrome preeclampsia. *Am. J. Hpertens.*, **4**, 700-708.
- Roberts, M.R., Ezashi, T., Das, P.**, 2004. Trophoblast gene expression: Transcription factors in the specification of early trophoblast. *Reproductive Biology and Endocrinology.*, **2**, 1-9.
- Roberts, J.M.**, 1998. Endothelial dysfunction in pre-eclampsia. *Semin. Reprod Endocrinol*, **16**, 5-11.
- Robillard, P.Y., Hulsey, T.C., Alexander, G.R. Keenan, A., de Caunes, F. and Papiernik, E**, 1993. Paternity patterns and risk of pre-eclampsia in the last pregnancy in multipare. *J.Reprod.Immunol.*, **24**, 1-12.
- Robillard, P.Y., Hulsey, T.C., Perianin, J., Janky, E., Miri, E.H. and Papiernik, E**, 1994. Association of pregnancy-induced hypertension with duration of sexual cohabitation before conception. *Lancet*, **344**, 973-975.
- Robinson, N.J., Baker, P.N., Jones, C.J.P and Aplin, J.D.**, 2007. A role for tissue transglutaminase in stabilization of membrane-cytoskeletal particles shed from the human placenta. *Biology of Reproduction*, **77**, 648-657.

- Rogers, M.A., Winter, H., Langbein, L., Bleiler, R. and Schweizer, J.,** 2004. The human type I keratin gene family: Characterization of new hair follicle specific members and evaluation of chromosome 17q21.2 gene domain. *Differentiation*, **72**, 527-540.
- Rogers, M.A., Edler, L., Winter, H., Langbein, L., Beckman, I. and Schweizer, J.,** 2005. Characterization of new members of the human type II keratin gene family and a general evolution of the keratin gene domain on chromosome 12q13.13. *J. Invest. Dermatol*, **124**, 536-544.
- Rowe, J., Campbell, S. and Gallery, E.D.,** 2003. Nitric oxide production by decidual endothelial cells is not reduced in preeclampsia. *Hypertens pregnancy*, **22**, 63-75.
- Roze, S. and Skaletsky, H.J.,** 2000. Primer3 on the www for general users and for biologist programmers. In Krawetz S, M. S., ed, *Bioinformatics methods and protocols: Methods in Molecular Biology*. Totowa, NJ.: Humana press. 365-386.
- [http://frodo.wi.mit.edu/cgi-bin/primer3/primer3\\_www.cgi](http://frodo.wi.mit.edu/cgi-bin/primer3/primer3_www.cgi) [accessed September/1/2008]
- Sacks, G.P., Studena, K. and Redman, C.W.G.,** 1998. Normal pregnancy and preeclampsia both produce inflammatory changes in peripheral blood leukocytes akin to those of sepsis. *Am.J.Obstet Gynecol*, **179**, 80-86.
- Sadler, T.W.,** 2000. *Langman's Medical Embryology*. 8th ed. USA: Lippincot Williams & Wilkins.
- Safer, J.D., Crawford, T.M. and Holick, M.F.,** 2004. A Role for Thyroid Hormone in Wound Healing through Keratin Gene Expression. *Endocrinology*, **145**, 2357-2361.
- Sargent, I.,** 2008. The fundamentals of reproduction, Bartho, J.S., Chaouat, G and Joseph-Mathieu, P., ed. In: *Molecular Mechanism of Implantation: proceedings of the*

*second EMBIC summer school. Second EMBIC handbook, Vol 1, July 1st-4th, 2006*  
2008, Inserm Transfert, France. pp287.

**Sargent, I.L., Germain, S.J., Sacks, G.P., Kumar, S. and Redman, C.W.G., 2003.**  
Trophoblast deportation and the maternal inflammatory response in pre-eclampsia.  
*Journal of Reproductive Immunology*, **59**, 153-160.

**Schaafsma, H.E., Van der Velden, L-A., Manni, J.J., Peters, H., Link, M., Ruiter, D.J. and Ramaekers, F.C.S., 1993.** Increased expression of cytokeratin 8, 18 and vimentin in the invasion front of mucosal squamous cell carcinoma. *J. Pathol*, **170**, 77-86.

**Schaafsma, H., Ramaekers, F., vanMuijen, G., Lane, E., Leigh, I., Robben, H., Huijsmans, A., Ooms, E. and Ruiter, D., 1990.** Distribution of cytokeratin polypeptides in human transitional cell carcinomas, with special emphasis on changing expression patterns during tumor progression. *Am J Pathol*, **136**, 329-343.

**Schermer, A., Galvin, S. and Sun, T-T., 1986.** Differentiation-related expression of major 64K corneal keratin in vivo and in culture suggest limbal location of corneal epithelial stem cells. *J.Cell Biol*, **103**, 49-62.

**Schmaier, A.H., 1998.** Plasma contact activation: A revised hypothesis. *Bio Res.*, **31**, 251-256.

**Schmidt, A., Heid, H.W., Schafer, S., Nuber, U.A., Zimbelmann, R. and Franke, W.W., 1994.** Desmosomes and cytoskeletal architecture in epithelial differentiation: cell type -specific plaque components and intermediate filament anchorage. *Eur.J.Cell Biol*, **65**, 229-245.

- Schrocksnadel, H., Daxenbichler, G., Artner, E., Stecke Berger, G and Dapunt, O.,** 1993. Tumor marker in hypertensive disorders of pregnancy. *Gynecol Invest*, **35**, 204-208.
- Schweizer, J., Bowden, P.E., Coulombe, P.A., Langbein, L., Lane, B.E., Magin, M.T., Maltais, L., Omary, B.M., Parry, D.A.D., Rogers, M.A and Wright, M.W.,** 2006. New consensus nomenclature for mammalian keratins. *J.Cell Biol*, **174**, 169-174.
- Scott, J.A.,** 1984. The role of cytoskeletal integrity in cellular transformation. *J.Theor.Biol.*, **106**, 183-188.
- Seligman, S.P., Buyon, J.P., Clancy, R.M., Young, B.K. and Abramson, S.B.,** 1994. The role of nitric oxide in the pathogenesis of preeclampsia. *Am J.Obstet. Gynecol.*, **171**, 944-948.
- Semat, A., Duprey, P., Vasseur, M. and Darmon, M.,** 1986. Mesenchymal-epithelial conversions induced by 5-Azacytidine: Appearance of cytokeratin Endo-A messenger RNA. *Differentiation*, **31**, 61-66.
- Sevene, E., Lewin, S., Mariano, A., Woelk, G., Oxman, A., Matinhure, S., Cliff, J., Fernandes, B. and Daniels, K.,** 2005. System and market failures: the unavailability of magnesium sulphate for the treatment of eclampsia and pre-eclampsia in Mozambique and Zimbabwe. *BMJ*, **331**, 765-769.
- Shariat-Madar, Z., Mahdi, F. and Schmaier, A.H.,** 1999. Mapping binding domains of kinisogens on endothelial cell cytokeratin 1. *J. Biol Chem*, **274**, 7137-7145.
- Sheppard, C.J.R. and Shotton, D.M,** 1997. *Confocal Laser Scanning Microscopy*. Oxford, UK.: BIOS Scientific Publishers Ltd.

- Shih, I-M. and Kumar, R.J.**, 2002. Molecular basis of gestational trophoblast diseases. *Curr. Mol Med*, **2**, 1-12.
- Shih, I-M. and Kumar, R.J.**, 1998. Epithelioid trophoblast tumour- A neoplasm distinct from choriocarcinoma and placenta site trophoblast tumour simulating carcinoma. *Am. J. Surg Pathol*, **22**, 1393-1403.
- Shih, I-M., Mazur, M.T., and Kurman, R.J.**, ed, 1999a. *Gestational trophoblast disease. In: Diagnostic surgical pathology*. New York: Lippincott Williams & Wilkins.
- Shih, I-M., Seidman, J.D., and Kurman, R.J.**, 1999b. Placenta site node and characterization of distinct types of intermediate trophoblast. *Hum. Pathol.*, **30**, 678-694.
- Shimokawa, H.**, 1999. Primary endothelial dysfunction: Atherosclerosis. *J. Moll cell cardiol*, **31**, 23-37.
- Shotton, D.M.**, 1988. The current renaissance in light microscopy II. Blur-free optical sectioning of biological specimens by confocal scanning fluorescence microscopy. *Proc. R. Microscop. Soc.*, **23**, 289-297.
- Skjaerven, R., Wilcox, A.J. and Lie, R.T.**, 2002. The interval between pregnancies and the risk of preeclampsia. *N. Engl. J Med.*, **346**, 33-3.
- Slotkin, T.A.**, 1998. Fetal nicotine or cocaine exposure: which one is worse? *J. Pharmacol Exp. Ther.*, **285**, 931-945.
- Smarason, A.K., Sargent, I.L., Starkey, P.M. and Redman, C.W.G.**, 1993. The effect of placental syncytiotrophoblast microvillous membrane from normal and pre-eclamptic women on the growth of endothelial cells in vitro. *Br. J. Obstet Gynaecol*, **100**, 943-949.
- Smith, E.A. and Fuchs, E.**, 1998. Defining the interactions between intermediate filaments and desmosomes. *J. Cell Biol*, **141**, 1229-1241.

- Smith, R.K., Ockleford, C.D., Byrne, S., Bosio, P. and Sanders, R.,** 2004. Healthy and pre-eclamptic placental basal plate lining cells: quantitative comparisons based on confocal laser scanning microscopy. *Microscopy Research & Technique*, **64**, 54-62.
- Speer, P., Adair, C.D., and Wang, Y.,** 2000. Effect of nicotine on leukocyte adhesion to uterine vasculature in pregnant rabbits as assessed by in vivo intravital microscopy. *Am.J.Obstet Gynecol*, **182** [suppl], S90.
- Speer, P., Zhang, Y., Gu, Y., Lucas M.J., and Wang, Y.,** 2002. Effect of nicotine on intracellular adhesion molecule expression in endothelial cells and integrin expression in neutrophils in vitro. *Am.J.Obstet Gynecol*, **186**, 551-556.
- Stahelin, L.A.,** 1974. Structure and function of intercellular junctions. *Int. Rev Cytol*, **39**, 191-283.
- Standly, J.R.,** 1989. Pemphigus and pemphigoid as paradigms of organ-specific, autoantibody-mediated diseases. *J. Clin. Invest.*, **83**, 14431-14448.
- Stasiak, P.C., Purkis, P.E., Leigh, I.M. and Lane, E.B.,** 1989. Keratin 19: predicted amino acid sequence and broad tissue distribution suggest it evolves from keratinocyte keratins. *J. Invest. Dermatol*, **92**, 707-716.
- Steiner, P.M. and Roop, D.R.,** 1988. The molecular and cellular biology of intermediate filament. *Ann. Rev. Biochem*, **57**, 593-625.
- Stone, J.L., Lockwood, C.J., Berkowitz, G.S., Alvarez, M., Lapinski, R and Berkowitz, R.L.,** 1994. Risk factors for severe pre-eclampsia. *Obstetrics & Gynecology*, **83**, 357-361.



**Stone, S., Pijnenborg, R., Vercruysse, L., Poston, R., Khamashta, M.A., Hunt, B.J. and Poston, L.,** 2006. The Placental Bed in Pregnancies Complicated by Primary Antiphospholipid Syndrome. *Placenta*, **27**, 457-467.

**Suciu, L., Popescu, L.M. and Gherghiceanu, M.,** 2007. Human Placenta: de visu demonstration of interstitial Cajal-like cells. *J. Cell. Mol. Med.*, **11**, 590-597.

**Sun, T.T., Eichner, R., Schermer, A., Cooper, D., Nelson, W.G and Weiss, R.A.,** 1984. Classification of expression and possible mechanisms of evolution of mammalian epithelial keratins: a unifying model. In A.J. Levine, G.F. Vande Woude, W.C. Topp, and J.D. Watson, ed, *Cancer Cells I. The transformed phenotype*. Cold Spring Harbor, New York.: Cold Spring Harbor Laboratory. 169-176.

**Szeverenyi, I., Cassidy, A.J., Chung, C.W., Lee, B.T.K., Common, J.E.A., Ogg, S.C., Chen, H., Sim, S.Y., Goh, W.L.P., Ng, K.W., Simpson, J.A., Chee, L.L., Eng, G.H., Li, B., Lunny, D.P., Chuon, D., Venkatesh, A., Khoo, K.H., McLean, W.H.I., Lim, Y.P., and Lane, E.B.,** 2009. *The human intermediate filament database: comprehensive information on a gene family in many human diseases*. [online]. Available at: <http://www.interfil.org/diseasesTypeInII.php>; <http://www.interfil.org/aboutDB.php> [accessed July/29/ 2008].

**Szeverenyi, I., Cassidy, A.J., Chung, C.W., Lee, B.T.K., Common, J.E.A., Ogg, S.C., Chen, H., Sim, S.Y., Goh, W.L.P., Ng, K.W., Simpson, J.A., Chee, L.L., Eng, G.H., Li, B., Lunny, D.P., Chuon, D., Venkatesh, A., Khoo, K.H., McLean, W.H.I., Lim, Y.P., and Lane, E.B.,** 2008. The Human Intermediate Filament Database: Comprehensive information on a gene family involved in many human diseases. *Human Mutation*, **29**, 351-360.

**Takahashi, K., Paladini, R.D. and Coulombe, P.A.,** 1995. Cloning and characterization of multiple human genes and cDNAs encoding highly related type II keratin 6 isoforms. *J. Biol Chem.*, **270**, 18581-18592.

**Tangrea, M.A., Gillespie, J.W., Flaig, M.J., Gannot, G., Knezevic, V., Emmert-Buck, M.R and Chuaqui, R.F.,** 2005. Methods of Microdissection and New Technologies. In M. R. Emmert-Buck, J. W. Gillespie, R. F. Chuaqui, ed, *Dissecting the Molecular Anatomy of Tissue Principles and practice..* 9TH ed. Berlin Heidelberg: Springer. 69-100.

**Tannetta, D.S., Sargent, I.L., Linton, E.A. and Redman, C.W.G.,** 2008. Vitamins C and E Inhibit Apoptosis of Cultured Human Term Placenta Trophoblast. *Placenta*, **29**, 680-690.

**Taylor, R.N., Crombleholme, W.R., Friedman, S.A., Jones, L.A., Casal, D.C and Roberts, J.M.,** 1991. High plasma cellular fibronectin levels correlate with biochemical and clinical features of pre-eclampsia but cannot be attributed to hypertension alone. *Am.J.Obstet Gynecol*, **165**, 895-901.

**Tempfer, C.B., Bancher-Todesca, D., Zeisler, H., Schatten, C., Husslein, P. and Gregg, A.R.,** 2000. Placental expression and serum concentrations of cytokeratin 19 in preeclampsia. *Obstetrics & Gynecology*, **95**, 677-682.

**Thadhani, R., Mutter, W.P., Wolf, M., Levine, R.J., Taylor, R.N., Sukhatme, V.P., Ecker, J. and Karumanchi, S.A.,** 2004. First trimester placental growth factor and soluble fms-like 1 and risk of pre-eclampsia. *J Clin Endocrinol Metab*, **89**, 770-775.

**The Eclampsia Trial Collaborative Group**, 1995. Which anticonvulsant for women with eclampsia? Evidence from the Collaborative Eclampsia Trial. *The Lancet*, **345**, 1455-1463.

**The Magpie trial collaborative group**, 2002. Do women with pre-eclampsia, and their babies, benefit from magnesium sulphate? The Magpie trial: a randomised placebo-controlled trial. *Lancet*, **359**, 1877-1890.

**Tjoa, M.L., Cindrova-Davies, T., Spasic-Boskovic, O., Bianchi, D.W and Burton, G.J.**, 2006. Trophoblast oxidative stress and the release of cell-free feto- placental DNA. *Am. J. Pathol.*, **169**, 400-404.

**Toal, M., Chan, C., Fallah, S., Alkazaleh, F., Chaddha, V., Windrim, R.C. and Kindom, J.C.**, 2007. Usefulness of a placental profile in high-risk pregnancies. *Am. J. Obstet Gynecol.*, **196**, 363-e1-7.

**Tomic, M., Jiang, C.K., Epstein, H.S., Freedberg, I.M., Samuels, H.H. and Blumenberg, M.**, 1990. Nuclear receptors for retinoic acid and thyroid hormone regulate transcription of keratin genes. *Cell Regul.*, **1**, 965-973.

**Trupin, L.S., Simon, L.P. and Eskenazi, B.**, 1996. Change in paternity: a risk factor for pre-eclampsia in multiparas. *Epidermiology*, **7**, 240-244.

**Tseng, S.C.G., Jarvinen, M.J., Nelson, W.G., Huang, J-W., Woodcock-Mitchell, J. and Sun, T-T.**, 1982. Correlation of specific keratins with different types of epithelial differentiation: monoclonal antibody study. *Cell*, **30**, 361-372.

**Tubbergen, P., Lachmeijer, A.M.A., Althuisius, S.M., Vlak, M.E.J., van Geijn, H.P. and Dekker, G.A.**, 1999. Change in paternity: a risk factor for pre-eclampsia in multiparous women? *J.Reprod.Immunol.*, **45**, 81-88.

- Uotila, J.T., Tuimala, R.J. and Aarnio, T.M.,** 1993. Findings on lipid peroxidation and antioxidant function in hypertensive complications of pregnancy. *Br. J Obstet Gynaecol*, **100**, 270-276.
- Van der ven, K. and Ober, C.,** 1994. HLA-G polymorphisms in African Americans. *J. Immunol*, **153**, 5628-5633.
- Venkatesha, S., Toporsian, M., Lam, C., Hanai, J-I., Mammoto, T., Kim, Y.M., Bdolah, Y., Lim, K-H., Libermann, T.A., Stillman, I.E., Roberts, D., Amore, P.A., Epstein, F.H., Sellke, F.W., Romero, R., Sukhatme, V.P., Letarte, M. and Karumanchi., A.,** 2006. Soluble endoglin contributes to the pathogenesis of preeclampsia. *Nature Medicine*, **12**, 642-649.
- Vicovac, L and Aplin, J.D.,** 1996. Epithelial-mesenchymal transition during trophoblast differentiation. *Acta Anat (Basel).*, **156**, 202-216.
- Vigano, P., Mangioni, S., Pompei, F. and Chiodo, I.,** 2003. Maternal- conceptus Cross Talk- A Review. *Placenta*, **24**, S56-S61.
- von Dadelszen, P., Magee, L.A. and Roberts, J.M.,** 2003. Subclassification of preeclampsia. *Hypertension in pregnancy.*, **22**, 143-148.
- Walker, J.J.,** 2000. Pre-eclampsia. *The Lancet*, **356**, 1260-1265.
- Walsh, S.W and Wang, Y.,** 1995. Trophoblast and placental villous core production of lipid peroxides, thromboxane and prostacyclin in preeclampsia. *J. Clin Endocrinol Metab.*, **80**, 1888-1893.
- Wang, Y. and Walsh, S.W.,** 2001. Increased superoxide generation is associated with decreased superoxide dismutase activity and mRNA expression in placental trophoblast cells in pre-eclampsia. *Placenta*, **22**, 206-212.

**Watson, A.L., Skepper, J.N., Jauniaux, E and Burton, G.J.,** 1998. Changes in concentration, localization and activity of catalase within the human placenta during early gestation. *Placenta*, **19**, 27-34.

**Watson, E.D.,** 2007. 2005 Trophoblast Research Award Lecture: Defects in the Keratin Cytoskeleton Disrupt Normal Murine Placental Development and Trophoblast Cell Function. *Placenta*, **28**, S111-S115.

**Wells, M.J., Hatton, M.W.C., Hewlett, B., Podor, T.J., Sheffield, W.P and Blajchman, M.A.,** 1997. Cytokeratin 18 is expressed on the hepatocyte plasma membrane surface and interacts with thrombin-antithrombin complex. *J.Biol chem.*, **272**, 28574-28581.

**Wilson, B.J., Watson, M.S., Prescott, G.J, Sunderland, S., Campbell, D.M., Hannaford, P and Smith, W.C.,** 2003. Hypertensive diseases of pregnancy and the risk of hypertension and stroke in later life: results from cohort study. *BMJ*, **326**, 845.

**Witlin, A.G. and Sibai, B.M.,** 1998. Magnesium sulphate therapy in pre-eclampsia and eclampsia. *Obstet Gynecol*, **92**, 883-889.

**Wojcik, S.M., Bundman, D.S. and Roop, D.R.,** 2000. Delayed wound healing in keratin 6a knockout mice. *Mol Cell Biol*, **20**, 5248-5255.

**World Health Organization,** 1994. Mother-baby package: Implementing safe motherhood in countries. Geneva: WHO/FHE/MSM/94.11.

**Yamada, S. Wirtz, D. and Coulombe, P.A.,** 2002. Pairwise assembly determines the intrinsic potential for self-organization and mechanical properties of keratin filaments. *Mol. Biol of the Cell*, **13**, 382-391.

**Yanagisawa, M., Kurihara, H., Goto, K. and Masaki, T., 1988b.** A novel peptide vasoconstrictor, endothelin, is produced by vascular endothelium and modulates smooth muscle  $\text{Ca}^{2+}$  channels. *J. Hypertens. Suppl.*, **6**, S188-S191.

**Yanagisawa, M., Kurihara, H., Kimura, S., Tomobe, Y., Kobayashi, M., Mitsui, Y., Yazaki, Y., Goto, K. and Masaki, T., 1988a.** Endothelin: A potent vasoconstrictor peptide produced by vascular endothelial cells. *Nature*, **332**, 411-415.

**Yeh, I.T., O'Connor, D.M. and Kurman, R.J., 1990.** Intermediate trophoblast: further immunocytochemical characterization. *Mod Pathol.*, **3**, 282-287.

**Zatloukal, K., Stumptner, C., Fuchsbichler, A., Fickert, P., Lackner, C., Trauner, M. and Denk, H., 2004.** The keratin cytoskeleton in liver diseases. *J. Pathol*, **204**, 367-376.

**Zhou, Y., Genbacev, O., Damsky, C.H. and Fisher, S.J., 1998.** Oxygen regulates human cytotrophoblast differentiation and invasion in normal pregnancy and preeclampsia. *J Reprod. Immunol*, **39**, 197-213.

**Zhou, Y., Damsky, C.H., Chiu, K., Roberts, J.M. and Fisher, S.J., 1993.** Preeclampsia is associated with abnormal expression of adhesion molecules by invasive cytotrophoblasts. *J.Clin.Invest.*, **91**, 950-960.

## **PATIENT INFORMATION LEAFLET**

**PATIENT INFORMATION LEAFLET,  
VERSION NO 2003CDO1, Tuesday, 25 August 2009  
Study No LGH 9161**

“Study title: Investigation of genetic, cellular and molecular pathological aspects of the intervillous space to clarify the mechanism of the pre- eclamptic materno- fetal interaction. ”

Short title: High blood pressure in pregnancy

Principle Investigators      *Dr Colin Ockleford PhD, FRCPath  
Mr Paul Bosio MD MRCOG  
Mr Jason Waugh MRCOG*

For further information you may contact Dr Ockleford at:-  
*The Advanced Light Microscope Facility  
Maurice Shock Medical Sciences Building  
Leicester Warwick Medical School  
University Road  
Leicester LE1 9HN*

*Tel: 0116 252 3020  
Email: [cxo@le.ac.uk](mailto:cxo@le.ac.uk)*

The study (Leicester Research Ethics Committee ref. No. 6336) of which this is a development was originally sponsored by “The Pathological Society of Great Britain and Ireland”. The work is to be carried out by staff at Leicester Warwick Medical Schools.

*You are being invited to take part in a research study. Before you decide it is important for you to understand why the research is being done and what it will involve. Please take time to read the following information carefully and discuss it with others if you wish. Ask us if there is anything that is not clear or if you would like more information. Take time to decide whether or not you wish to take part.*

### **1. What is the purpose of the study?**

We have recently uncovered new information about the detailed structure of the tissues in the healthy human placenta. The new information relates to a part of the placenta that develops abnormally when pre-eclampsia ensues. We now wish to study this area in detail comparing the normal and pre-eclamptic placentae very carefully to see what

we can learn about the course of the disease. At some future stage this may help us to develop new rational strategies for treatment of the disease.

## **2. What is pre-eclampsia?**

Pre-eclampsia is a disease that can affect pregnant women. In mild cases it causes protein in the urine, swelling of tissues and slightly raised blood pressure. Untreated, the raised blood pressure can have severe effects. In these cases it can lead to eclampsia where the mother has fits and harm can come to her baby. Although the cause is not yet fully understood it is believed to involve placenta tissue as where that is diseased pre-eclampsia is seen earlier in pregnancy. Pre-eclampsia is obviously a disease where progress in understanding, if it leads to new treatments, could be very valuable.

## **3. Why have I been chosen**

You have been chosen either

- a) because you have clinical signs of pre-eclampsia and we would like to examine small samples of placenta after it is delivered for changes associated with the disease. Or alternatively
- b) because your pregnancy is a healthy one and we wish to compare similar small samples of placenta taken after it is delivered so that we can be sure we have a good basis for comparison.

## **4. What will happen to me if I take part in the study?**

- The whole study should be complete within 3 years of the start date in early April 2004
- The number of visits to hospital will not be increased beyond that expected for your normal treatment.
- Any tests to be carried out, e.g. physical examination, blood test etc. on you and your baby will be the normal routine ones for your own and your baby's benefit. In addition we would like you to give permission for use of samples of the placenta. These will be obtained after the delivery of the placenta and baby for careful microscopic and cell-biological study. Subsequently the tissue of the placenta will be disposed of in the approved manner for human tissues. We do not plan to keep any tissue beyond the end of the study this will be at the latest 3 years from your giving consent.
- You will not be asked to keep any records specifically for this study.
- You will not be asked to fill in any questionnaires for the purposes of this study.
- The procedures for our research will all be carried out on the placenta after your baby has been delivered and special research staff will be handling the tissue. We do not therefore envisage any additional risk involved for you or your baby in helping with this research.
- No short-term benefits will accrue to you or your family. We hope and are working hard to try to ensure that there will be long term ones for others and babies affected by this condition in the future.

## **4. Will information obtained in the study be confidential?**



As usual your treatment will be recorded in your medical records and these will be treated with the usual degree of confidentiality under the data protection act. Some relevant excerpts of your notes may be useful as raw research data to members of the research team. The consultant-in-charge of your welfare and that of your baby will arrange to transmit only any necessary information and then using a code number. *Your name and address will be removed so that you cannot be recognised from it.*

You will not be identified in any documents or published work relating to the research.

Normally the patient's GP is informed of the patient participation in a medical study. As this study is of the placenta only we do not intend to do so on this occasion. However should you wish to consult your GP please do so and show them the information you have been given. We will make ourselves available to discuss any issues with your GP if they think it valuable.

#### **5. What if I and/ or my baby are harmed by the study?**

We believe this to be extremely *unlikely* as we are only intending to study the placenta following your baby's birth. Nevertheless the research will be indemnified in the usual way. If you are harmed due to someone's negligence, then you may have grounds for a legal action but you may have to pay for it. Regardless of this, if you wish to complain, or have any concerns about any aspect of the way you have been approached or treated during the course of this study, the normal National Health Service complaints mechanisms are available to you.'

#### **6. Will I receive out of pocket expenses for taking part in the study?**

There will be no out of pocket expenses payment associated with this trial and there should be no additional travel involved. Neither will your doctor be paid for including you in this study; he is doing this in the hope that the work will benefit future patients.

#### **7. Do I have to take part?**

It is up to you to decide whether or not to take part. If you do decide to take part you will be given this information sheet to keep and be asked to sign a consent form. If you decide to take part you are still free to withdraw at any time and without giving a reason. A decision to withdraw at any time, or a decision not to take part, will not affect the standard of care you receive.

#### **8. What will happen to the results of the research study?**

We aim to publish the outcome of our work in peer-reviewed medical and scientific journals that are freely accessible so that they are most useful to the widest range of people. We cannot predict where they will appear, as acceptance for publication is an editorial decision, but this should be within 4 years and if any member of the team is contacted they undertake to indicate to participants where relevant results are to be, or have been published, so they can obtain a copy.

#### **9. Who has reviewed the study?**

All research that involves NHS patients or staff, information from NHS medical records or uses NHS patients or staff, information from NHS medical records or uses NHS

premises or facilities must be approved by a Leicestershire Local Research Ethics Committee before it goes ahead. Approval does not guarantee that you will not come to any harm if you take part. However, approval means that the Committee is satisfied that your rights will be respected, that any risks have been reduced to a minimum and balanced against possible benefits and that you have been given sufficient information on which to make an informed decision to take part or not.

‘Thank you for reading this.’

## *SAMPLE LETTER OF INVITATION*

Date: Tuesday, 25 August 2009

To: The Patient

Dear Patient

**Re:** "Investigation of genetic, cellular and molecular pathological aspects of the intervillous space to clarify the mechanism of the pre- eclamptic materno- fetal interaction."

Short title: High blood pressure in pregnancy

A research study is being carried out at the *Leicester Royal Infirmary* by

Dr Colin Ockleford, Mr Paul Bosio, Jason Waugh and their research teams.

a. The study has been designed to examine details of placental structure that may be important in the disease pre- eclampsia. Patients are being asked for permission to remove tissue samples from their placentae after delivery so that they can be studied.

b. *either:* As you are currently being treated at this hospital for this condition, your responses would be very valuable.

*or :* You *do not* have pre-eclampsia but we still wish to examine tissue samples from your placenta as a healthy comparison organ in our study.

It is hoped that the results of this study will improve our knowledge of pre- eclampsia and so help us to design rational strategies for improved treatments.

If you would like to take part in this study, details of which are given on the information leaflet enclosed, please complete the reply slip enclosed with this letter and return it in the pre-paid envelope. Our research assistant/ associate will then contact you to arrange a convenient time to obtain your consent and explain the project in more detail. Our research assistant/ associate will be supervised by the heads of clinical care in this area- Mr Paul Bosio and Mr Jason Waugh.

Initiation of this line of research followed successful submission of a competitive bid nationally for funding by the Pathological Society of Great Britain and Ireland and following initial successes we aim to develop it with support from appropriate Medical Charities and the Leicester Warwick Medical Schools.

I would like to thank you for taking time to read this letter and hope to hear from you soon. If you have any queries please feel free to contact the research assistant/associate on telephone number 0116 252 3031 or if you prefer to talk to a senior clinician supervising patient contact telephone Mr Paul Bosio on his personal telephone number - see below.

Yours sincerely

*Dr Paul Bosio  
Consultant in Pregnancy Hypertension  
Dept. of Obstetrics and Gynaecology*

*Telephone No: 0116 258 7770*

Centre Number: Research and Development Department, Leicester General Hospital  
9161

Study Number: uhl 9161

Patient Identification Number for this trial:

## CONSENT FORM

**Title of Project:** Study title: Investigation of genetic, cellular and molecular pathological aspects of the intervillous space to clarify the mechanism of the pre-eclamptic materno- fetal interaction.

Short title: High blood pressure in pregnancy

Name of Researchers: **Dr Colin Ockleford PhD FRCPath.**  
**Mr Paul Bosio MD MRCOG**  
**Mr Jason Waugh MRCOG**

*Please initial boxes:*

I confirm that I have read and understand the information sheet dated Friday, 03 August 2003 (version no 2003CDO1) for the above study and have had the opportunity to ask questions. ☐

I understand that my participation is voluntary and that I am free to withdraw at any time, without giving any reason, without my medical care or legal rights being affected. ☐

I understand that sections of any of my medical notes may be looked at by responsible individuals from the Medical School or from regulatory authorities where it is relevant to my taking part in research. I give permission for these individuals to have access to my records and understand that all the information will be treated as confidential. ☐

I understand medical research is covered for mishaps in the same manner as for patients undergoing treatment in the NHS i.e. compensation is only available if negligence occurs. ☐

I agree to take part in the above study and to being contacted by an approved member of the research team. ☐

My Address is: .....

.....

.....

Telephone No: .....Date:.....

_____ Name of Patient	_____ Date	_____ Signature
--------------------------	---------------	--------------------

I confirm I have explained the nature of the Trial, as detailed in the Patient Information Sheet, in terms suited to the understanding of the patient and that the patient will be given a copy of the information sheet and a signed consent form to keep.

_____ Name of Person taking consent (if different from researcher)	_____ Date	_____ Signature
--	---------------	--------------------

_____ Researcher	_____ Date	_____ Signature
---------------------	---------------	--------------------

Copies: 1 for patient; 1 for researcher; 1 to be kept with hospital notes.

Please return in the enclosed pre-paid envelope to:

Dr Colin Ockleford PhD FRCPath.,

Maurice Shock Medical Sciences Building,

Leicester Warwick Medical Schools,

University Road,

Leicester LE1 9HN.

Thank you.