
































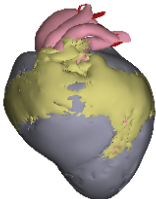



Heart of the adult ostrich

-    lumen
-    pulmonary vein
-    left atrioventricular valve
-    aortic valve
-    pulmonary artery valve
-    myocardium
-    right ventricular free wall
-    muscular flap valve
-    fibro-fatty tissue
-    systemic arteries
-    coronaries
-    pulmonary artery
-    rm



Ventral

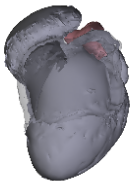

Fig. 14B

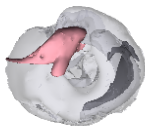


Fig. 14C