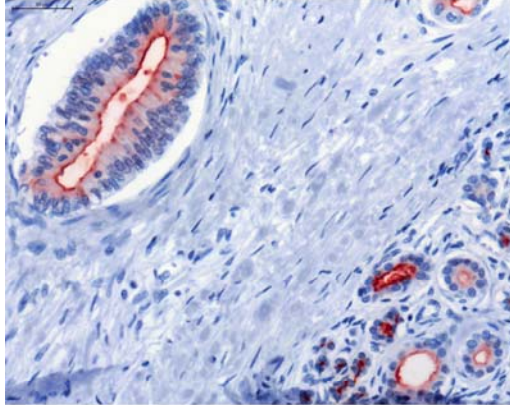
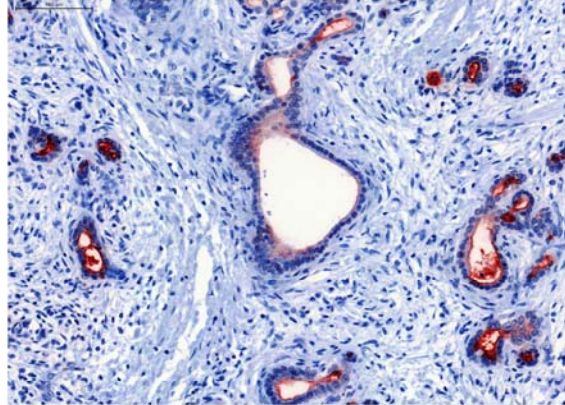


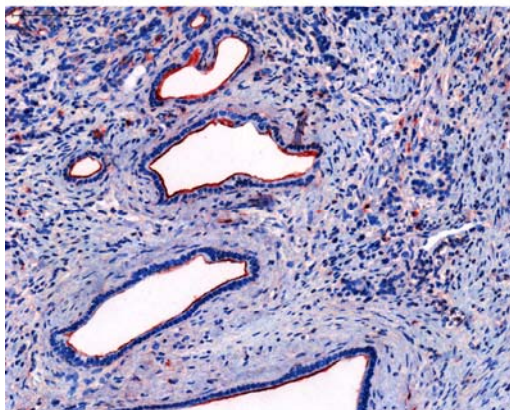
a) Apical staining of CD133



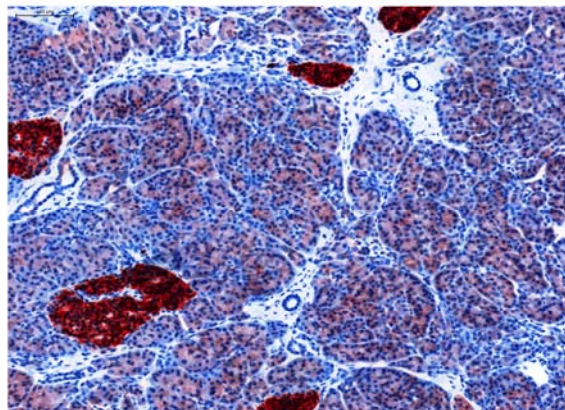
b) Small ducts vs. large ducts in CD133 staining



c) Apical staining of CD44



d) Strong positive islet cells in CD166, CD44 & CD326 staining



Immunohistochemical staining morphologies of pancreatic tissue.