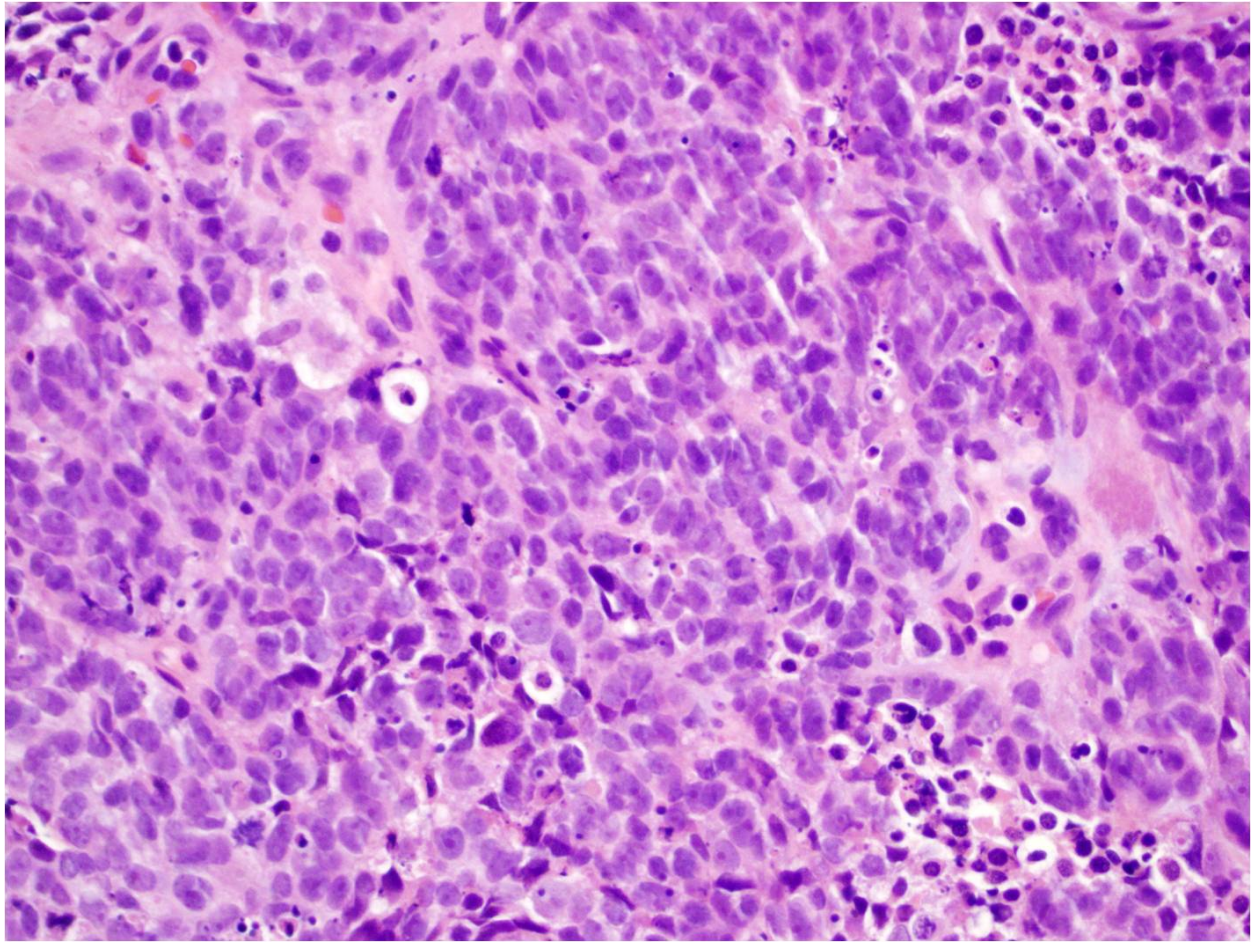


Figure 1- Small Cell Carcinoma of the Urethra



Tumor cells have very little cytoplasm; as a result, they show nuclear crowding and molding. Small cell carcinomas carry a high proliferation rate, as evidenced by frequent mitoses, crush artifact, and geographic necrosis.

Figure 2- Small Cell carcinoma of the Urethra- Tumor cells positive for neuroendocrine marker chromogranin

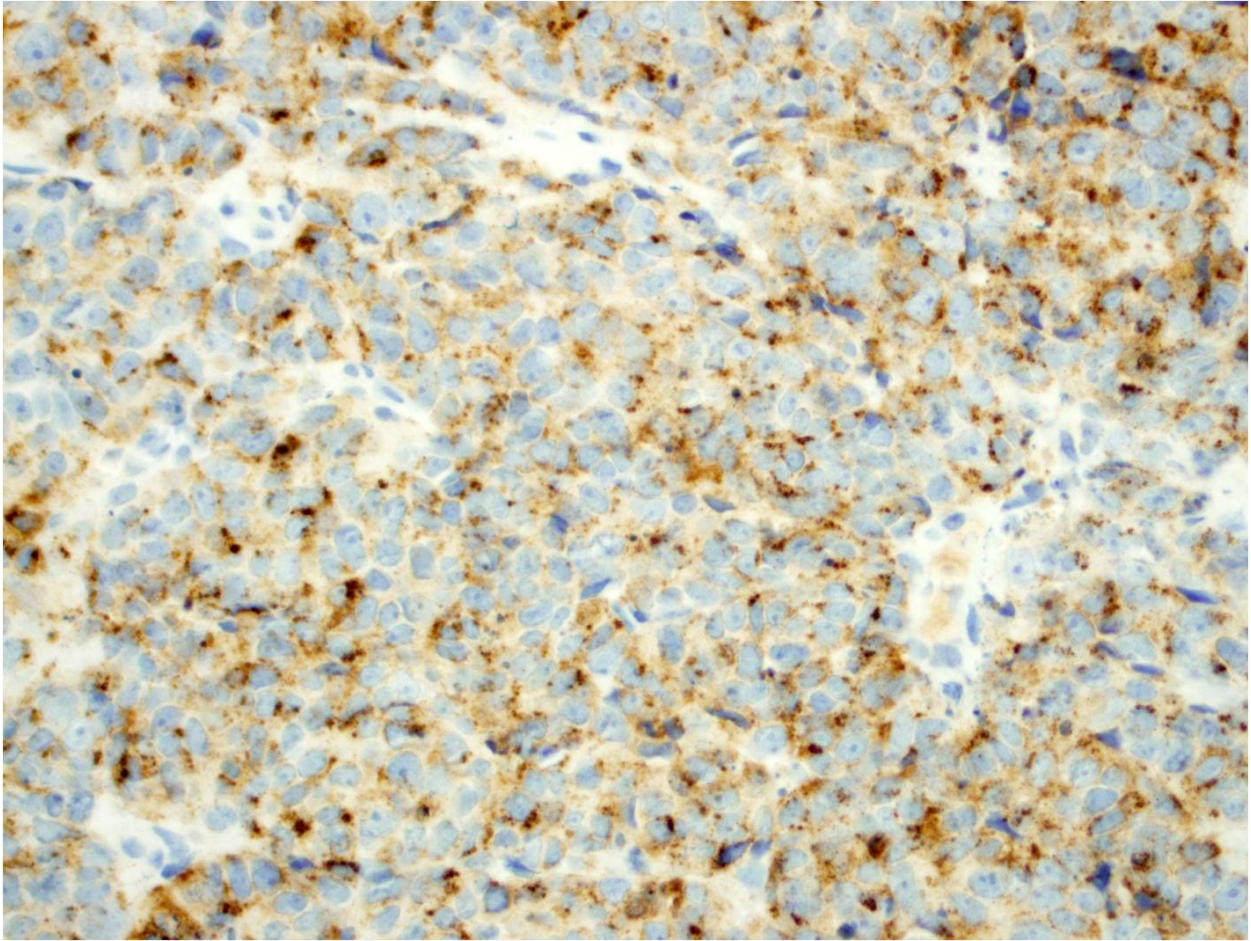




Figure 3- Small Cell Carcinoma of the Urethra-Tumor cells positive for neuroendocrine marker Synaptophysin

