

An Update on the Molecular and Clinical Characteristics of Apocrine Carcinoma of the Breast

Semir Vranic, Zoran Gatalica

Item type

Journal Contribution

Terms of use

This work is licensed under a [CC BY 4.0](https://creativecommons.org/licenses/by/4.0/) license

This version is available at

https://manara.qnl.qa/articles/journal_contribution/An_Update_on_the_Molecular_and_Clinical_Characteristics_of_Apocrine_Carc

Access the item on Manara for more information about usage details and recommended citation.

Posted on Manara – Qatar Research Repository on

2021-12-27

An Update on the Molecular and Clinical Characteristics of Apocrine Carcinoma of the Breast

Semir Vranic,^{1,2} Zoran Gatalica³

Abstract

Apocrine carcinoma of the breast is a rare malignancy. According to 2019 WHO classification, apocrine cellular features and a characteristic steroid receptor profile (Estrogen receptor (ER)-negative and androgen receptor (AR)-positive) define apocrine carcinoma. Her-2/neu protein expression is reported in ~30-50% of apocrine carcinomas, while NGS analysis showed frequent *PIK3CA/PTEN/AKT* and *TP53* mutations followed by deregulation in the mitogen-activated protein kinase pathway components (mutations of *KRAS*, *NRAS*, *BRAF*). A recent miRNA study indicates various miRNAs (downregulated hsa-miR-145-5p and upregulated 14 miRNAs such as hsa-miR-182-5p, hsa-miR-3135b, and hsa-miR-4417) may target the commonly altered pathways in apocrine carcinomas such as ERBB2/HER2 and mitogen-activated protein kinase signaling pathway. Although AR expression is a hallmark of apocrine carcinoma, little is known regarding the efficacy/resistance to antiandrogens. Success of bicalutamide, a non-steroidal anti-androgen, was reported in a case of Her2-negative apocrine carcinoma. Two recent studies, however, described presence of anti-androgen resistance biomarkers (a splice variant ARv7 and *AR/NCOA2* co-amplification) in a subset of AR+ apocrine carcinomas, cautioning the use of anti-androgens in AR+ triple-negative breast carcinomas. Apocrine carcinomas rarely show biomarkers predictive of response to immune checkpoint inhibitors (PD-L1 expression, MSI-H status, and TMB-high). Therefore, a comprehensive cancer profiling of apocrine carcinomas is necessary to identify potential therapeutic targets for a truly individualized treatment approach.

Clinical Breast Cancer, Vol. 22, No. 4, e576–e585 © 2021 The Author(s). Published by Elsevier Inc.

This is an open access article under the CC BY license (<http://creativecommons.org/licenses/by/4.0/>)

Keywords: Breast, Apocrine carcinoma, Androgen receptor, Molecular features, Therapy

Introduction

Breast cancer is the leading malignancy among adult females worldwide, with a high mortality rate that is only preceded by lung cancer.¹ It is a heterogeneous and complex disease encompassing numerous and diverse histologic and molecular genetic types.^{2,3} While invasive breast carcinoma of no special type (NST) constitutes ~70% of all breast malignancies, the remaining 30% include various and rare (special) subtypes, defined by distinct morphology, molecular expressions, and/or genetic features; consequently, clinical course and treatment options vary significantly.³

In the current review, we continue^{4,5} to bring attention to the apocrine breast carcinoma, critically appraise and summarize the recent literature on molecular and clinical studies in the field.

WHO Definition of Apocrine Carcinoma

The 2019 WHO classification of breast tumors recognized apocrine carcinoma as a distinct, special type of breast cancer (under the name "carcinoma with apocrine differentiation").³ It is characterized by a distinct apocrine morphology (described and illustrated in [Figure 1](#)), which must be present in >90% of cancer cells (=essential criteria). As desirable criteria, the WHO proposed a characteristic steroid receptor profile: Estrogen receptor (ER)-negative and androgen receptor (AR)-positive. When strictly defined using the essential and desirable criteria, apocrine carcinoma is a rare breast malignancy, constituting ~1% of all breast cancers.⁶ The WHO classification also proposed a diagnostic algorithm and differential diagnostic approach for breast tumors whose cells exhibit eosinophilic or foamy cytoplasm (Summarized and updated in [Table 1](#)). The diagnosis of apocrine carcinoma can occasionally be challenging due to the overlapping/similar morphology with some

¹ College of Medicine, QU Health, Qatar University, Doha, Qatar

² Biomedical and Pharmaceutical Research Unit, QU Health, Qatar University, Doha, Qatar

³ Department of Pathology, University of Oklahoma Health Sciences Center, Oklahoma City, OK

Submitted: Nov 18, 2021; Revised: Dec 14, 2021; Accepted: Dec 20, 2021; Epub: 27 December 2021

Address for correspondence: Semir Vranic, MD, PhD, College of Medicine, QU Health, Qatar University, PO Box 2713 Doha, Qatar
E-mail contact: svranic@qu.edu.qa

Figure 1 An invasive breast carcinoma composed of nests and sheets of neoplastic cells with abundant, granular eosinophilic cytoplasm, well-defined cell borders, and large nuclei with prominent nucleoli (Hematoxylin and Eosin stain, 20x).

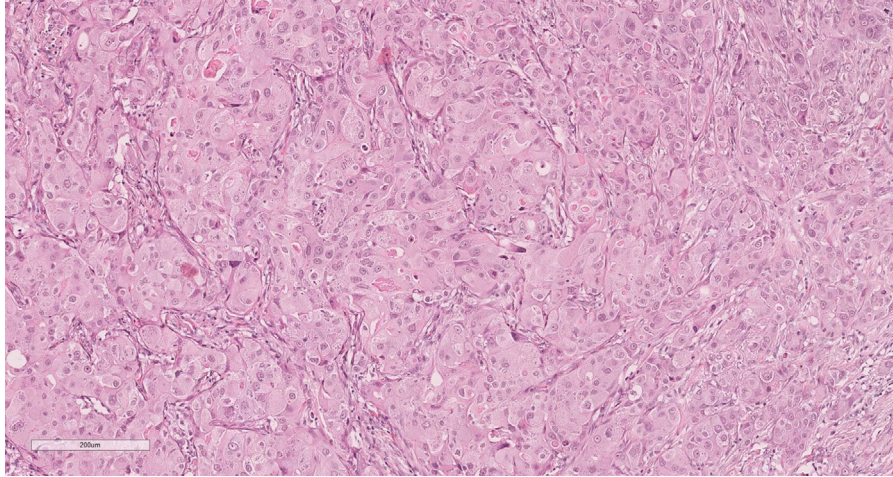


Table 1 Differential Diagnosis Between Apocrine Carcinoma and Other Breast Tumors With Similar Morphology^a

Diagnosis	Frequency	Morphology	CK Status	GCDFP-15	Steroid Receptors	HER-2/neu	S-100	CD68	Additional Biomarkers
Oncocytic carcinoma	Very rare	Abundant, brightly eosinophilic cytoplasm with well-defined borders, large nuclei with prominent nucleoli	+	-/+	ER+/AR-/+	Positive (25%)	-	-	Mitochondrial stains positive
Apocrine carcinoma	~1%	Abundant, granular eosinophilic cytoplasm with well-defined borders, large nuclei with prominent nucleoli	+	+	ER-/AR+	Positive (30-60%)	-	-	GATA3+AMACR+
Granular cell tumor	Very rare	Abundant granular cytoplasm without atypia	-	-	ER-/AR-	-	+	+	None
Histiocytic proliferation	Very rare	Pale or foamy cells without prominent atypia	-	-	ER-/AR-	-	-/+	+	None

Abbreviations: AMACR = α -Methylacyl-CoA racemase; AR = Androgen receptor; CK = Cytokeratin; ER = Estrogen receptor; GCDFP-15 = Gross cystic disease fluid protein 15.

^a Adopted and updated from.⁶

other, even rarer neoplasms, such as oncocytic carcinomas. However, the combination of morphology and specific immunohistochemical biomarkers (eg, mitochondrial stains) can be helpful in such difficult cases (Table 1). Other differential diagnoses (eg, granular cell tumors, histiocytic lesions) can also be ruled out using simple immunohistochemical algorithms (Table 1).

We believe that this approach will substantially improve the diagnosis of apocrine carcinoma, which has been a subject of discussion and controversy for a long time. The lack of clearly defined diagnostic criteria has also contributed to the contradictory and

inconsistent data in the published literature, including diagnostics, clinical presentation, and outcome of the patients with apocrine carcinoma (please refer to the paragraphs on molecular and clinical characteristics, the results of these studies are summarized in Tables 2 and 3). A distinct "molecular apocrine carcinoma/tumor/" subtype was defined based on the analysis of the gene expression data and is characterized by the consistent AR activity and the lack of ER activity (with or without HER2 activity).⁷ Gene expression studies also revealed that these tumors exhibit predominantly luminal features (eg, expression of luminal cytokeratins and the

Apocrine carcinoma of the breast

Table 2 Overview of the Recent (≥ 2018) Molecular Studies and Novel Biomarkers Described in Apocrine Carcinoma of the Breast

Author (year)	Biomarker (molecular pathway) in Apocrine Carcinoma	Clinical Relevance
Gatalica-Vranic (unpublished data)	AMACR positive in 100% apocrine lesions, including apocrine carcinomas	Diagnostic utility; the study also revealed AMACR expression in non-apocrine lesions of the breast
Ferguson et al (2021) ³¹	ARv7 identified in 19/196 AR+ triple-negative breast carcinomas; 8/19 ARv7+ cases exhibited apocrine features	Resistance to anti-AR therapies (eg, bicalutamide, enzalutamide)
Nakamura et al (2021) ³⁴	AMACR positive in 97% apocrine carcinomas	Diagnostic biomarker
Cremonini et al (2021) ²⁵	AR gene copy loss (AR monosomy) in AR+ apocrine carcinomas	High transcriptional activity of the AR gene with a potential of antiandrogen therapy
Boissière-Michot et al (2021) ⁵¹	Low CXCR2 and CD11b expression in molecular apocrine carcinomas (AR+ and FOXA1+); low PD-L1 and TIL	Poor response to immunotherapy
Kolecikova et al (2021) ⁴²	Specific miRNA profile: Downregulated: hsa-miRNA-143-3p, hsa-miRNA-145-5p, hsa-miRNA-182-5p, hsa-miRNA-3135b, hsa-miRNA-4417, and hsa-miRNA-205-5p Upregulated: hsa-miR-22-3p, hsa-miRNA-185-5p, and hsa-miR-4443	These miRNAs affect Wnt, MAPK, and Erb/HER2 signaling A potential role in EMT
Lehmann et al (2020) ³³	FGFR2 fusions NF1 gene mutations AR+ carcinomas had co-amplification of AR and NCOA2 and/or ARv7 variant	Limited response to AR and PIK3CA inhibitors
Vranic et al (2020) ⁴³	PTEN and HRAS mutations in apocrine DCIS with progression to spindle cell metaplastic carcinoma with the same mutations; EMT was supported by the loss of E-cadherin (CDH1 gene wild type) and nuclear Beta-catenin expression in invasive component; Loss of AR expression in the invasive component	
Sun et al (2020) ⁵⁰	Mutational profile: PIK3CA (72%), PTEN (33%), TP53 (28%) Cell cycle regulators (50%) MAPK regulators (44%) FGFR alterations (17%)	94% of triple-negative apocrine carcinomas had at least one actionable genomic alteration (PIK3CA/mTOR inhibitors, CDK4/6 inhibitors, RAS/RAF/MEK inhibitors)
Shousha et al (2020) ⁴⁰	Strong expression of claudins 1 and 3 and the lack of claudin 4 expression	Potential diagnostic biomarkers
Liu et al (2018) ⁷¹	EGFR positive in 86.5% "molecular apocrine cases" (ER-/PR-/AR+) 32% co-expressed EGFR and HER2 EGFR negatively affected the prognosis; correlated with AR and higher Ki-67	EGFR as a potential therapeutic target
Liu et al (2018) ⁷²	HSP27 is involved in AR signaling in the MDA-MB-453 cell line	Potential for HSP27 inhibitors ⁷³
I-O Biomarkers in Apocrine Carcinoma		
Author (year)	Biomarker(s)	Response to immune checkpoint inhibitors
Boissière-Michot et al (2021) ⁵¹	Low PD-L1, low TIL, and low CD8+ and CD3+ lymphocytes in molecular apocrine carcinomas (AR+ and FOXA1+)	Poor response
Dusenbery et al (2021) ⁵²	MHC class I loss in 78% triple-negative apocrine carcinomas PD-L1 positivity in 4/10 (40%) of cases	Resistance to the therapy (MHC class I loss in ~50% PD-L1+ cases) % of PD-L1 positivity: 1-25%
Sun et al (2020) ⁵⁰	Low TMB (mean: 3 mutations/Mb) MSS (100%) PD-L1 positivity (~12%)	Poor response

Abbreviations: AMACR = α -Methylacyl-CoA racemase; AR = Androgen receptor; ARv7 = Androgen receptor splice variant 7; DCIS = ductal carcinoma in situ; EGFR = epidermal growth factor receptor; EMT = epithelial-mesenchymal transition; ER = Estrogen receptor; FOXA1 = Forkhead Box A1; HSP 27 = Heat shock protein 27; I-O = Immuno-Oncology; Mb = Megabase; MHC class I = major histocompatibility complex class I; MSS = microsatellite stable; PD-L1 = programmed death-Ligand 1; PR = Progesterone receptor; TIL = Tumor-infiltrating lymphocytes; TMB = tumor mutational burden

lack of basal features) and are therefore called "luminal androgen receptor"/LAR/ tumors.⁷⁻¹⁰ However, molecularly defined apocrine carcinoma does not necessarily correlate with morphologically and immunohistochemically (ER-/AR+) defined apocrine carcinomas with the estimated overlap of ~70% to 80%.⁸ In addition, a vast majority of LAR carcinomas are of triple-negative phenotype while 30% to 60% of morphologically and immunohistochemically defined apocrine carcinomas exhibit ERBB2/HER2 overex-

pression. This was confirmed in a recent study by Bonnefoi et al, who showed the concordance between molecularly and immunohistochemically confirmed apocrine carcinomas to be 88%. They also found that 2/3 of these apocrine carcinomas were HER2 positive.¹¹ These data indicate that apocrine carcinomas are heterogeneous. Even when strictly defined by morphology and immunohistochemistry, two molecular subtypes of apocrine carcinomas exist (HER2-positive and triple-negative). Within both molecular subtypes, a

Table 3 Review of the Recent (≥ 2018) Studies Exploring the Clinical Characteristics, Treatment Response, And Outcome of the Patients With Apocrine Carcinoma of the Breast

Author (year)	Population (Number of Patients)	Molecular Profile of Apocrine Carcinoma	Clinical Outcome (Information)	Additional Relevant Findings
Zhao et al (2021) ⁶³	Not provided	Basal-like HER2 positive with "apocrine metaplasia"	Poorer response to neoadjuvant anti-HER2 therapy compared with non-basal HER2+ carcinomas	Common <i>TP53</i> mutations
Trapani et al (2021) ⁶⁸	Systematic review	Triple negative (AR positive)	No benefit of adjuvant chemotherapy if early-stage (pNo)	Consider antiandrogens
Di Leone et al (2021) ⁷⁴	20 patients	Molecular apocrine (LAR) Triple-negative	Lower response to neoadjuvant therapy	Lower Ki-67 expression
Kumar et al (2021) ⁷⁵	41 patients	Molecular apocrine (LAR) Triple-negative	High rate of lymph node metastasis	AR-positive Lower proliferation rate
Boissière-Michot et al (2021) ⁵¹	114 patients	Molecular apocrine (AR+ and FOXA1+)	Worse outcome compared with non-molecular triple-negative carcinomas	
Saridakis et al (2021) ⁷⁶	2234 patients (SEER)	50% triple-negative 28% HER2+ 22% luminal	Apocrine carcinomas have more aggressive behavior; Triple-negative apocrine have better outcomes compared with TNBC NST	
Honma et al (2021) ⁷⁷	18 patients	Triple-negative	More favorable outcome than TNBC NST	AR-positive (100%)
Sanges et al (2020) ⁷⁸	45 patients (TNBC database)	Triple-negative	Better 5-y survival while overall survival similar to TNBC	AR-positive in 89% High ($\geq 30\%$) Ki-67 (54%)
Lehmann et al (2020) ³³	8 patients	Metastatic triple-negative AR+ (LAR)	Better response to the targeted therapies (AR and PIK3CA inhibitors) compared with non-LAR TNBC	Resistance mechanisms discovered (ARv7 and AR/NCOA2 co-amplification)
Kim et al (2020) ⁷⁹	373 patients (Korean Breast Cancer Society Registry database)	42% HER2+ and Luminal B (HER2+) 28% triple-negative 30% Luminal A and B (high Ki-67)	Similar prognosis to invasive carcinomas NST	
Tzikas et al (2020) ⁶¹	10 patients (Swedish regional cancer registry)	Triple-negative	Not provided	More prevalent among older patients
Sun et al (2020) ⁵⁰	18 patients	Triple-negative	83% disease-specific survival (median follow-up: 76.5 mo)	AR positive 100% Ki-67 $\sim 10\%$ (average)
Han et al (2020) ⁸⁰	675 patients (SEER)	52% triple-negative 18% HER2+ 30% luminal	TN apocrine did worse while luminal apocrine did better compared with matched NST case	
Ilhan et al (2020) ⁸¹	15 patients	67% HER2+ 33% triple-negative	Four patients died (mean follow-up 5 y)	AR positive (100%) GCDFP-15 (60%)
Kubouchi et al (2020) ⁸²	16 patients	Triple-negative	Early-stage cancers have a good prognosis; the response to NEC is related to high ($\geq 50\%$) Ki-67 expression	AR positive (100%) FOXA1 positive (100%) GCDFP-15 (94%) Ki-67 $\geq 50\%$ (12.5%)
Wysocka et al (2020) ⁸³	57 patients	45.5% HER2+ 29% luminal 25.5% triple-negative	Ki-67 had a strong adverse impact on the outcome	AR-positive (86%)
Zhao et al (2020) ⁸⁴	195 patients (SEER)	Triple-negative	Favorable compared with TNBC NST	
Arciero et al (2020) ⁸⁵	566 patients (NCDB)	Triple-negative	Favorable compared with TNBC NST	
Skenderi et al (2020) ⁶²	259 patients (SEER)	HER2-positive (2/3 ER-negative)	A similar outcome of apocrine patients regardless of the ER/PR status	Breast-cancer related deaths were more prevalent in the NST HER2+ cohort
Montagna et al (2020) ⁸⁶	24 patients	Triple-negative	Favorable outcome	The study included early-stage (pT1-2/No) cases with low Ki-67 without chemotherapy Treatment de-escalation proposed

(continued on next page)

Apocrine carcinoma of the breast

Table 3 (continued)

Author (year)	Population (Number of Patients)	Molecular Profile of Apocrine Carcinoma	Clinical Outcome (Information)	Additional Relevant Findings
Wu et al (2019) ⁸⁷	366 patients (SEER)	Triple-negative	Favorable compared with TNBC NST	
Bonnefoi et al (2019) ¹¹	93 patients (EORTC10994 cohort)	Molecular apocrine HER2+ (67%)	Poor prognosis (59% 5-y recurrence-free survival)	TP53 mutation (72%) 88% concordance between IHC and gene expression data
Dieci et al (2019) ⁶⁰	8 patients	Triple-negative	Worse outcome compared with TNBC NST	AR-positive (87.5%)
Meattini et al (2018) ⁸⁸	46 patients	Triple-negative	Favorable compared with TNBC NST	All cases were centrally reviewed and diagnoses confirmed; Apocrine carcinomas had significantly lower Ki-67 than matched NST cases
Imamovic et al (2018) ⁶⁵	62 patients	33 pure apocrine carcinomas HER2+ (77%)	Favorable (70% five y survival)	17 patients treated with neoadjuvant therapy: four achieved pCR All pure apocrine carcinomas were AR+
Zhao et al (2018) ⁸⁴	195 patients (SEER)	Triple-negative	Better prognosis compared with TNBC NST	
Astvatsuryan et al (2018) ⁸⁹	17 patients	Triple-negative	Similar to TNBC NST	AR-positive (76%) Lower proliferation rate
Echavarría et al (2018) ⁶⁷	14 patients	Triple-negative (LAR) 3/14 basal (PAM50 classifier)	Not reported	The lowest (21%) response to neoadjuvant chemotherapy among TNBC The lowest Ki-67 (median 40%)
Santonja et al (2018) ⁶⁶	14 patients	Triple-negative (LAR) 5/14 basal (PAM50 classifier)	Not reported	The lowest (14%) response to neoadjuvant chemotherapy among TNBC The lowest Ki-67 (71% had <50%)
Liao et al (2018) ⁹⁰	199 patients (SEER)	Triple-negative	Better prognosis compared with TNBC NST	
Liu et al (2018) ⁷¹	200 patients	Molecular apocrine carcinomas (ER-/PR-/AR+)	Carcinomas with EGFR and EGFR/HER2 (co)expression had a worse outcome	EGFR positive in 86.5%
Mills et al (2018) ⁹¹	1486 patients (NCDB)	50% triple-negative	Better prognosis compared with TNBC NST	

Abbreviations: AR = androgen receptor; EGFR = epidermal growth factor receptor; ER = estrogen receptor; FOXA1 = Forkhead Box A1; GCDP-15 = Gross cystic disease fluid protein 15; IHC = immunohistochemistry; LAR = luminal androgen receptor; NCDB = national cancer center database; NEC = neoadjuvant chemotherapy; NST = no special type; pCR = pathologic complete response; PR = progesterone receptor; SEER = surveillance, epidemiology and end results program; TNBC = triple-negative breast cancer

small proportion of cases may show basal phenotype (eg, expression of basal cytokeratins and/or EGFR).

It is still a common practice to diagnose apocrine carcinomas by their morphologic features. Given the recent recommendations from the WHO Classification of Breast Tumors,⁶ we advise the practicing pathologists to adopt a new diagnostic algorithm, which combines a steroid receptor profile and the characteristic apocrine morphology. We believe that this approach will improve diagnostic accuracy and consistency in reporting of apocrine carcinomas and ultimately contribute to a better clinical characterization of this peculiar mammary malignancy.

Novel Molecular Characteristics and Biomarkers of Apocrine Carcinoma

The results of the recent molecular studies on apocrine carcinoma are summarized in Table 2.

AR expression is a characteristic, diagnostic hallmark of apocrine carcinoma but itself is not specific, as AR is expressed in a variety of breast carcinomas, both ER-positive (70%-90%) and ER-negative (20%-40%).¹²⁻¹⁴ Numerous studies have also explored the prognostic value of AR expression in breast cancer.^{12,14-17} Although earlier studies revealed promising therapeutic effects of antiandrogens in

AR+ breast carcinomas, including apocrine tumors,^{18,19} two recent studies,^{20,21} showed low to modest therapeutic benefits of antiandrogens in a mixed group of AR+ breast carcinomas. Both studies included ER-positive and ER-negative AR-positive breast carcinomas with a pretreatment assessment of the AR positivity. Furthermore, other important biomarkers, including those involved in a potential anti-AR resistance, have not been explored. Other clinical trials with anti-AR are explored in more detail in a recent review of Cipriano et al.²²

Genetic studies on the AR gene are rarely reported. A pivotal study by Kasami et al²³ explored the CAG repeat number of the AR gene in a cohort of fibroadenomas, DCIS, and invasive breast carcinomas. The authors found the highest CAG repeats in DCIS, particularly in DCIS with apocrine differentiation.²³ A study by Lee et al exploring the CAG polymorphisms of the AR gene revealed no association with the development of breast cancer, but patients with more (23+) CAG repeats of the AR gene had a poor prognosis.²⁴ Farmer et al found no significant differences in CAG repeats between molecular apocrine carcinomas (17-19) and basal (18) and luminal (20) subtypes.⁷ Cremonini et al recently reported a small (n = 20), well-defined apocrine cohort exploring the status of the AR gene. They found AR loss (monosomy) in most of the tested cases, along with the retained transcriptional activity of several AR regulatory genes, including the MAGE family, UXT, and FLNA genes.²⁵ Based on these findings, the authors speculated that the patients with apocrine carcinoma might benefit from androgen-deprivation therapy, but this requires a clinical validation. Androgen receptor variant 7 (ARv7), a splice variant of AR, is another essential biomarker closely related to anti-AR effectiveness (resistance) as confirmed in prostate carcinoma,²⁶ as well as in salivary duct carcinoma, which shares many morphologic and molecular similarities with apocrine breast carcinoma.^{27,28} The AR-V7 encodes a truncated AR protein that possesses only the transactivating N-terminal domain without the C-terminal ligand-binding domain, resulting in constitutive activation of AR.²⁹ Similar effects have been shown in breast cancer. Thus, ARv7 variants might induce proliferation of the apocrine cell line MDA-MB-453 in the presence of antiandrogen enzalutamide.³⁰ ARv7 was recently described in a cohort of primary and metastatic breast cancers.³¹ The overall frequency was ~10% but was significantly higher (42%) in AR+ carcinomas with apocrine morphology. Notably, ARv7 was also detected in primary, therapy-naïve breast carcinomas (without previous exposure to anti-androgens), indicating a potentially different mechanism of ARv7 activation in the breast compared with prostate carcinomas, but similar to the findings of ARv7 in salivary duct carcinomas.²⁸ The authors proposed routine ARv7 testing for all patients with AR-positive apocrine tumors that are being considered for the treatment with AR inhibitors.³¹ Interestingly, ARv7 and co-amplification of AR and the nuclear co-receptor NCOA2, both of which are associated with anti-AR resistance in prostate cancer,³² have been recently reported in a phase Ib/II clinical trial with AR-positive TNBC.³³ ARv7 was also identified among the non-responders to antiandrogens, indicating its role in the resistance to the therapy. Although LAR patients had better therapeutic response to the combined AR/PIK3CA inhibition than non-LAR TNBC patients, overall therapeutic benefit was limited.³³ This

study is one of the properly designed clinical trials that included a comprehensive molecular assessment prior and after the targeted treatments. Owing to such a design, the authors were able to identify biomarkers of response and resistance.

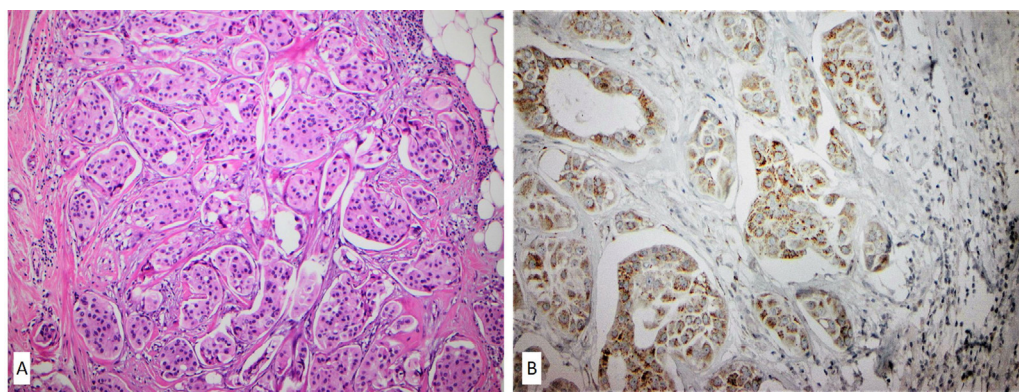
Gross cystic disease fluid protein 15 (GCDFP-15 or PIP-3), along with AR expression, has been considered a biomarker of apocrine differentiation in the breast.⁶ Nakamura et al recently reported that α -Methylacyl-CoA racemase (AMACR) is expressed with a marked preponderance in apocrine breast carcinomas (both in situ and invasive). AMACR has been a biomarker of prostate and several other cancers (eg, papillary renal cell carcinoma, urothelial carcinoma in situ).^{34,35} They found that AMACR was expressed in 96% of apocrine ductal carcinoma in situ (DCIS) cases and 97% of invasive apocrine carcinomas, in contrast to non-apocrine carcinomas that exhibited AMACR positivity in only 22% of the cases. The study revealed a comparable sensitivity of AMACR with GCDFP-15 for apocrine carcinomas, whereas the AMACR specificity was significantly higher (78% vs. 32%). Notably, AMACR protein expression correlated well with its mRNA expression.³⁴ The expression of AMACR (Figure 2) raises an interesting possibility of the role of diet and the interplay with the hormonal status and apocrine breast carcinomas. High animal fat consumption is associated with an increase in triple-negative breast cancer (TNBC) risk in premenopausal women.³⁶

Epithelial-to-Mesenchymal Transition (EMT) in Apocrine Carcinoma

Epithelial-mesenchymal transition (EMT) is one of the hallmarks of cancer progression³⁷. The claudins are transmembrane proteins that regulate the tight junctions between epithelial cells and are involved in signaling between the epithelial cells and their environment³⁸ and are also involved in EMT.³⁷ Previous studies showed that claudins 1, 3, and 4 are consistently expressed in normal mammary epithelium.³⁹ In contrast, apocrine cells within apocrine metaplasia were positive for claudin 1 and consistently negative for claudin 4.³⁹ Sousha et al recently demonstrated claudin 1 and claudin 3 expressions and the lack of claudin 4 protein expression in a small cohort of apocrine lesions, including invasive apocrine carcinoma with the triple-negative phenotype.⁴⁰ The diagnostic and potential therapeutic utility of these findings remains unknown.

MicroRNAs (miRNAs) represent small non-coding RNAs that act as post-transcriptional regulators of various cellular functions. miRNAs negatively regulate gene expression by their binding to their selective messenger RNAs (mRNAs), causing either mRNA degradation or translational repression, depending on their complementarity with target mRNA sequences.⁴¹ miRNAs have been extensively characterized in various cancers, including breast cancer. Recently, Kolecckova et al⁴² demonstrated that triple-negative breast carcinomas with apocrine and spindle cell (metaplastic) morphology exhibited a distinct miRNA profile compared with other breast cancers. In particular, they showed the downregulation of hsa-miRNA-143-3p and hsa-miRNA-205-5p and upregulation of the hsa-miR-22-3p, hsa-miRNA-185-5p, and hsa-miR-4443 (Table 2). Apocrine carcinomas also had decreased expression of hsa-miR-145-5p and increased expression of additional 14 miRNAs, including hsa-miR-182-5p, hsa-miR-3135b, and hsa-miR-4417. The pathway

Figure 2 A case of apocrine carcinoma with micropapillary growth pattern (A) exhibiting diffuse expression of α -Methylacyl-CoA racemase (AMACR) protein by immunohistochemistry (B).



analysis revealed that these miRNAs closely interfere with several important signaling pathways, such as Wnt, ErbB/HER2, and MAPK pathways; the authors also speculated that these miRNAs might contribute to EMT in special types of TNBC – apocrine and spindle cell (metaplastic) carcinomas, concluding that further mechanistic studies are essential to confirm their observations.⁴² Notably, we also demonstrated the active EMT in a case of morphologically apocrine DCIS (AR+) harboring *PTEN* and *HRAS* mutations with progression to spindle cell metaplastic carcinoma that had the same mutational profile and a loss of AR expression.⁴³ EMT was supported by the loss of E-cadherin protein (without *CDH1* gene mutations or loss) and nuclear β -catenin expression in invasive spindle cell component.⁴³ Further studies are required to elucidate the EMT in apocrine carcinomas and its clinical relevance (therapy response and resistance).

The recent studies indicate that EMT might be actively involved in the pathogenesis of apocrine carcinomas via several molecular mechanisms. However, these studies do not reflect the full spectrum of signaling pathways that are involved in EMT in apocrine tumors.^{44,45} Also, the clinical relevance of the observed alterations in apocrine carcinomas should be confirmed.

Immune Checkpoint Inhibitors in Apocrine Carcinoma

Immune checkpoint inhibitors (ICI) have markedly improved the treatment options and outcome of various solid and hematologic malignancies, including triple-negative breast cancer (TNBC). Thus, FDA approved pembrolizumab in both neoadjuvant and adjuvant settings along with its companion diagnostic test for PD-L1 testing (22c3 pharmDx assay, Agilent Technologies). In contrast, atezolizumab and its CDx SP142 were initially approved in 2019 but were withdrawn in August 2021 from use in TNBC patients.⁴⁶ Most of the clinical trials and randomized studies with ICI have not specifically addressed the role of apocrine morphology among TNBC. In addition, the response of HER2-positive apocrine carcinomas to ICI remains largely unknown despite the recently published promising therapeutic effects of atezolizumab combined with anti-HER2 drugs on HER2-positive breast carcinomas.⁴⁷

Several predictive biomarkers of response to ICI have been validated, including PD-L1 expression (on cancer, immune cells or both), high tumor mutational burden (TMB-H), and high microsatellite instability status (MSI-H). In TNBC samples, PD-L1 expression (positivity defined as Combined Positive Score [CPS] ≥ 10) detected by immunohistochemistry has been approved as a companion diagnostic (CDx) test for pembrolizumab.⁴⁸ A few earlier studies have specifically explored predictive biomarkers to ICI in apocrine carcinomas (PD-L1), reporting conflicting results.^{5,49} Three recent studies indicate that apocrine carcinomas show low PD-L1 expression in both tumor and immune cells, low tumor mutational burden, and are consistently microsatellite stable (MSS).⁵⁰⁻⁵² Although high TIL is a feature of TNBC,⁵³ the studies reported low TIL in apocrine carcinomas, which along with a low percentage of intratumoral CD8+ and CD3+ lymphocytes, and a loss of MHC class I (including PD-L1+ apocrine cases), make patients with this cancer less likely responsive to ICIs.^{51,52,54}

Other Targetable Biomarkers in Apocrine Carcinoma

Comprehensive molecular profiling aimed at identifying potentially targetable alterations in cancer has become the standard for precision oncology.⁵⁵ Numerous studies have been published on various subtypes of breast cancer, but those exploring molecular features specifically of apocrine carcinoma remain sparse. Sun et al profiled eighteen "pure" triple-negative apocrine carcinomas (apocrine morphology + AR positivity), revealing *PIK3CA* (72%), *PTEN* (33%), and *TP53* (28%) alterations as the most common in apocrine carcinomas.⁵⁰ A proportion of the cases also harbored genetic alterations within the MAPK pathway (*BRAF*, *HRAS*, *KRAS*, *MAP3K1*), cell cycle regulators (*CDKN2A*, *CDKN2B*, *CDK6*), and FGF pathways (*FGFR2* amplification and fusion) (Table 2). Notably, one apocrine case had a well-described *TERT* gene promoter mutation (c.-124C > T), while another had a novel *FGFR2-TACC2* fusion, not previously reported in breast cancer.⁵⁰ The authors concluded that a vast majority of apocrine carcinomas harbored potentially targetable but diverse genomic alterations,

making their detection a requirement for successful personalized medicine approach (eg, PIK3CA/mTOR inhibitors⁵⁰).

Based on the previous data and their own results, Lehmann et al³³ explored anti-AR Enzalutamide combined with PIK3CA inhibitor Taselisib in a small cohort of AR-positive metastatic TNBCs (phase Ib/II study, TBCRC032). Seventeen pretreated patients randomly received enzalutamide with or without taselisib. Although all the patients experienced disease progression at 16 weeks except for one patient with LAR who was on the combined treatment and had not progressed within 18 months when the study was terminated.³³ In addition, the authors found AR expression to be insufficient in predicting the response although the LAR carcinomas had a substantially higher clinical benefit (75%) compared with other TNBC molecular subtypes (12.5%).³³ Further and larger studies should definitely confirm the benefit of such combined targeted therapies in apocrine carcinomas.

The above-described molecular alterations in apocrine carcinomas generally align with the previously published studies.^{5,56-58} Dysregulation of the cell cycle regulators (CDKN2A and B, CDK6) in a subset of apocrine carcinomas indicates a potential for the treatment with CDK4/6 inhibitors, as shown in the study of Asghar et al.⁵⁹ The authors performed comprehensive *in vitro* and *in vivo* experiments using various breast cancer cell lines, including the apocrine MDA-MB-453 cells. They demonstrated that the apocrine cells were highly sensitive to CDK4/6 inhibitors. More importantly and relevant to apocrine carcinomas, CDK4/6 inhibitors exhibited a synergistic effect with PIK3CA inhibitors in *PIK3CA*-mutant cell lines including MDA-MB-453, extending the use of combined treatment with both CDK4/6 and PIK3CA inhibitors.⁵⁹

Taken together, the recent data confirm the relevance of comprehensive molecular profiling in identifying the targetable biomarkers in apocrine carcinomas. Further translational and clinical studies (basket trials) are needed to verify the findings from the cell lines and molecular studies. These could pave new treatment modalities for patients with advanced disease.

Clinical Studies on Apocrine Carcinoma

We systematically reviewed the recent literature (≥ 2018) on apocrine carcinoma exploring PubMed/MEDLINE, Scopus, and Web of Science Core Collection databases, using the following keywords: "Apocrine carcinoma", "carcinoma with apocrine differentiation", "molecular apocrine carcinoma", "luminal androgen receptor carcinoma", and "breast", "clinical characteristics/features", "outcome", and "survival". The studies exploring non-invasive carcinomas (=apocrine DCIS) and benign apocrine lesions (eg, adenosis, metaplasia) were excluded from the analysis and review. Case reports and small case series (< 5 patients) were also excluded.

Our literature search in the databases revealed 32 clinical studies that have been published since 2018 (the studies and their major results are summarized in Table 3). The number of the patients in the studies shows marked differences, varying from small studies involving 8 to 10 patients^{60,61} to a large series (> 1000 patients) retrieved from the publicly available databases such as the Surveillance, Epidemiology, and End of Results (SEER) and National Cancer Center Database (NCDB). Notably, most of the

reported studies focused on the triple-negative apocrine carcinomas, while very few specifically explored HER2-positive apocrine carcinomas.^{11,62,63} Similarly, most studies also reported the clinical outcome (overall- or disease-specific survival) of the patients with apocrine carcinoma alone or compared with the matched NST subgroup.

Consistent with the previous data, our literature survey confirms contradictory results about the response to chemotherapy and clinical outcome of patients with apocrine carcinoma. This is likely to be caused by the inconsistent diagnostic criteria used to define apocrine carcinomas. We believe that the new WHO definition of apocrine carcinoma with diagnostic utilization of essential and desirable criteria will help better define this category and hence identification of clinically useful information.

Very few studies specifically explored the effects of (neo) adjuvant chemotherapy in patients with apocrine carcinoma.⁶³⁻⁶⁸ Several studies clearly pointed the limited response of molecularly defined triple-negative apocrine carcinomas (LAR) to neoadjuvant chemotherapy in comparison with other non-apocrine TNBC.^{66,67} Both studies also reported significantly lower Ki-67 in LAR compared with non-apocrine TNBC, which is in line with previous studies.^{13,57} Zhu et al and Mohammed et al showed that the lack of AR expression in TNBC independently predicted pCR among TNBC patients.^{69,70} In addition, a systematic review of Trapani et al. revealed that triple-negative, AR+ positive apocrine carcinomas had no benefit of adjuvant chemotherapy if treated in the early stage (pN0).⁶⁸ Instead, the authors proposed that antiandrogens should be considered for such patients in the adjuvant setting.⁶⁸ As discussed above, the response to anti-AR may also be limited due to the various resistance mechanisms as shown in a detailed clinical and molecular study by Lehmann et al.³³

Conclusions and Future Directions

Recent advances have contributed to the improved diagnostics of apocrine carcinoma of the breast. These efforts should also reduce the considerable variability and discrepancy in apocrine carcinomas' definition, molecular and clinical characteristics. Novel biomarkers have also been described, but their diagnostic and clinical (predictive and prognostic) utility has to be confirmed. The current evidence indicates that AR-positive breast carcinomas, including apocrine subtype, may have limited clinical benefit of (neo) adjuvant chemotherapy. Apart from the Her-2/neu target, advanced and/or metastatic apocrine carcinomas still have limited targeted treatment options. The role of antiandrogens in apocrine and other AR-positive breast carcinomas also require further research as limited data (small number of studies and small sample size) on the potential mechanisms of response/resistance are currently available. Therefore, a comprehensive genomic cancer profiling of apocrine carcinomas appears to be a promising approach that could reveal potential targets for an individualized therapeutic treatment.

Disclosure

The authors declare no conflict of interest.

Apocrine carcinoma of the breast

Acknowledgments

The Qatar National Library (QNL) funded the publication of this article.

References

1. Siegel RL, Miller KD, Fuchs HE, Jemal A. Cancer Statistics, 2021. *CA Cancer J Clin.* 2021;71:7–33.
2. Cancer Genome Atlas N. Comprehensive molecular portraits of human breast tumours. *Nature.* 2012;490:61–70.
3. Board E. *Breast Tumours. WHO Classification of Tumours.* 2. 5th ed. Lyon: IARC; 2019.
4. Vranic S, Schmitt F, Sapino A, et al. Apocrine carcinoma of the breast: a comprehensive review. *Histol Histopathol.* 2013;28:1393–1409.
5. Vranic S, Feldman R, Gatalica Z. Apocrine carcinoma of the breast: A brief update on the molecular features and targetable biomarkers. *Bosn J Basic Med Sci.* 2017;17:9–11.
6. Provenzano E GZ, Vranic S. *WHO Classification of Tumours: Breast Tumours.* 2. 5th ed. Carcinoma with apocrine differentiation. Lyon: IARC; 2019.
7. Farmer P, Bonnefoi H, Becette V, et al. Identification of molecular apocrine breast tumours by microarray analysis. *Oncogene.* 2005;24:4660–4671.
8. Doane AS, Danso M, Lal P, et al. An estrogen receptor-negative breast cancer subset characterized by a hormonally regulated transcriptional program and response to androgen. *Oncogene.* 2006;25:3994–4008.
9. Lehmann BD, Bauer JA, Chen X, et al. Identification of human triple-negative breast cancer subtypes and preclinical models for selection of targeted therapies. *J Clin Invest.* 2011;121:2750–2767.
10. Lehmann-Che J, Hamy AS, Porcher R, et al. Molecular apocrine breast cancers are aggressive estrogen receptor negative tumors overexpressing either HER2 or GCDFP15. *Breast Cancer Res.* 2013;15:R37.
11. Bonnefoi H, MacGrogan G, Poncet C, et al. Molecular apocrine tumours in EORTC 10994/BIG 1-00 phase III study: pathological response after neoadjuvant chemotherapy and clinical outcomes. *Br J Cancer.* 2019;120:913–921.
12. Salvi S, Bonafè M, Bravaccini S. Androgen receptor in breast cancer: a wolf in sheep's clothing? A lesson from prostate cancer. *Semin Cancer Biol.* 2020;60:132–137.
13. McNamara KM, Yoda T, Miki Y, et al. Androgenic pathway in triple negative invasive ductal tumors: its correlation with tumor cell proliferation. *Cancer Sci.* 2013;104:639–646.
14. Niemeier LA, Dabbs DJ, Beriwal S, Striebel JM, Bhargava R. Androgen receptor in breast cancer: expression in estrogen receptor-positive tumors and in estrogen receptor-negative tumors with apocrine differentiation. *Mod Pathol.* 2010;23:205–212.
15. Park S, Koo J, Park HS, et al. Expression of androgen receptors in primary breast cancer. *Ann Oncol.* 2010;21:488–492.
16. Kensler KH, Regan MM, Heng YJ, et al. Prognostic and predictive value of androgen receptor expression in postmenopausal women with estrogen receptor-positive breast cancer: results from the Breast International Group Trial 1-98. *Breast Cancer Res.* 2019;21:30.
17. Anestis A, Zoi I, Papavassiliou AG, Karamouzis MV. Androgen receptor in breast cancer-clinical and preclinical research insights. *Molecules.* 2020;25:358.
18. Arce-Salinas C, MC Riesco-Martínez, Hanna W, Bedard P, Warner E. Complete response of metastatic androgen receptor-positive breast cancer to bicalutamide: case report and review of the literature. *J Clin Oncol.* 2016;34:e21–e24.
19. Bonnefoi H, Grellety T, Tredan O, et al. A phase II trial of abiraterone acetate plus prednisone in patients with triple-negative androgen receptor positive locally advanced or metastatic breast cancer (UCBG 12-1). *Ann Oncol.* 2016;27:812–818.
20. Boers J, Venema CM, de Vries EFJ, et al. Serial [(18)F]-FDHT-PET to predict bicalutamide efficacy in patients with androgen receptor positive metastatic breast cancer. *Eur J Cancer.* 2021;144:151–161.
21. Lu Q, Xia W, Lee K, et al. Bicalutamide plus aromatase inhibitor in patients with estrogen receptor-positive/androgen receptor-positive advanced breast cancer. *Oncologist.* 2020;25:21–e15.
22. Cipriano E, Mesquita A. Emerging therapeutic drugs in metastatic triple-negative breast cancer. *Breast Cancer (Auckl).* 2021;15.
23. Kasami M, Gobbi H, Dupont WD, Simpson JF, Page DL, Vnencak-Jones CL. Androgen receptor CAG repeat lengths in ductal carcinoma in situ of breast, longest in apocrine variety. *Breast.* 2000;9:23–27.
24. Lee YT, Liu HM, Lee LH, et al. The polymorphism of CAG repeats in the androgen receptor gene and breast cancer mortality. *Cancer Biomark.* 2015;15:815–822.
25. Cremonini A, Saragoni L, Morandi L, et al. Chromosome X aneusomy and androgen receptor gene copy number aberrations in apocrine carcinoma of the breast. *Virchows Arch.* 2021;479:345–354.
26. Antonarakis ES, Lu C, Wang H, et al. AR-V7 and resistance to enzalutamide and abiraterone in prostate cancer. *N Engl J Med.* 2014;371:1028–1038.
27. Dalin MG, Desrichard A, Katabi N, et al. Comprehensive molecular characterization of salivary duct carcinoma reveals actionable targets and similarity to apocrine breast cancer. *Clin Cancer Res.* 2016;22:4623–4633.
28. Gargano SM, Senarathne W, Feldman R, et al. Novel therapeutic targets in salivary duct carcinoma uncovered by comprehensive molecular profiling. *Cancer Med.* 2019;8:7322–7329.
29. Dalin MG, Watson PA, Ho AL, Morris LG. Androgen receptor signaling in salivary gland cancer. *Cancers (Basel).* 2017;9:17.
30. Hickey TE, Irvine CM, Dvinge H, et al. Expression of androgen receptor splice variants in clinical breast cancers. *Oncotarget.* 2015;6:44728–44744.
31. Ferguson DC, Mata DA, Tay TK, et al. Androgen receptor splice variant-7 in breast cancer: clinical and pathologic correlations. *Mod Pathol.* 2021. doi:10.1038/s41379-021-00924-5.
32. Qin J, Lee HJ, Wu SP, et al. Androgen deprivation-induced NCoA2 promotes metastatic and castration-resistant prostate cancer. *J Clin Invest.* 2014;124:5013–5026.
33. Lehmann BD, Abramson VG, Sanders ME, et al. TBCRC 032 IB/II multicenter study: molecular insights to AR antagonist and PI3K inhibitor efficacy in patients with AR(+) metastatic triple-negative breast cancer. *Clin Cancer Res.* 2020;26:2111–2123.
34. Nakamura H, Kukita Y, Kunimasa K, et al. alpha-Methylacyl-CoA racemase: a useful immunohistochemical marker of breast carcinoma with apocrine differentiation. *Hum Pathol.* 2021;116:39–48.
35. Alston ELJ, Zynger DL. Does the addition of AMACR to CK20 help to diagnose challenging cases of urothelial carcinoma in situ? *Diagn Pathol.* 2019;14:91.
36. Yang XR, Chang-Claude J, Goode EL, et al. Associations of breast cancer risk factors with tumor subtypes: a pooled analysis from the Breast Cancer Association Consortium studies. *J Natl Cancer Inst.* 2011;103:250–263.
37. Gowrikumar S, Singh AB, Dhawan P. Role of claudin proteins in regulating cancer stem cells and chemoresistance-potential implication in disease prognosis and therapy. *Int J Mol Sci.* 2019;21(1):53.
38. Kwon MJ. Emerging roles of claudins in human cancer. *Int J Mol Sci.* 2013;14:18148–18180.
39. Tokes AM, Kulka J, Paku S, et al. Claudin-1, -3 and -4 proteins and mRNA expression in benign and malignant breast lesions: a research study. *Breast Cancer Res.* 2005;7:R296–R305.
40. Shousha S, Anscombe O, McFarlane T. All benign and malignant apocrine breast lesions over-express claudin 1 and 3 and are negative for claudin 4. *Pathol Oncol Res.* 2020;26:1073–1078.
41. Loh HY, Norman BP, Lai KS, Rahman N, Alitheen NBM, Osman MA. The regulatory role of MicroRNAs in breast cancer. *Int J Mol Sci.* 2019;20:4940.
42. Koleckova M, Ehrmann J, Bouchal J, et al. Epithelial to mesenchymal transition and microRNA expression are associated with spindle and apocrine cell morphology in triple-negative breast cancer. *Sci Rep.* 2021;11:5145.
43. Vranic S, Stafford P, Palazzo J, et al. Molecular profiling of the metaplastic spindle cell carcinoma of the breast reveals potentially targetable biomarkers. *Clin Breast Cancer.* 2020;20:326–331 e321.
44. Kalluri R. EMT: when epithelial cells decide to become mesenchymal-like cells. *J Clin Invest.* 2009;119:1417–1419.
45. Kalluri R, Weinberg RA. The basics of epithelial-mesenchymal transition. *J Clin Invest.* 2009;119:1420–1428.
46. Genentech Provides Update on Tecentriq U.S. Indication for PD-L1-Positive, Metastatic Triple-Negative Breast Cancer. 2021. <https://www.gene.com/medialpress-releases/14927/2021-08-27/genentech-provides-update-on-tecentriq-u>. Accessed November 11, 2021.
47. Hamilton EP, Kaklamani V, Falkson C, et al. Impact of Anti-HER2 treatments combined with atezolizumab on the tumor immune microenvironment in early or metastatic breast cancer: results from a phase Ib study. *Clin Breast Cancer.* 2021;21:539–551.
48. FDA approves pembrolizumab for high-risk early-stage triple-negative breast cancer. 2021; <https://www.fda.gov/drugs/resources-information-approved-drugs/fda-approves-pembrolizumab-high-risk-early-stage-triple-negative-breast-cancer>.
49. Dill EA, Gru AA, Atkins KA, et al. PD-L1 expression and intratumoral heterogeneity across breast cancer subtypes and stages: an assessment of 245 primary and 40 metastatic tumors. *Am J Surg Pathol.* 2017;41:334–342.
50. Sun X, Zuo K, Yao Q, et al. Invasive apocrine carcinoma of the breast: clinicopathologic features and comprehensive genomic profiling of 18 pure triple-negative apocrine carcinomas. *Mod Pathol.* 2020;33:2473–2482.
51. Boissiere-Michot F, Jacot W, Massol O, Mollevi C, Lazennec G. CXCR2 levels correlate with immune infiltration and a better prognosis of triple-negative breast cancers. *Cancers (Basel).* 2021;13:2328.
52. Dusenbery AC, Maniaci JL, Hillerson ND, Dill EA, Bullock TN, Mills AM. MHC class I loss in triple-negative breast cancer: a potential barrier to PD-1/PD-L1 checkpoint inhibitors. *Am J Surg Pathol.* 2021;45:701–707.
53. Stanton SE, Adams S, Disis ML. Variation in the incidence and magnitude of tumor-infiltrating lymphocytes in breast cancer subtypes: a systematic review. *JAMA Oncol.* 2016;2:1354–1360.
54. Chowell D, Morris LGT, Grigg CM, et al. Patient HLA class I genotype influences cancer response to checkpoint blockade immunotherapy. *Science.* 2018;359:582–587.
55. Vranic S, Gatalica Z. The role of pathology in the era of personalized (precision) medicine: a brief review. *Acta Med Acad.* 2021;50:47–57.
56. Costa JL, Justino A, Gomes M, et al. Abstract 2013: Comprehensive genetic characterization of apocrine lesions of the breast. *Cancer Res.* 2013;73(8 Supplement):2013.
57. Vranic S, Marchio C, Castellano I, et al. Immunohistochemical and molecular profiling of histologically defined apocrine carcinomas of the breast. *Hum Pathol.* 2015;46:1350–1359.

58. Weisman PS, Ng CK, Brogi E, et al. Genetic alterations of triple negative breast cancer by targeted next-generation sequencing and correlation with tumor morphology. *Mod Pathol*. 2016;29:476–488.
59. Asghar US, Barr AR, Cutts R, et al. Single-cell dynamics determines response to CDK4/6 inhibition in triple-negative breast cancer. *Clin Cancer Res*. 2017;23:5561–5572.
60. Dieci MV, Tsvetkova V, Griguolo G, et al. Androgen receptor expression and association with distant disease-free survival in triple negative breast cancer: analysis of 263 patients treated with standard therapy for stage I-III disease. *Front Oncol*. 2019;9:452.
61. Tzikas AK, Nemes S, Linderholm BK. A comparison between young and old patients with triple-negative breast cancer: biology, survival and metastatic patterns. *Breast Cancer Res Treat*. 2020;182:643–654.
62. Skenderi F AM, Alahamd YM, Abdelhafez IHE, Gatalica Z, Vranic S. HER2-positive apocrine carcinoma of the breast: a population-based analysis of incidence, treatment, and outcome. *Virchows Arch*. 2020;477:S55.
63. Zhao D, Fu X, Rohr J, et al. Poor histologic tumor response after adjuvant therapy in basal-like HER2-positive breast carcinoma. *Pathol Res Pract*. 2021;228.
64. Lehmann BD, Jovanovic B, Chen X, et al. Refinement of triple-negative breast cancer molecular subtypes: implications for neoadjuvant chemotherapy selection. *PLoS One*. 2016;11.
65. Imamovic D, Bilalovic N, Skenderi F, et al. A clinicopathologic study of invasive apocrine carcinoma of the breast: a single-center experience. *Breast J*. 2018;24:1105–1108.
66. Santonja A, Sanchez-Munoz A, Lluch A, et al. Triple negative breast cancer subtypes and pathologic complete response rate to neoadjuvant chemotherapy. *Oncotarget*. 2018;9:26406–26416.
67. Echavarría I, Lopez-Tarruella S, Picornell A, et al. Pathological response in a triple-negative breast cancer cohort treated with neoadjuvant carboplatin and docetaxel according to Lehmann's refined classification. *Clin Cancer Res*. 2018;24:1845–1852.
68. Trapani D, Giugliano F, Uliano J, et al. Benefit of adjuvant chemotherapy in patients with special histology subtypes of triple-negative breast cancer: a systematic review. *Breast Cancer Res Treat*. 2021;187:323–337.
69. Zhu M, Yu Y, Shao X, Zhu L, Wang L. Predictors of response and survival outcomes of triple negative breast cancer receiving neoadjuvant chemotherapy. *Chemotherapy*. 2020;65:101–109.
70. Mohammed AA, Elsayed FM, Algazar M, Rashed HE, Anter AH. Neoadjuvant chemotherapy in triple negative breast cancer: correlation between androgen receptor expression and pathological response. *Asian Pac J Cancer Prev*. 2020;21:563–568.
71. Liu X, Feng C, Liu J, et al. The importance of EGFR as a biomarker in molecular apocrine breast cancer. *Hum Pathol*. 2018;77:1–10.
72. Liu X, Feng C, Liu J, et al. Androgen receptor and heat shock protein 27 co-regulate the malignant potential of molecular apocrine breast cancer. *J Exp Clin Cancer Res*. 2018;37:90.
73. Choi SK, Kam H, Kim KY, Park SI, Lee YS. Targeting heat shock protein 27 in cancer: a druggable target for cancer treatment? *Cancers (Basel)*. 2019;11:1195.
74. Di Leone A, Fragomeni SM, Scardina L, et al. Androgen receptor expression and outcome of neoadjuvant chemotherapy in triple-negative breast cancer. *Eur Rev Med Pharmacol Sci*. 2021;25:1910–1915.
75. Kumar S, Bal A, Das A, et al. Molecular subtyping of triple negative breast cancer by surrogate immunohistochemistry markers. *Appl Immunohistochem Mol Morphol*. 2021;29:251–257.
76. Saridakis A, Berger ER, Harigopal M, et al. Apocrine breast cancer: unique features of a predominantly triple-negative breast cancer. *Ann Surg Oncol*. 2021;28:5610–5616.
77. Honma N, Ogata H, Yamada A, et al. Clinicopathological characteristics and prognostic marker of triple-negative breast cancer in older women. *Hum Pathol*. 2021;111:10–20.
78. Sanges F, Floris M, Cossu-Rocca P, et al. Histologic subtyping affecting outcome of triple negative breast cancer: a large Sardinian population-based analysis. *BMC Cancer*. 2020;20:491.
79. Kim J, Kim JY, Lee HB, et al. Characteristics and prognosis of 17 special histologic subtypes of invasive breast cancers according to World Health Organization classification: comparative analysis to invasive carcinoma of no special type. *Breast Cancer Res Treat*. 2020;184:527–542.
80. Han Y, Wang J, Xu B. Clinicopathological characteristics and prognosis of breast cancer with special histological types: a surveillance, epidemiology, and end results database analysis. *Breast*. 2020;54:114–120.
81. Ilhan B, Emiroglu S, Turkyay R, Ilhan R. The role of histopathologic testing on apocrine carcinoma of the breast. *Curr Probl Cancer*. 2020;44.
82. Kubouchi K, Shimada K, Yokoe T, Tsutsumi Y. Avoidance and period-shortening of neoadjuvant chemotherapy against triple-negative breast cancer in stages I and II: importance of Ki-67 labeling index and the recognition of apocrine-type lesions. *Technol Cancer Res Treat*. 2020;19.
83. Wysocka J, Adamczyk A, Kruczak A, Niemiec J, Sas-Korczyńska B. High Ki-67 expression is a marker of poor survival in apocrine breast carcinoma. *Pol J Pathol*. 2020;71:107–119.
84. Zhao S, Ma D, Xiao Y, Jiang YZ, Shao ZM. Clinicopathologic features and prognoses of different histologic types of triple-negative breast cancer: A large population-based analysis. *Eur J Surg Oncol*. 2018;44:420–428.
85. Arciero CA, Diehl 3rd AH, Liu Y, et al. Triple-negative apocrine carcinoma: A rare pathologic subtype with a better prognosis than other triple-negative breast cancers. *J Surg Oncol*. 2020;122:1232–1239.
86. Montagna E, Cancellò G, Pagan E, et al. Prognosis of selected triple negative apocrine breast cancer patients who did not receive adjuvant chemotherapy. *Breast*. 2020;53:138–142.
87. Wu W, Wu M, Peng G, Shi D, Zhang J. Prognosis in triple-negative apocrine carcinomas of the breast: a population-based study. *Cancer Med*. 2019;8:7523–7531.
88. Meattini I, Pezzulla D, Saieva C, et al. Triple negative apocrine carcinomas as a distinct subtype of triple negative breast cancer: a case-control study. *Clin Breast Cancer*. 2018;18:e773–e780.
89. Astvatsaturyan K, Yue Y, Walts AE, Bose S. Androgen receptor positive triple negative breast cancer: clinicopathologic, prognostic, and predictive features. *PLoS One*. 2018;13.
90. Liao HY, Zhang WW, Sun JY, Li FY, He ZY, Wu SG. The clinicopathological features and survival outcomes of different histological subtypes in triple-negative breast cancer. *J Cancer*. 2018;9:296–303.
91. Mills MN, Yang GQ, Oliver DE, et al. Histologic heterogeneity of triple negative breast cancer: a national cancer centre database analysis. *Eur J Cancer*. 2018;98:48–58.